



## Discover Generics

Cost-Effective CT & MRI Contrast Agents



FRESENIUS  
KABI

[VIEW CATALOG](#)

# AJNR

## **Clostridium septicum meningoencephalitis: an unusual presentation of occult rectal carcinoma.**

R L Ragland, J R Knorr, G M Lee, U DeGirolami and N D Gelber

*AJNR Am J Neuroradiol* 1992, 13 (5) 1487-1488

<http://www.ajnr.org/content/13/5/1487.citation>

This information is current as  
of September 2, 2025.

# ***Clostridium septicum* Meningoencephalitis: An Unusual Presentation of Occult Rectal Carcinoma**

Ronald L. Ragland,<sup>1,4</sup> John R. Knorr,<sup>1</sup> Grace M. Lee,<sup>2</sup> Umberto DeGirolami,<sup>3</sup> and Nicholas D. Gelber<sup>1</sup>

**Summary:** Colonic and hematologic malignancies can predispose to clostridial abscess in the CNS, as demonstrated in this 67-year-old man who died from clostridial meningoencephalitis secondary to rectal adenocarcinoma.

**Index terms:** Brain, infection; Meningitis; Encephalitis

Pneumocephalus in the nontraumatic setting is distinctly unusual. Without prior trauma, infection by a gas-forming organism must be considered. Most often, such infection results in localized abscess formation and a loculated form of pneumocephalus. Herein, we report a case of diffuse meningoencephalitis as the only manifestation of an occult transmural rectal carcinoma.

## **Case Report**

A 67-year-old man with no significant prior medical history was brought to our Emergency Room (ER) obtunded. His wife related a history of a rapidly progressive 18-hour deterioration starting with nausea and vomiting and followed by fever and chills, diarrhea, confusion, and ultimately unresponsiveness. In the ER, he was hemodynamically unstable. An emergent noncontrast CT examination of the brain was performed. Multicompartmental pneumocephalus was noted (Figs. 1A and 1B). The patient remained unresponsive and there was a lack of brain stem reflex function. The patient died within hours of presentation. Subsequently, blood and cerebrospinal fluid cultures were positive for *Clostridium septicum* growth. Autopsy revealed clostridial meningoencephalitis. There was acute inflammatory change involving the subependymal region, leptomeninges, and subarachnoid space blood vessels. In these regions, cystic spaces consistent with invasion by gas-forming organisms were present; Gram's stain showed gram-positive rods. There was no evidence of infection of other organ systems. A necrotic rectal adenocarcinoma, Duke's grade B1 was discovered.

## **Discussion**

Though nontraumatic CNS clostridial infection is unusual, it is well recognized that colonic and hematologic malignancies predispose to clostridial abscesses in the brain (1–8). In this case, it appears plausible that the infection of the CNS occurred after the patient developed sepsis. Most often, such brain involvement is characterized by localized abscess formation and the demonstration of diffuse meningoencephalitis by imaging is said to be rare (2). Clearly, the development of clostridial brain infection is ominous, with mortality rates reported in the range of 50% to 100%, with somewhat improved survival with early recognition and intravenous antibiotics (3, 5). Our case is typical of the rapid downward spiral of clinical deterioration that marks clostridial CNS infection.

*C. septicum* is an anaerobic, gram-positive bacillus that forms spores (8). Clostridial species are a common soil saprophyte and, as such, soil-contaminated penetrating wounds are subject to infection. However, hematologic malignancy and colonic adenocarcinomas (especially in the cecum) also predispose to infection (1, 3). Necrotic tumor tissue abets clostridial spore germination leading to septicemia and, in the absence of a contaminated penetrating wound, *C. septicum* septicemia should raise the suspicion of underlying malignancy (1, 9, 10).

In summary, this case illustrates a distinctly unusual manifestation of the well-recognized pathogenetic factors involving *C. septicum* septicemia and resultant meningoencephalitis: a rare presentation of occult rectosigmoid adenocarcinoma.

Received August 20, 1991; accepted contingent on revision September 26; revision received November 22 and accepted December 10.

<sup>1</sup> Department of Radiology, University of Massachusetts Medical Center, Worcester, MA.

<sup>2</sup> Department of Radiology, Johns Hopkins Hospital, Baltimore, MD.

<sup>3</sup> Department of Pathology, Brigham and Women's Hospital, Boston, MA.

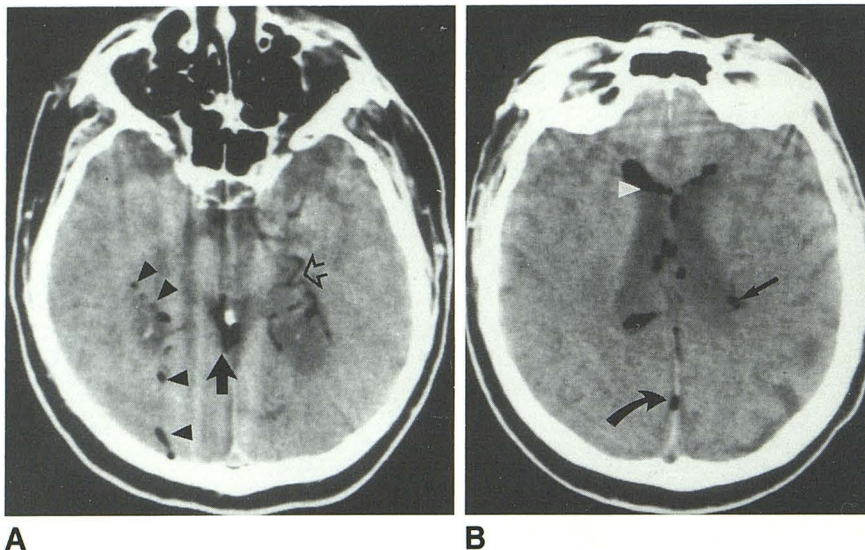
<sup>4</sup> Address reprint requests to Ronald L. Ragland, MD, Department of Radiology, University of Massachusetts Medical Center, 55 Lake Avenue, North, Worcester, MA 01655.



Fig. 1. Noncontrast CT examination of the brain.

A, There is a serpiginous area of gas collection within the left medial temporal lobe (*open arrow*). This has the appearance of intravascular gas. There is intraparenchymal gas (*arrowheads*), as well as intracisternal gas (*solid arrow*).

B, At the level of the ventricular bodies, there is increased cerebrospinal fluid density noted. Again, there is intraparenchymal gas (*small arrow*), gas within the interhemispheric fissure (*curved arrow*), as well as intraventricular gas with a gas-fluid level noted anteriorly (*white arrowhead*).



## References

1. Roeltgen D, Shugar G, Towfighi J. Cerebritis due to *Clostridium septicum*. *Neurology* 1980;30:1314-1316
2. Klein MA, Kelly JK, Jacobs IG. Diffuse pneumocephalus from *Clostridium perfringens* meningitis: CT findings. *AJNR* 1989;10:447
3. Alpern RJ, Dowell JR VR. *Clostridium septicum* infections and malignancy. *JAMA* 1969;209:385-388
4. Schaaf RE, Jacobs N, Kelvin FM, Gallis HA, Akwari O, Thompson WM. *Clostridium septicum* infection associated with colonic carcinoma and hematologic abnormality. *Radiology* 1980;137:625-627
5. Katlic MR, Derkac WM, Coleman WS. *Clostridium septicum* infection and malignancy. *Ann Surg* 1981;193:361-364
6. Koransky JR, Stargel MD, Dowell JR VR. *Clostridium septicum* bacteremia: its clinical significance. *Am J Med* 1979;66:63-66
7. Gorse GJ, Slater LM, Sobol E, Kim RC, Wishnow RM, Cesario TC. CNS infection and bacteremia due to *Clostridium septicum*. *Arch Neurol* 1984;41:882-884
8. Jawetz E, Melnick JL, Adelberg EA, eds. Anaerobic spore forming bacilli: the Clostridia. In: *Review of Medical Microbiology*. 13th ed. Los Altos, CA: Lange, 1978:192-197
9. Malmgren RA, Flanigan CC. Localization of the vegetative form of *Clostridium tetani* in mouse tumors following intravenous spore administration. *Cancer Res* 1955;15:473-478
10. Propst A, Mose JR. Die wirkung apathogener Clostridien auf bosartigen tumoren. *Z Krebsforsch* 1966;68:337-351