



Get Clarity On Generics

Cost-Effective CT & MRI Contrast Agents

**FRESENIUS
KABI**

WATCH VIDEO

AJNR

MR imaging in patients with primary thyroid lymphoma.

T Ohnishi, S Noguchi, N Murakami, S Jinnouchi, H Hoshi, S Futami and K Watanabe

AJNR Am J Neuroradiol 1992, 13 (4) 1196-1198

<http://www.ajnr.org/content/13/4/1196>

This information is current as
of August 14, 2025.

MR Imaging in Patients with Primary Thyroid Lymphoma

Takashi Ohnishi,^{1,3} Shiro Noguchi,¹ Nobuo Murakami,¹ Seishi Jinnouchi,² Hiroaki Hoshi,² Shigemi Futami,² and Katsushi Watanabe²

Summary: The authors describe two patients with thyroid lymphoma and Hashimoto thyroiditis; T1- and T2-weighted MR sequences were used. In one patient, the region of lymphoma showed a different signal intensity on T2 images; in the other patient, the signal level was identical to the Hashimoto disease. In sum, the processes could not be significantly differentiated using MR.

Index terms: Lymphoma; Thyroid gland, Magnetic resonance; Thyroid gland, neoplasms

Malignant lymphoma presenting as a primary neoplasm in the thyroid, although uncommon, still accounts for 4% of all thyroid malignancies (1). Primary thyroid lymphoma may be clinically suspected if there is associated Hashimoto thyroiditis, in which case ultrasonography and biopsy can be performed to confirm the diagnosis (2). Recently, several magnetic resonance (MR) imaging studies of thyroid malignancies have been reported (3–6, 8). But of these, only three studies report MR imaging of primary thyroid lymphoma (3, 4, 8). We performed MR imaging in two patients with primary thyroid lymphoma. The findings in one of these patients are different from previous reports. We present the findings of MR images obtained from patients with primary thyroid lymphoma having associated Hashimoto thyroiditis.

Case Reports

Case 1

A 62-year-old woman with a 2-month history of anterior neck swelling was admitted to our hospital. Physical examination revealed an elastic, hard mass measuring 3.5 × 3 cm in the right thyroid gland. Thyroid function test

results confirmed hypothyroidism and the antimicrosomal antibody level (MCHA) was positive. Ultrasonography depicted a hypoechoic tumor in the right lobe of the thyroid gland. MR imaging was performed with a 0.5 T superconductive MR system using a surface coil for the neck. T1-weighted axial images with spin-echo pulse sequences 500/20/4 (TR/TE/excitations) and cardiac gated T2-weighted images with long TR and TE spin-echo pulse sequence 2256/80/2 were obtained. Section thickness was 6 mm with an intersection gap of 1 mm. Matrix size was 256 × 256. On T1-weighted images, the signal intensity of the tumor in the right lobe was isointense relative to that of the left lobe (Fig. 1A). In the T2-weighted images, the signal intensity of the tumor was demonstrated as homogeneous with slightly high-intensity areas relative to the left (Fig. 1B). Malignant lymphoma (non-Hodgkin lymphoma, follicular medium type) in the right lobe and Hashimoto thyroiditis in the left lobe were confirmed by open biopsy.

Case 2

A 59-year-old woman presented with swelling of the neck and was admitted to our hospital. Physical examination and thyroid function test suggested Hashimoto thyroiditis. Ultrasonography demonstrated a hypoechoic tumor in the left lobe of the thyroid. The signal intensity of the left lobe was identical to that of the right lobe on both T1(500/15/4) and T2-weighted images (2176/80/2) (Figs. 2A and 2B). Malignant lymphoma (non-Hodgkin lymphoma, follicular medium type) in the left lobe and Hashimoto thyroiditis in the right lobe were confirmed by open biopsy.

Discussion

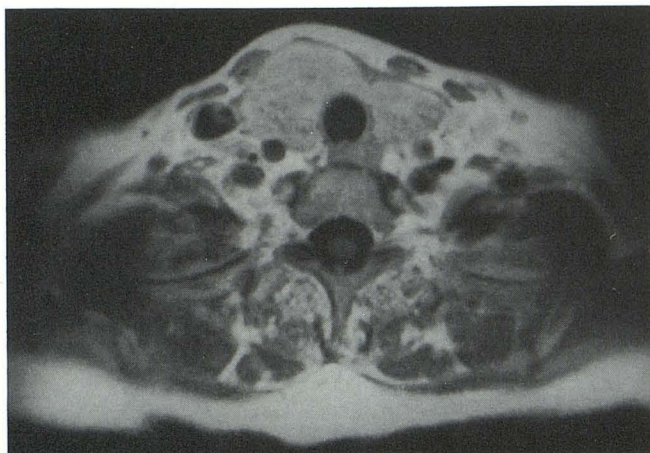
The signal intensity of MR studies in patients with primary thyroid lymphoma has only been described three times to date (3, 4, 8). Higgins et

Received July 25 1991; accepted and revision requested November 20; revision received December 4.

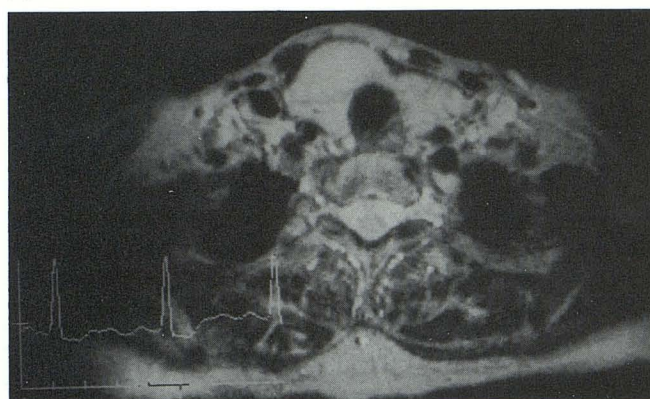
¹ Noguchi Thyroid Clinic and Hospital Foundation, Beppu, Oita, Japan.

² Department of Radiology, Miyazaki Medical College, Miyazaki, Japan.

³ Address reprint requests to Takashi Ohnishi, Noguchi Thyroid Clinic and Hospital Foundation, 6-33 Noguchi Nakamachi, Beppu, Oita, Japan 874.



A

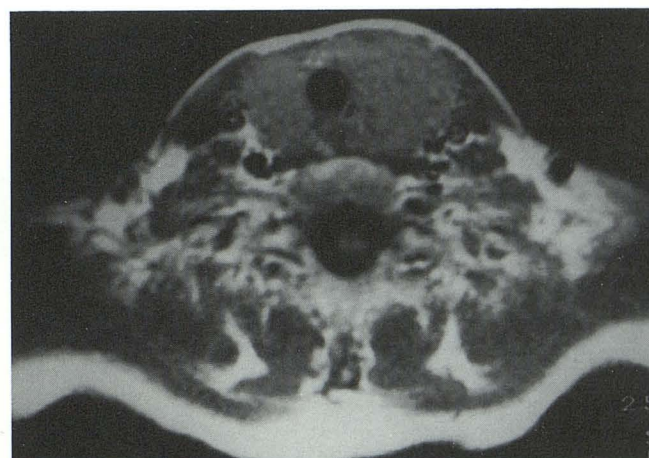

B

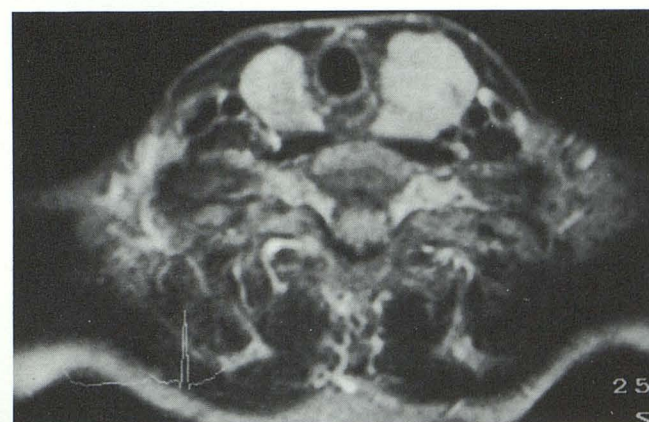
Fig. 1. Tumor of the right lobe shows homogeneous isointensity on T1-weighted image (A) and high intensity to left lobe on T2-weighted image (B).

al (3) reported the signals to be of low to medium intensity in T1-weighted images and of heterogeneous high intensity in T2-weighted images. Takashima et al (4), however, were able to clearly distinguish thyroid lymphoma from Hashimoto thyroiditis as a homogeneous area of high intensity in T2-weighted images. They also noted that the signal intensities of thyroid lymphoma were similar to those of thyroid carcinoma or adenoma in the previous reports (3, 5, 6). To the best of our knowledge, the largest study of MR imaging in primary thyroid lymphoma was reported by Shibata et al (8). They reported that five of six lymphomas showed homogeneous high intensity on T-2 weighted images (8). At our clinic we obtained MR images in two patients. In case 1, the findings were in keeping with those of the above mentioned reports; however, in our second case, the results were contrary to previous re-

ports. MR imaging could not distinguish thyroid lymphoma from Hashimoto thyroiditis in either T1- or T2-weighted images. Shibata et al (8) reported that they could not differentiate Hashimoto thyroiditis from lymphoma. However, they were describing a single case in which diffuse lymphomatous involvement throughout the entire gland could not be differentiated from the underlying Hashimoto thyroiditis (8). Unlike their study, our second case was identified as a solitary localized mass on ultrasonography and pathologic findings. Early diagnosis improves the prognosis in patients with thyroid lymphoma (7); however, thyroid lymphoma must first be distinguished from Hashimoto thyroiditis. To date, T2-weighted MR images seem to hold great potential to differentiate the two, but an infallible method of defining thyroid lymphoma has yet to be established.



A



B

Fig. 2. The signal intensity of tumor in the left lobe is identical to that of right lobe on both T1-weighted (A) and T2-weighted (B) images.

References

1. Souhami L, Simpson WJ, Carruthers JS. Malignant lymphoma of the thyroid gland. *Int J Radiat Oncol Bio Phys* 1980;6:1143-1147
2. Hamburger JI, Miller JM, Kini SR, et al. Lymphoma of the thyroid. *Ann Intern Med* 1983;99:685-693
3. Higgins CB, Auffermann W. MR imaging of thyroid and parathyroid glands: a review of current status. *AJR* 1988;151:1095-1106
4. Takashima S, Ikezoe J, Morimoto S, et al. MR imaging of primary thyroid lymphoma. *J Comput Assist Tomogr* 1989;13:517-518
5. Gefter WB, Spritzer CE, Eisenberg B, et al. Thyroid imaging with high-field-strength surface-coil MR. *Radiology* 1987;164:483-490
6. Noma C, Nishimura K, Togashi K, et al. Thyroid gland: MR imaging. *Radiology* 1987;164:495-499
7. Devine RM, Edis AJ, Banks PM, et al. Primary lymphoma of the thyroid: a review of the Mayo Clinic experience through 1987. *World J Surg* 1981;5:33-38
8. Shibata T, Noma S, Nakano Y, et al. Primary thyroid lymphoma: MR appearance. *J Comput Assist Tomogr* 1991;15:629-633