



Get Clarity On Generics

Cost-Effective CT & MRI Contrast Agents

**FRESENIUS
KABI**

[WATCH VIDEO](#)

AJNR

Embolization of spinal dural arteriovenous fistula with polyvinyl alcohol particles: experience in 14 patients.

D A Nichols, D A Rufenacht, C R Jack, Jr and G S Forbes

AJNR Am J Neuroradiol 1992, 13 (3) 933-940

<http://www.ajnr.org/content/13/3/933>

This information is current as
of August 11, 2025.

Embolization of Spinal Dural Arteriovenous Fistula with Polyvinyl Alcohol Particles: Experience in 14 Patients

Douglas A. Nichols,¹ Daniel A. Rufenacht,¹ Clifford R. Jack, Jr.,¹ and Glenn S. Forbes¹

Purpose: To assess the effectiveness, initial and long term, of embolization using polyvinyl alcohol particles (PVA) particles in patients with spinal dural arteriovenous fistulas (SDAVF). **Methods:** The initial treatment in 14 patients with SDAVF was embolization with PVA particles. Postembolization occlusion of the SDAVF was documented angiographically in all cases. **Results:** All 14 patients initially showed an improvement in clinical symptoms, but the neurologic status of 11 patients subsequently deteriorated. Of the 11 patients who had recurrence of symptoms, nine had angiographically proven recurrences of their SDAVF while two had negative follow-up of spinal angiography. PVA embolization is ineffective for the treatment of SDAVF and is not without risk. **Conclusion:** On the basis of a literature review of the other two alternative treatments (operation or liquid adhesive embolization) available for SDAVF and our preliminary experience with *N*-butyl cyanoacrylate (NBCA) embolization, we suggest that NBCA embolization be the initial treatment of choice for SDAVF; if that procedure is not possible, or is unsuccessful, then operation is recommended.

Index terms: Arteriovenous malformations, spinal; Fistula, arteriovenous; Interventional neuroradiology; Interventional materials, polyvinyl alcohol particles

AJNR 13:933-940, May/June 1992

Vascular malformations of the spinal canal that derive their arterial supply from dural arteries and that drain into medullary veins were recognized as a distinct pathologic entity in 1977 by Kendall and Logue (1) and were described as being epidural in location. Angiotomographic evaluation revealed a close topographic relationship of the vascular malformation to the nerve root sheath. A single draining vein was formed at the level of the dura and became slightly dilated along its intrathecal course (2). This description led to the term "radiculomeningeal arteriovenous fistula," which later has been referred to as "spinal dural arteriovenous fistula (SDAVF) draining into medullary veins" (3). Histologic evaluation of SDAVF demonstrates that the "nidus" is a network of collaterals of dural arteries; this network represents the extradural arterial pedicle that feeds the fistula. The arteriovenous (AV) shunt is transdural

in location and the draining vein is intradural in location (4).

The generally accepted pathophysiologic basis for the neurologic deficits associated with SDAVF, as proposed by Aminoff et al (5) in 1974, is that an increase in spinal cord venous pressure secondary to the AV shunt results in reduced intramedullary blood flow, which leads to an ischemic myelopathy.

Merland et al (2) injected the anterior spinal artery (of Adamkiewicz) in patients with SDAVF and interpreted the lack of normal venous drainage as a direct sign of congestion of the circulation. Angiography showed that the medullary venous system was filled by the SDAVF but lacked outflow from radicular veins. Intraoperative measurement of the intravascular pressure of intrathecal perimedullary draining veins has demonstrated mean pressures of 60% to 87.5% of mean systemic arterial blood pressure (6). The coexistent problems are thus congestion of the circulation and poor drainage of the spinal cord by radicular veins.

Most authorities agree that the basis of any therapy for SDAVF should be elimination of the AV shunt within the dura or disconnection of the

Received April 19, 1991; accepted and revision requested June 28; revision received August 21.

¹ Department of Diagnostic Radiology, Mayo Clinic and Mayo Foundation, Rochester, MN 55905. Address reprint requests to D. A. Nichols.

AJNR 13:933-940, May/June 1992 0195-6108/92/1303-0933

© American Society of Neuroradiology

TABLE 1: Clinical and angiographic findings in 14 patients with SDAVF who underwent embolization with PVA particles

Case	Age (yr)/ Sex	Duration of Clinical Symptoms before Diagnosis (mo)	Primary Arterial Supply to SDAVF	Clinical Course after Embolization	Findings on Follow-up Angiography
1	60/M	12	Left T4	1) initial improvement for 6 mo, then relapse 2) Triparesis secondary to embolization	Recurrence at left T4 6 mo after first embolization Recurrence at left T4 22 mo after second embolization
2	71/F	18	Right T9	Initial improvement for 25 mo, then relapse	Negative, 28 mo after em- bolization
3	58/M	36	Right T10	Initial improvement for 7 mo, then relapse	Recurrence at right T10 16 mo after embolization
4	51/M	6	Left T11	1) Initial improvement for 2 mo, then relapse 2) No improvement	Recurrence at left T12 5 mo after first embolization Recurrence at left T12 1 mo after second embolization
5	70/M	36	Right L3	Mild initial improvement, then stable course un- til last follow-up 36 mo after embolization	NA
6	54/F	24	Right L1	Mild initial improvement for 5 mo, then relapse	Recurrence at right T7 5 mo after embolization
7	69/M	4	Right T7	Initial improvement for 8 mo, then relapse	Recurrence at right T7 41 mo after embolization
8	64/F	48	Right T5 and T6	Improvement and stable	NA
9	74/F	36	Left superior lat- eral sacral	Temporary worsening of LLE paresis, then im- provement and stable	Negative, 5 mo after embo- lization
10	57/M	3	Left T10	1) Initial improvement for 7 mo, then relapse 2) Initial improvement for 6 mo, then relapse	Recurrence at left T10 8 mo after first embolization Recurrence at left T10 9 mo after second embolization
11	54/M	4	Right T8	Initial improvement for 4 mo, then relapse	Recurrence at right T8 4 mo after embolization
12	70/M	24	Right T8	1) Mild initial improve- ment for 7 mo, then relapse 2) No improvement	1) Recurrence at right T8 11 mo after 1st embolization 2) NA
13	60/F	36	Left T8	Initial improvement for 1 mo, then relapse	Recurrence at left T8 2 mo after embolization
14	65/M	12	Right T6	Initial improvement for 8 mo, then relapse	Negative follow-up angiog- raphy 7 and 21 mo after embolization

Note.—LLE, left lower extremity; NA, not applicable.

arterialized draining vein from the coronal venous plexus of the spinal cord to thereby improve the AV pressure gradient within the spinal cord.

The preferred management of SDAVF remains controversial. Early investigators (7, 8) advocated

embolization with particulate materials as the initial treatment, and many medical centers still use this approach despite recent reports (9, 10) documenting recurrences of SDAVF after this therapy. Others have advocated embolization

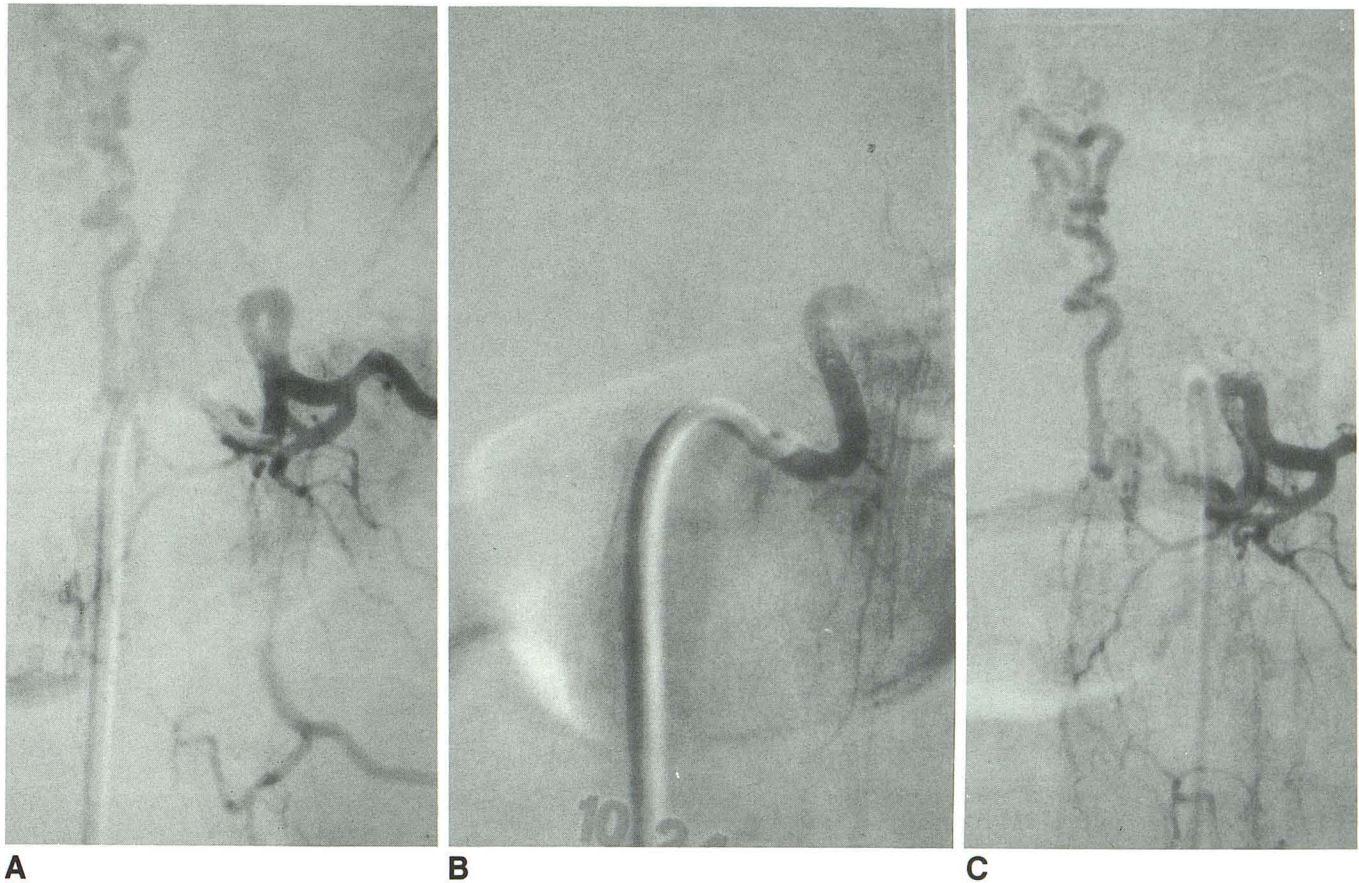


Fig. 1. Recurrence of SDAVF after embolization with PVA particles.

A, Spinal angiogram obtained before embolization demonstrates SDAVF arising from left T10 intercostal artery.

B, Spinal angiogram obtained immediately after embolization of left T-10 intercostal artery demonstrates occlusion of SDAVF.

C, Follow-up angiogram obtained 8 months after the first particulate embolization procedure shows recurrence of left T-10 SDAVF.

with liquid adhesives (2, 3, 11–13) or operation to eliminate the AV shunt (9, 10, 14, 15).

We report our experience with 14 patients who had SDAVF and were initially treated by embolization with particulate materials. We also discuss the reasons for the disappointing results of this treatment and the rationale for our proposal that embolization with *N*-butyl cyanoacrylate (NBCA) be the initial therapy for most patients with SDAVF. If NBCA embolization is not possible or is unsuccessful, surgical removal is an alternative therapy.

Materials and Methods

We retrospectively reviewed the histories and radiographic findings of 16 consecutive patients seen at our institution between 1982 and 1986 who underwent embolization with polyvinyl alcohol (PVA) particles as the initial form of therapy for SDAVF. Two patients were lost to long-term follow-up; therefore, the series consists of the remaining 14 patients for whom follow-up information was available.

Table 1 summarizes the pertinent clinical and angiographic findings in the 14 patients. The average age of the 14 patients (9 men and 5 women) was 63 years (range, 51–74 years). All patients presented with a history of progressive paraparesis, and upper and lower motor neuron abnormalities were found on physical examination. The average duration of clinical symptoms was 21 months (range, 3–48 months).

The radiographic diagnosis of SDAVF was made from myelography (done with patients in the prone and supine positions) and selective spinal angiography in all patients. The SDAVF was located in the middle of the thoracic region (T4–T7) in four patients, low thoracic region (T8–T12) in seven, lumbar region in two, and sacral region in one.

The diameter of the AV shunts was approximately 0.5–1.5 mm, measured angiographically at the origin of the draining vein, and they were supplied by a network of collaterals of dural arteries. The AV shunts were single with a solitary draining vein joining the medullary venous plexus through a moderately enlarged radicular vein (4). All patients had angiographic evidence of spinal cord venous hypertension and abnormal drainage of the medullary venous system.

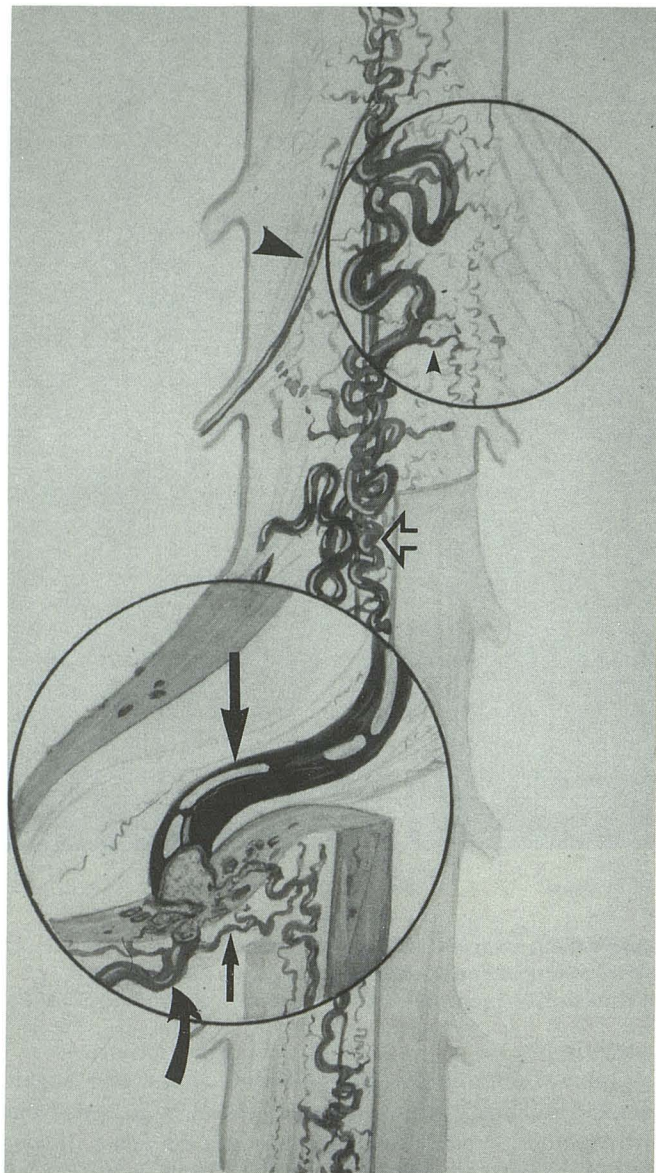
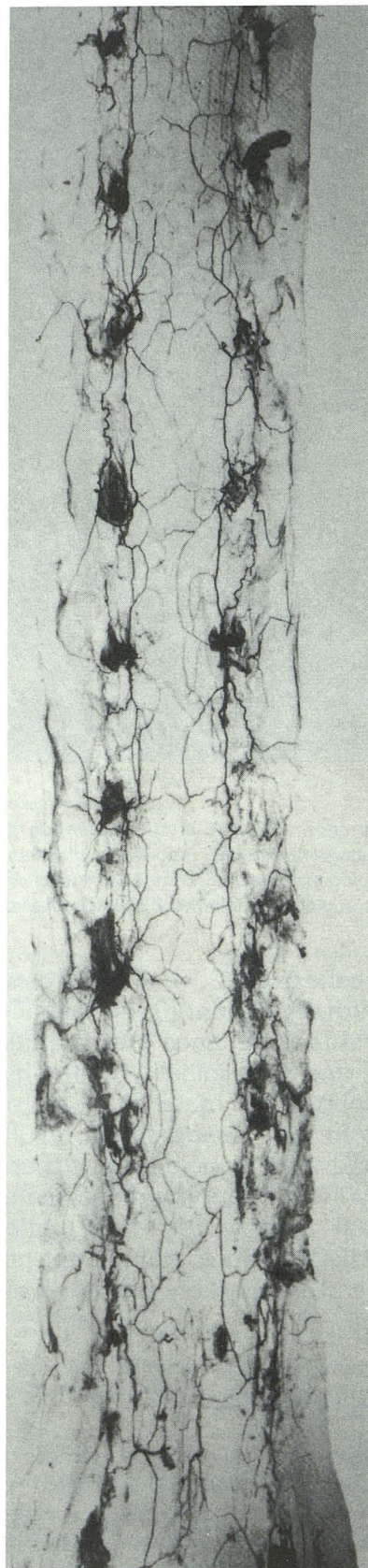


Fig. 2. SDAVF. Arterial supply is from dural branch (*curved arrow, bottom inset*) of spinal ramus of the intercostal or lumbar artery. Potential dural collaterals (*small arrow, bottom inset*) will allow for reconstitution of SDAVF if occlusion with PVA particles is proximal to AV shunt. Drainage is through a radicular vein (*large arrow, bottom inset*) to coronal venous plexus on the cord surface (*open arrow*). Small branches of coronal venous plexus (*small arrowhead, top inset*) may be occluded if particulate material passes through fistula. Note lack of normal venous drainage through radicular veins and normal size of anterior spinal artery (*large arrowhead*). (Illustrated by D.A. Rufenacht, MD)

All embolization procedures were performed through a transfemoral approach. Catheters of various shapes and sizes were used for selective catheterization of the intercostal, lumbar, or sacral arteries that gave origin to the dural arteries supplying the SDAVF. Because the patients were treated before steerable microcatheters were readily available, superselective catheterization of the dural arteries was not performed. Embolization with PVA particles (100–500



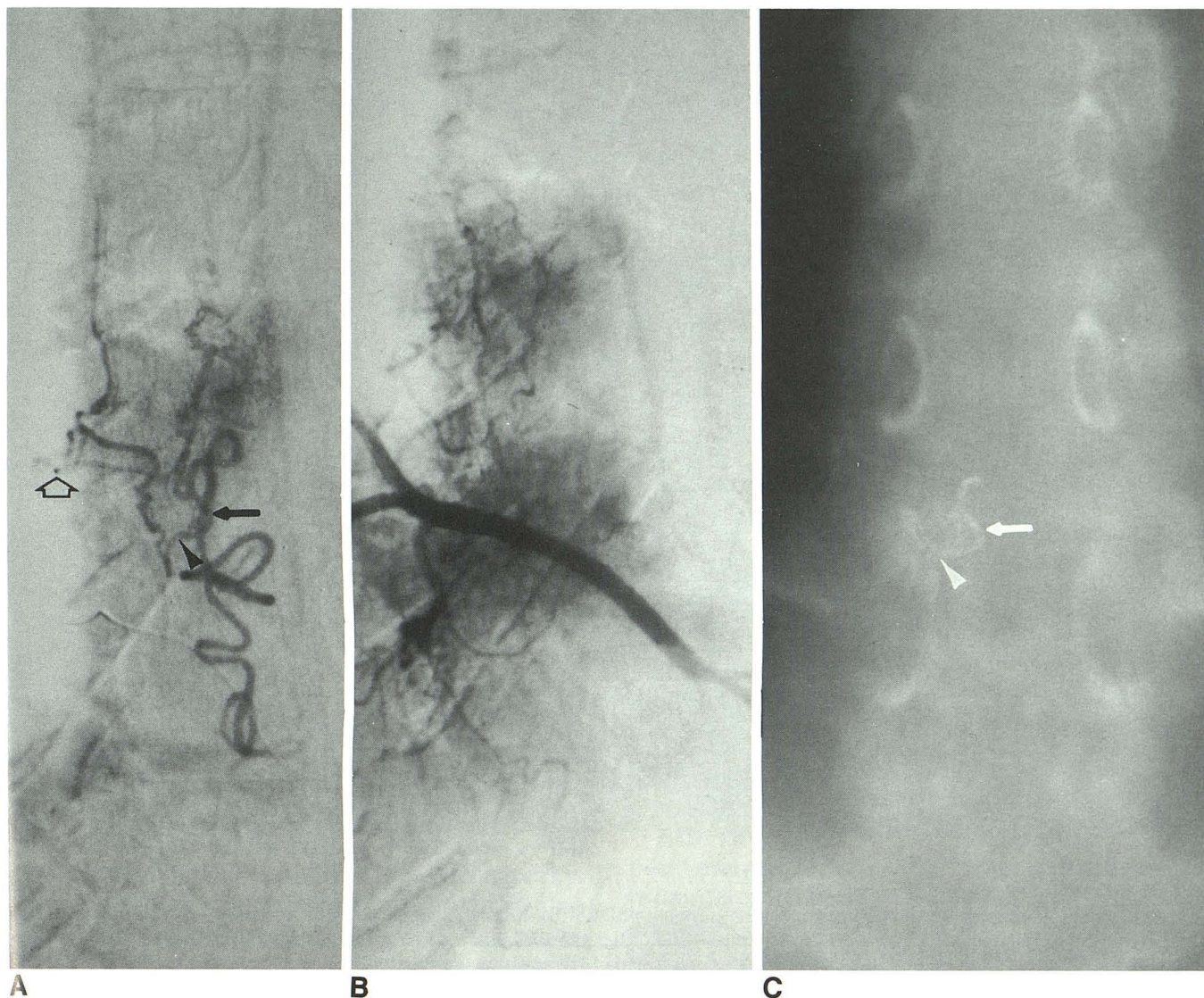


Fig. 4. SDAVF arising from right T9 intercostal artery.

A, Selective injection of dural branch supplying SDAVF before embolization. *Open arrow* points to the microcatheter, *arrowhead* demonstrates the fistula site, and *arrow* demonstrates the proximal draining vein.

B, Control angiogram obtained after embolization with NBCA demonstrates no opacification of the draining vein.

C, Tomogram obtained after NBCA embolization demonstrates optimal deposition of NBCA at site of fistula (*arrowhead*) and proximal draining vein (*arrow*).

μm in diameter) in a suspension of normal saline and contrast material was performed with flow-directed technique done under fluoroscopic guidance. PVA particles were obtained from commercial vendors or were prepared in our laboratory; their sizes ranged from approximately 100–300 μm and from 300–500 μm . In three procedures, microfibrillar collagen (Avitene, MedChem, Woburn, MA) was added to the PVA particulate solution. Angiography showed occlusion of the SDAVF in all 14 patients.

Fig. 3. Radiograph depicting rich collateral arterial supply of spinal dura, which is most prominent in area of nerve root sheaths (16, 17). (Reprinted from Manelfe et al (16) by permission of the journal.)

Results

After embolization, all 14 patients initially had improvement in their clinical symptoms. One patient had temporary worsening of preexisting weakness of the left lower extremity that subsequently improved beyond the level before embolization.

After initial improvement, 11 of the 14 patients had worsening of their symptoms 1–25 months (mean, 7 months) after their first embolization procedure. Of these 11 patients, nine had angio-

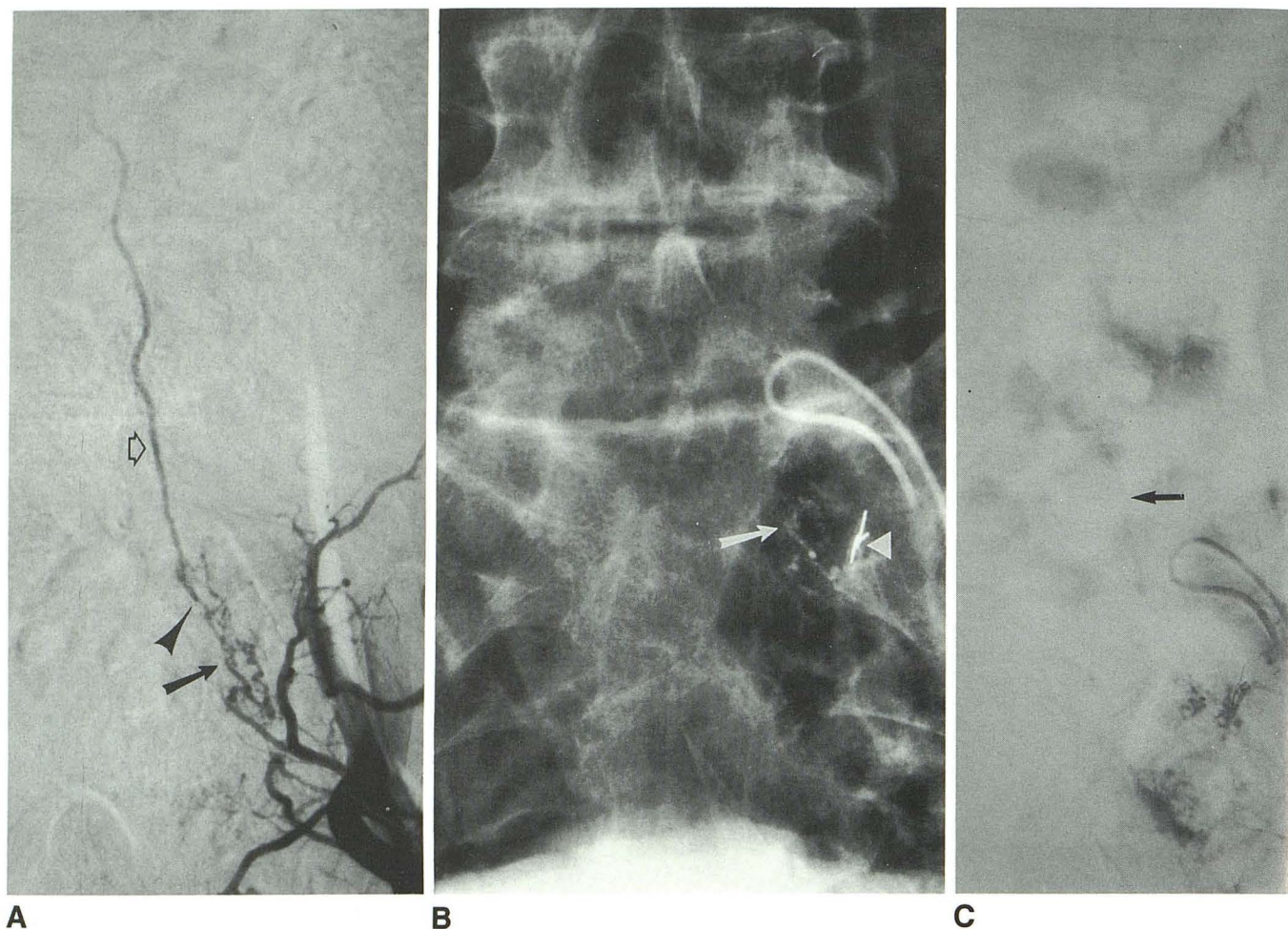


Fig. 5. SDAVF involving left S1 nerve root.

A, Angiogram obtained before embolization. Arterial supply to SDAVF is from left superior lateral sacral artery. Arrow demonstrates dural arterial collateral network; arrowhead demonstrates fistula site; and open arrow demonstrates draining radicular vein.

B, Radiograph after NBCA embolization demonstrates deposition of NBCA within dural arterial collateral network (arrow). Arrowhead demonstrates "protective" coils placed in muscular branch prior to NBCA embolization.

C, Control angiogram obtained immediately after NBCA embolization demonstrates persistent faint opacification of draining vein (arrow). Surgery was performed the next day to remove the SDAVF.

graphically proven recurrences of their SDAVF, and two had negative spinal angiography.

Four patients with recurrence underwent a second embolization procedure with PVA particles. A complication in one of these patients was a tripareisis secondary to inadvertent embolization of an upper thoracic anterior spinal artery arising one level higher than the intercostal artery supplying the SDAVF. Twenty-two months after the second embolization procedure, angiography demonstrated recurrence of the SDAVF. One patient improved clinically after the second embolization but later deteriorated and had an angiographically proven recurrence 9 months after the second embolization. One patient showed no improvement after the second embolization and had an angiographically proven recurrence 1 month

after the second embolization. One patient showed no improvement after the second embolization and has declined further follow-up evaluation.

Illustrative Case

A 56-year-old man presented with a 10-month history of intermittent paresthesias of the left lower extremity and a 3-week history of severe low-back pain, progressive urinary retention, constipation, and weakness of the distal right lower extremity. Physical examination demonstrated right ankle clonus, decreased strength of the rectal sphincter, mild weakness of the distal lower extremities (on the right more than the left), and numbness to pain along the lateral aspects of

both feet and of the left perianal region. Lumbar myelography (with water-soluble contrast agent), performed elsewhere before transfer to our institution, was negative from the cul-de-sac to L1. The spinal canal above the L1 level was not examined. Subsequent myelography performed at our institution demonstrated multiple vessels in the low thoracic region that were consistent with an SDAVF. A spinal angiogram (Fig. 1A) demonstrated an SDAVF arising from the left T10 intercostal artery that had enlarged draining medullary veins along the posterior surface of the lower thoracic spinal cord and conus. The SDAVF was embolized with PVA particles (100–300 μ m in diameter), and angiography performed immediately after embolization demonstrated occlusion of the SDAVF (Fig. 1B). After embolization, the lower extremity weakness improved and bowel and bladder functions returned to normal. However, 8 months after the embolization procedure, urinary retention and lower extremity weakness recurred subacutely. Spinal angiography demonstrated recurrence of the SDAVF (Fig. 1C), and it was again embolized and occluded with PVA particles (100–300 μ m in diameter). The symptoms and findings on physical examination remained stable for another 8 months, when the lower extremity weakness worsened. A spinal angiogram again demonstrated recurrence of the SDAVF. The SDAVF was then treated surgically. A laminectomy was performed and the draining vein arising from the left T10 SDAVF was coagulated. At follow-up 8 months after operation, bowel and bladder functions had returned and lower extremity strength was normal. The strength of the rectal sphincter and results of sensory examination were unchanged from the initial evaluation.

Discussion

We retrospectively reviewed the histories and angiographic findings of 14 consecutive patients with SDAVF who had embolization with PVA particles as the initial form of treatment. Eighteen such procedures were performed on these 14 patients. Angiographically proven recurrences occurred after 14 of the embolization procedures. Two patients with clinical signs and symptoms suggestive of recurrence had negative results on subsequent spinal angiograms. Only three patients had sustained improvement of their clinical symptoms after particulate embolization.

Several reports (9, 10, 14, 15) advocate operation as the treatment of choice. Symon et al (15) reported arrest of a "previously progressive disturbance of gait" in 39 of 46 surgically treated patients and improvement of disturbed gait in 32 of the 46 patients. Control of micturition improved in 26 of the 46 patients.

Several reports advocate embolization with liquid adhesives (NBCA has replaced isobutyl-2-cyanoacrylate (IBCA)) as the preferred treatment for SDAVF (2, 3, 11, 12). Merland et al (3) reported the largest series of patients treated by this technique. Of their 45 patients with SDAVF 31 had their SDAVF successfully occluded by IBCA embolization. The 14 remaining patients required operation because the occlusion occurred in the arterial feeder proximal to the AV shunt. Of the 42 patients available for follow-up review 3 months to 7 years after treatment, 31 had had immediate or delayed clinical improvement.

In Figure 2, the vascular nidus is within the dural covering of the nerve root. Arterial supply is from the dural branch of the spinal ramus of the intercostal or lumbar artery. The fistula is drained intradurally by retrograde flow through a single radicular vein to dilated, tortuous, and congested medullary veins.

SDAVF can be treated successfully only by permanently occluding the nidus or fistula or the proximal portion of the draining vein. Although angiography indicates that particulate embolization is successful initially, in most cases the actual site of occlusion is proximal to the fistula site and subsequent recanalization of the occluded artery or recruitment of dural collaterals (Figs. 2 and 3) will lead to recurrence of the SDAVF.

The size of the AV fistula varies (approximately 0.5–1.5 mm in diameter in our series), and in some instances it may be large enough to allow passage of particles into the draining vein so that small branches of the medullary veins are occluded (top inset of Fig. 2). This may be a cause of the neurologic complications that occasionally occur after embolization procedures. This highlights the potential risk of any embolization procedure performed for the treatment of SDAVF. Agents used to occlude the SDAVF that pass through the AV fistula and lodge within the venous system may compromise the precarious venous outflow of the spinal cord and thereby worsen the myelopathy.

The arteries that supply the SDAVF are usually smaller than the AV shunt itself; this observation

is consistent with the rich arterial network of the dura (16) and explains the recurrences observed in our series and in other reported series (9, 10). To obtain an occlusion at the level of the AV shunt, a material is needed that is able to reach a large shunt through small arteries.

Embolization of SDAVFs with NBCA allows permanent occlusion of these lesions. For NBCA embolization to be successful, the fistula site or the proximal portion of the draining vein or both must be occluded (Fig. 4). If the NBCA polymerizes in the feeding artery proximal to the fistula (Fig. 5), surgery should be performed without delay to interrupt the draining vein.

Two contraindications to NBCA embolization exist (2, 3). If the anterior spinal artery arises from the same intercostal artery as the dural artery that supplies the SDAVF, then the risk of NBCA embolization is too high and surgery is recommended. Surgery is also the treatment of choice if the dural artery that supplies the SDAVF cannot be catheterized selectively so that NBCA embolization can be safely performed. Another possible contraindication to NBCA embolization is location of the SDAVF in a middle to upper thoracic level. In the upper thoracic region, the draining vein (before it joins the medullary venous system) is usually shorter than it is if the SDAVF is located in the lower thoracic or lumbosacral regions. Therefore, the "margin of error" for late polymerization of NBCA in the draining vein without polymerization occurring in the medullary venous system is less in the upper and middle thoracic regions.

We recommend that NBCA embolization be the preferred initial treatment for SDAVF. The probability of success and the complication rates are comparable in the largest reported series of NBCA embolization and operation for the treatment of SDAVF (3, 15). NBCA embolization is a less invasive technique than surgery, and the patient usually can start a rehabilitative program the day after the embolization procedure (the interval to rehabilitation is several days after a surgical procedure). In addition, in most cases when NBCA embolization is unsuccessful, surgery is still an alternative. Surgery as the initial

treatment should be reserved for cases in which the anterior spinal artery arises from the same pedicle supplying the SDAVF or in which selective catheterization of the arterial supply to the SDAVF is not possible.

References

1. Kendall BE, Logue V. Spinal epidural angiomatous malformations draining into intrathecal veins. *Neuroradiology* 1977;13:181-189
2. Merland JJ, Riche MC, Chiras J. Intraspinal extramedullary arteriovenous fistulae draining into the medullary veins. *J Neuroradiol* 1980;7:271-320
3. Merland JJ, Assouline E, Rufenacht D, Guimaraens L, Laurent A. Dural spinal arteriovenous fistulae draining into medullary veins: clinical and radiological results of treatment (embolization and surgery) in 56 cases. *Excerpta Med Int Congr Ser* 1986;698:283-289
4. Benhaïem N, Pairier J, Hurth M. Arteriovenous fistulae of the meninges draining into the spinal veins: a histologic study of 28 cases. *Acta Neuropathol (Berl)* 1983;62:103-111
5. Aminoff MJ, Barnard RO, Logue V. The pathophysiology of spinal vascular malformations. *J Neurol Sci* 1974;23:255-263
6. Hassler W, Thron A, Grote E. Hemodynamics of spinal dural arteriovenous fistulas: an intraoperative study. *J Neurosurg* 1989;70:360-370
7. Doppman JL, Di Chiro G, Ommaya AK. Percutaneous embolization of spinal cord arteriovenous malformations. *J Neurosurg* 1971;34:48-55
8. Djindjian R, Merland JJ, Djindjian M, Houdart R. Place de l'embolisation dans le traitement des malformations artério-veineuses médullaires à propos de 38 cas. *Neuroradiology* 1978;16:428-429
9. Hall WA, Oldfield EH, Doppman JL. Recanalization of spinal arteriovenous malformations following embolization. *J Neurosurg* 1989;70:714-720
10. Morgan MK, Marsh WR. Management of spinal dural arteriovenous malformations. *J Neurosurg* 1989;70:832-836
11. Russell EJ, Berenstein A. Neurologic applications of interventional radiology. *Neurol Clin* 1984;2:873-902
12. Scialfa G, Scotti G, Biondi A, De Grandi C. Embolization of vascular malformations of the spinal cord. *J Neurosurg Sci* 1985;29:1-9
13. Choi IS, Berenstein A. Surgical neuroangiography of the spine and spinal cord. *Radiol Clin North Am* 1988;26:1131-1141
14. Oldfield EH, Di Chiro G, Quindlen EA, Rieth KG, Doppman JL. Successful treatment of a group of spinal cord arteriovenous malformations by interruption of dural fistula. *J Neurosurg* 1983;59:1019-1030
15. Symon L, Kuyama H, Kendall B. Dural Arteriovenous malformations of the spine: clinical features and surgical results in 55 cases. *J Neurosurg* 1984;60:238-247
16. Manelfe C, Lazorthes G, Rouleau J. Arteries de la dure-mère rachidienne chez l'homme. *Acta Radiol Diagn* 1972;13:829-841
17. Manelfe C. Contribution à l'étude de la vascularisation artérielle de la dure-mère rachidienne chez l'homme: étude anatomo-radiologique et histologique. Considérations pathologiques. Thèse médicale, Toulouse, 1969

Please see the Commentary by Choi on page 941 in this issue.