



Get Clarity On Generics

Cost-Effective CT & MRI Contrast Agents

**FRESENIUS
KABI**

[WATCH VIDEO](#)

AJNR

Aneurysms of spinal arteries associated with intramedullary arteriovenous malformations. I. Angiographic and clinical aspects.

A Biondi, J J Merland, J E Hodes, J P Pruvo and D Reizine

AJNR Am J Neuroradiol 1992, 13 (3) 913-922

<http://www.ajnr.org/content/13/3/913>

This information is current as
of August 21, 2025.

Aneurysms of Spinal Arteries Associated with Intramedullary Arteriovenous Malformations. I. Angiographic and Clinical Aspects

A. Biondi,^{1,2} J. J. Merland,¹ J. E. Hodes,¹ J. P. Pruvo,¹ D. Reizine¹

Purpose: To evaluate the nature of aneurysms of the spinal arteries, their relative frequency, and the risks associated with these lesions. **Methods:** We retrospectively reviewed the spinal angiographic studies of 186 patients with spinal cord vascular malformations—70 intramedullary AVMs, 44 extra (peri) medullary AV fistulas, and 72 dural AV fistulas. **Results:** Fifteen spinal artery aneurysms (SAs) in 14 out of 70 patients (20%) with an intramedullary AVM were discovered. No SAs were observed in the other types of spinal vascular malformations. The intramedullary AVMs with SAs were cervical in seven cases and thoracic in the other seven cases (one of the thoracic had two SAs). Fourteen SAs were located on a major feeding vessel to the associated intramedullary AVM (10 on the anterior spinal artery and four on a posterior spinal artery and only one SA was located remote from the AVM feeding vessels. This remote aneurysm was located on the intercostal artery feeding a vertebral angioma in a patient with metameric angiomatosis. Subarachnoid hemorrhage occurred in all cases of SA. The presence of a SA carried a statistically significant ($P < .05$) increase in the risk of bleeding. **Conclusions:** Although increased blood flow seems to be an important factor in formation of these SAs associated with intramedullary AVMs, the role of a developmental vascular anomaly must be stressed: metameric angiomatosis was found in six out of the 14 patients (43%).

Index terms: Arteriovenous malformations, spinal; Spine, angiography; Aneurysm, arteriovenous; Fistula, arteriovenous

AJNR 13:913–922, May/June 1992

The term “spinal aneurysm” (arterial aneurysm, venous aneurysm, cirroid aneurysm, arteriovenous aneurysm) has been imprecisely used to describe varied spinal vascular malformations. Spinal angiography has facilitated a correct understanding and classification of these lesions. Spinal vascular malformations are divided into “true” intramedullary arteriovenous malformations (AVMs), extra (peri) medullary arteriovenous (AV) fistulas, and dural AV fistulas (1). In this paper we use the term spinal aneurysms (aneurysms of the spinal arteries) in a more restrictive sense to describe lesions analogous to aneurysms

of cerebral vessels. Spinal aneurysms (SAs) are localized dilatations of arteries feeding the spinal cord and, more rarely, of those arteries feeding the spine. SAs are rare lesions and, to our knowledge, only a few cases have been reported, whether isolated (2–13) or associated with spinal cord vascular malformations (14–25).

The concomitant presence of a cerebral AVM with an intracranial aneurysm is well known (26–50) and has a reported frequency of between 2.7% and 16.7% (28–30, 34, 41, 45, 47). Several theories explaining the pathogenesis of associated cerebral AVMs and aneurysms have been proposed (28–30, 33–38, 40–42, 45–48).

The purpose of our study was to report our series of SAs and review the published literature in order to come to a better understanding of these lesions and of their association with spinal vascular malformations. In addition, because some authors (17, 19) have reported an increased risk of bleeding when an intramedullary AVM is associated with a SA, we specifically evaluated the incidence of bleeding in patients that harbor

Received May 15, 1991; accepted and revisions requested August 6; revisions received November 6.

¹ University of Paris VII, Lariboisiere Hospital, Department of Neuro-radiology and Therapeutic Angiography, 2, rue Ambroise Pare, 75010 Paris, France.

² Address reprint requests to Alessandra Biondi, Pitié-Salpêtrière Hospital, Department of Neuroradiology, 47 Boulevard de l'hôpital, 75013 Paris, France.

AJNR 13:913–922, May/June 1992 0195-6108/92/1303-0913

© American Society of Neuroradiology

TABLE 1: Spinal aneurysms associated with intramedullary AVMs

Case/ Sex	Age	SAH	AVM Level	AVM Feeders	Spinal Aneurysm Location		Met Ang
					Artery	Segment	
1/M	14	3	C5	1 ASA 4 PSA	ASA, (R deep cervical)	medullary	
2/M	20	1	C5-C7	3 ASA 2 PSA	ASA, (L deep cervical)	radicular	
3/F	22	2	C6-C7	1 ASA 2 PSA	ASA, (L deep cervical)	radicular	
4/F	16	3	C5	1 ASA 2 PSA	ASA, (R thyrocervical trunk)	medullary	muscle, subcutaneous tissue
5/F	22	1	C5-C6	2 ASA 2 PSA	ASA, (R deep cervical)	medullary	
6/F	12	3	C4-C5	2 ASA	ASA, (R deep cervical)	radicular medullary junction	dura, bone, muscle, R sup limb
7/F	35	1	C7	1 ASA 2 PSA	ASA, (R deep cervical)	medullary	
8/M	13	2	T7-T8	1 ASA	ASA (L T10)	medullary	bone
(2 SAs)				1 PSA	PSA (L T9)	medullary	
9/F	16	1	T4-T6	2 ASA 2 PSA	PSA (L T6)	radicular	skin
10/M	32	2	T8-T9	3 ASA 2 PSA	ASA (L T9)	radicular medullary junction	
11/F	18	1	T9-T10	2 ASA 2 PSA	ASA (R T9)	medullary	
12/M	26	1	T9-T10	2 ASA 2 PSA	PSA (L T11)	medullary	dura, soft tissue
13/M	37	1	T11	1 ASA 2 PSA	PSA (L L1)	radicular	
14/M	17	1	T5-T6	2 ASA 1 PSA	L T5	Intercostal artery	dura, bone

Note.—C = cervical; T = thoracic; M = male; F = female; R = right; L = left; Met Ang = metamerism angiomas.

this combination of lesions. Criteria for the diagnosis of SAs, angiographic findings, and pathophysiologic aspects are reported.

Materials and Methods

The conventional (nondigital) spinal angiographic studies of 186 patients with spinal cord vascular malformations (70 intramedullary AVMs, 44 extra (peri) medullary AV fistulas, and 72 dural AV fistulas) were reviewed. Among the 70 intramedullary AVMs, two groups were identified and compared: one group with associated SAs (14 cases), and the other group without SAs.

Angiographic criteria for the diagnosis of SA were the following: SAs must be visualized on an arterial vessel during the initial arterial phase; selective injections in both

frontal and lateral views must eliminate dilated vessels or vessel coilings mimicking aneurysms. Aneurysmal dilations within the nidus of the intramedullary AVM itself (compatible with true aneurysms, pseudoaneurysms, or venous ectasias), aneurysms of the anterior spinal artery associated with coarctation of the aorta, and venous pouches were excluded.

Spinal angiography was performed with selective injection of all pedicles. Angiotomography was available in nine of the 14 patients with an associated SA.

Results

Clinical and angiographic findings are summarized in Table 1. Fifteen SAs were identified in 14 out of 70 patients (20%) with an intramedullary

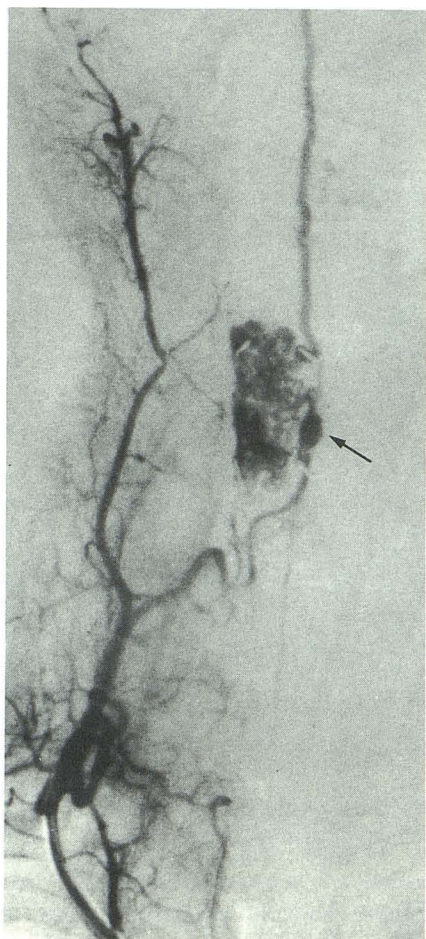


Fig. 1. Case 5. Aneurysm of the anterior spinal artery (arrow) associated with a cervical intramedullary AVM. Anteroposterior view of the right deep cervical artery angiogram. Aneurysm is on the medullary segment of the ASA and proximal to the nidus of the AVM.

AVM (Figs. 1–5). SAs were not found in the 44 cases of extra (peri) medullary AV fistulas or the 72 cases of dural AV fistulas reviewed. In all spinal arteriograms reviewed in our department we never observed an isolated SA. There were eight males and six females among the patients with associated SAs. Mean age of presentation was 18.5 years (range 12–37). Subarachnoid hemorrhage (SAH) occurred in all cases. Clinical onset of symptoms was due to SAH in 12 patients and progressive neurologic deficits, preceding SAH, in two. Six of the 14 patients (43%) had recurrent bleeding episodes before the initiation of treatment (cervical four cases, thoracic two cases). In two patients, the SAH occurred during pregnancy. In the remaining 56 patients with isolated intramedullary AVMs (23 cervical, 33 thoracic), the mean age of presentation was 21.5 years (range 6–40). Bleeding occurred in 39/56 patients (70%) with isolated intramedullary AVMs

(83% of cervical AVMs, 61% of thoracic AVMs) while progressive neurologic deficits without bleed was noted in 17/56 (30%). Recurrent bleeding occurred in 13/56 (23%) cases (30% of cervical AVMs, and 12% of thoracic AVMs).

Statistical analysis (χ^2 test with Yates correction) of the results (SAH in 14/14 of intramedullary AVMs with associated SA and in 39/56 of isolated AVMs) indicates that the existence of a spinal aneurysm in a patient with an intramedullary AVM carries an increased risk of bleeding ($P < .05$).

The intramedullary AVMs associated with SAs were cervical in seven patients and thoracic in the other seven patients. All of these AVMs had multiple feeders (from 2 to 5, mean 3.6). Fourteen SAs were located on one of the main, high-flow feeding vessels of the AVM: 10 on the anterior spinal artery (ASA) (seven cervical, three thoracic), and four on a posterior spinal artery (PSA) (all thoracic). SAs were found on both radicular (three) and medullary (eight) segments of the spinal arteries, and at the radiculo-medullary junction of the ASA (two). In one case, the aneurysm was located on a large sulco-commissural artery of the ASA. Only one aneurysm was found remote to the intramedullary AVM. It arose from the intercostal artery (dural radicular spinal artery) that fed a vertebral angioma in a patient with metamerism angiomas (Fig. 5). One patient (case 8) had two SAs on two feeders to the AVM: one on the ASA and the other on a PSA (Fig. 2). In a patient (case 11) with an isolated intramedullary AVM, serial angiographic studies demonstrated the appearance of a small SA on a sulco-commissural artery of the ASA 2 years after the first angiogram (Fig. 4). No intercurrent bleeding was observed in this case. The diameter of the SAs ranged from 2 to 15 mm.

Metameric angiomas involving all or parts of the neighboring structures such as dura, bone, muscle, subcutaneous tissue, and/or skin was present in six out of 14 (43%) patients (two cervical, four thoracic AVMs) (seven out of 15 (47%) SAs). In one patient (case 6) the metamerism angiomas extended to the right upper limb. In one patient (case 12) with metamerism angiomas, the parent vessel of the SA was dysplastic. In the 56 patients with isolated intramedullary AVMs, 18 had metamerism angiomas (32%) (seven cervical, 11 thoracic AVMs).

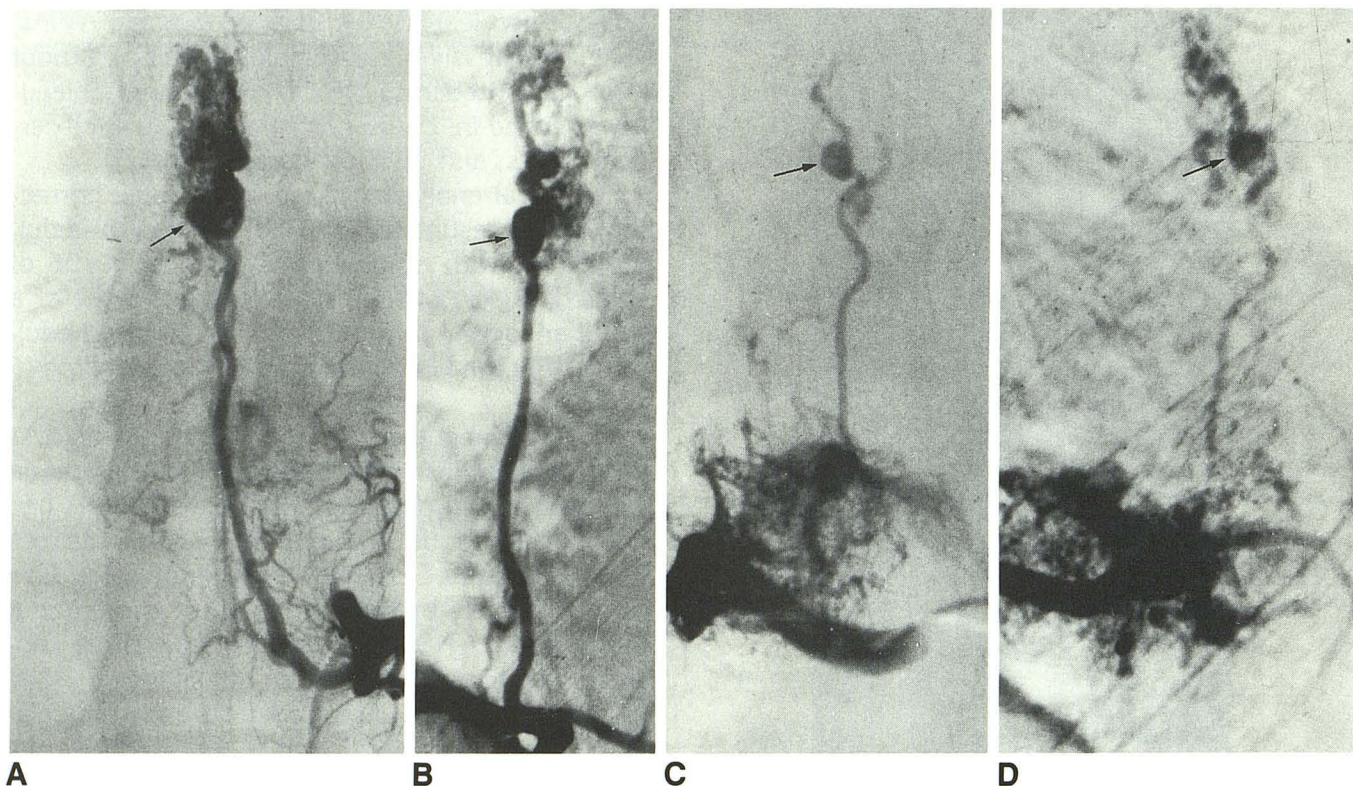


Fig. 2. Case 8. Two SAs associated with a thoracic T7-T8 intramedullary AVM. Anteroposterior (A) and lateral (B) view of left 10th intercostal artery angiogram showing aneurysm of the ASA (arrow). Anteroposterior (C) and lateral (D) view of left ninth intercostal artery angiogram show the PSA with a SA (arrow).

Discussion

SAs (aneurysms of the spinal arteries) are localized dilations of arteries feeding the spinal cord and, more rarely, of those arteries feeding the spine. SAs are located on the ASA more often than on the PSA. They can originate from different segments of these vessels: radicular, medullary, at the radiculo-medullary junction, and from a sulco-commissural artery leading to an associated intramedullary AVM.

In this study, we excluded the SAs of the ASA associated with coarctation of the aorta. It is well known that in cases of stenosis of the aorta and femoral arteries, the ASA and also the internal thoracic arteries are important collateral pathways. In this "hypertrophied spinal artery syndrome" a SA may arise from the dilated and tortuous ASA because of hemodynamic changes and degeneration of the elastic fibers of the artery (51). Saccular dilations and venous ectasias within the nidus of an intramedullary AVM have often been described as SAs (16, 21). An intradural dilatation could correspond to a true aneurysm or to a pseudoaneurysm (52). The latter forms at the site of bleeding as a result of the organization of a hematoma in the surrounding

tissue. These lesions do not correspond to an aneurysm of the spinal arteries as we have defined. In addition, in some cases of extra (peri) medullary AV fistula, (which are defined as a direct AV shunt between one or more medullary arteries and a perimedullary vein) the venous pouch, which is often detected at the site of the shunt, has been reported as a SA (15, 18, 19 (in Ref. 19, one out of two cases)) (Fig. 6).

To our knowledge, 12 isolated SAs and 15 SAs associated with a spinal vascular malformation have been reported. A precise review of the literature is difficult because angiographic studies had been performed only in five out of the 12 isolated SAs, and in 11 of the 15 AVM-associated SAs. In the remaining cases, diagnosis was based on surgical or postmortem findings.

Isolated SAs are very rare lesions. In the experience of our department, we have never encountered such a lesion. Their rarity is thought to be related to the small caliber of spinal vessels and the infrequency with which they are affected by atherosclerosis (7). Among the 12 cases (2-13) reported in the literature, only seven can be considered as true SAs. Five cases should be excluded for the following reasons: in two cases

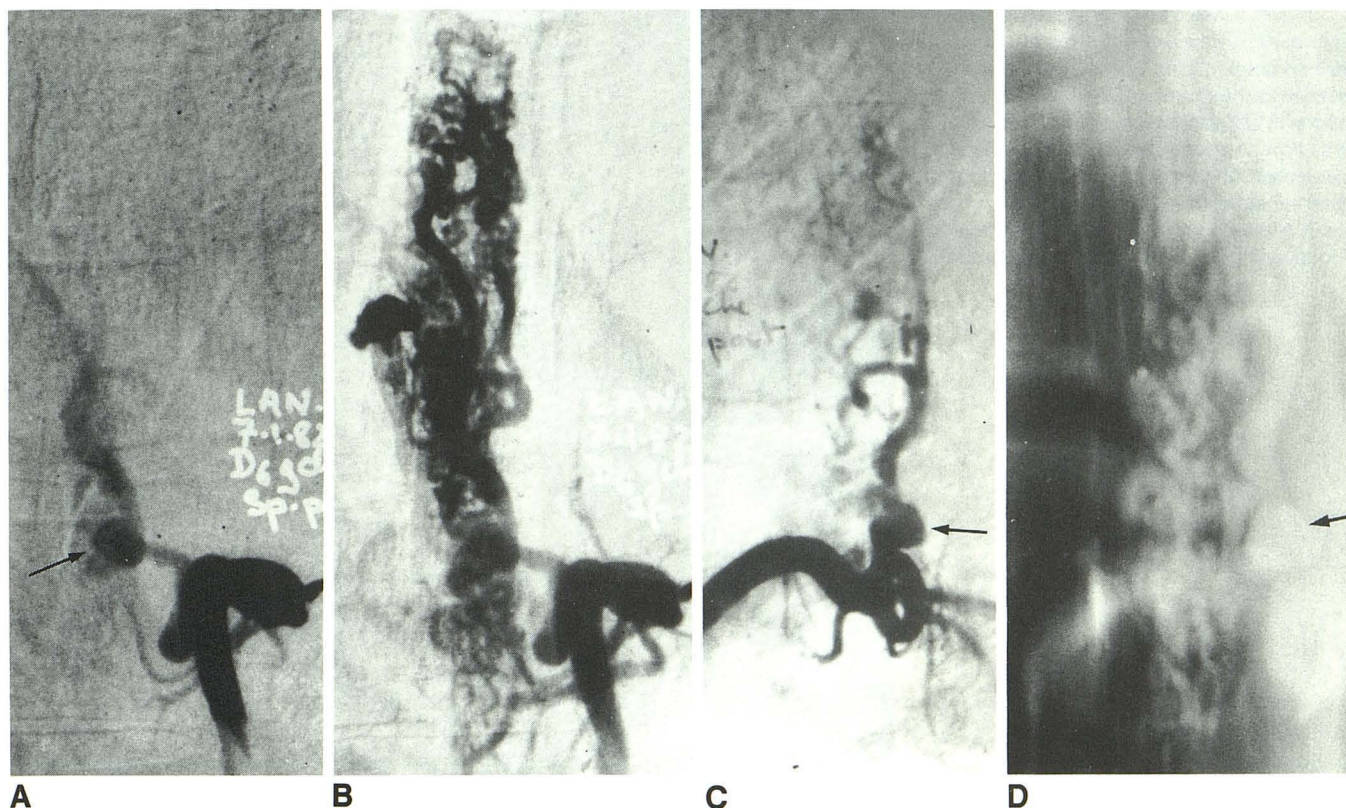


Fig. 3. Case 9. Aneurysm (arrows) of the radicular portion of a PSA feeding a T4-T6 intramedullary AVM. Anteroposterior view of left sixth intercostal artery angiogram early (A) and late phase (B). Lateral projection conventional angiogram (C) and lateral angiotomogram (D) confirm the presence of the aneurysm (arrows).

(2, 8) without angiography, the surgical description suggested an extramedullary AV fistula and not a SA; in a third case (5), also without angiography, surgical findings were indicative of a spinal AVM; a fourth case (6) was associated with aortic coarctation, and a fifth case (9, 12) was reported twice by two different authors. Of the remaining seven isolated SAs, angiography was performed in four cases. Three SAs (3, 7, 10) were thoracic (two on ASA and one on an anterior radicular artery) and four (4, 9, 11, 13) were located in the cervical region at the C1-C2 level (three on the ASA and one on a PSA). Bleeding occurred in five of these seven patients with an isolated SA.

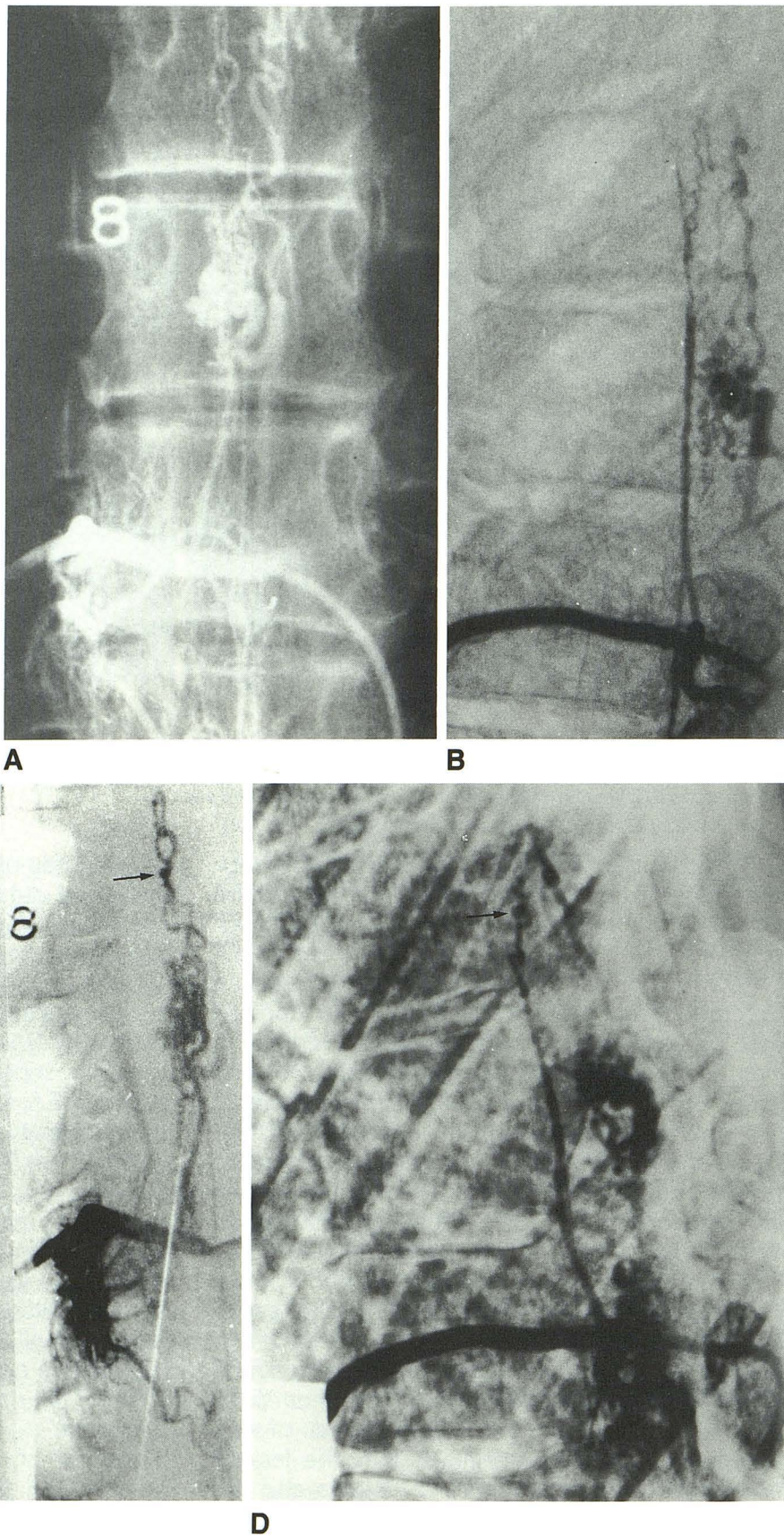
Among the fifteen SAs associated with a spinal AVM reported in the literature (14–25), seven lesions can not be considered as true SAs. In two cases (16, 21), the aneurysmal sac was found within the spinal AVM itself. In another three cases (15, 18, 19 (in Ref. 19, one out of two cases)) the illustrations suggest that the lesions were extra (peri) medullary AV fistulas and the described SA was actually the dilated venous pouch at the site of the AV shunt. In two cases (20, 23) in which angiography was not performed,

the pictures of the surgical findings were ambiguous and did not distinguish between an extramedullary AV fistula or a SA with a spinal AVM. The remaining eight well-documented SAs (14, 17, 19, 22, 24, 25) were associated with an intramedullary AVM. The clinical onset was reflected by SAH in all cases except one.

In our series of intramedullary AVMs, an associated SA was present in 20% of the cases. In the literature, this coexistence has been reported with a lower frequency (between 2.2% and 7.7%) (19, 22, 24), but it must be considered that, at the time of many of these reports, dural AV fistulas were not yet defined and extra (peri) medullary AV fistulas were often included and mistaken for intramedullary AVMs. In fact, if we consider in our series all types of spinal malformations (186 lesions), an associated aneurysm is found in only 7.5% of the cases, in agreement with the reported literature.

Review of the clinical histories of our series revealed no significant age differences at onset of symptoms between the 56 patients with isolated intramedullary AVMs and the 14 patients with an intramedullary AVM and associated SA.

Fig. 4. Case 11. Anteroposterior (A) and lateral (B) view of right ninth intercostal artery angiogram. Anterior spinal artery feeder to the thoracic T8-T9 level intramedullary AVM. No aneurysm was detected at this time. Anteroposterior (C) and lateral (D) projection 2 years after initial angiogram. Interval development of a small SA (arrow) on a sulco-commissural artery of the ASA. No bleeding occurred during interval time.



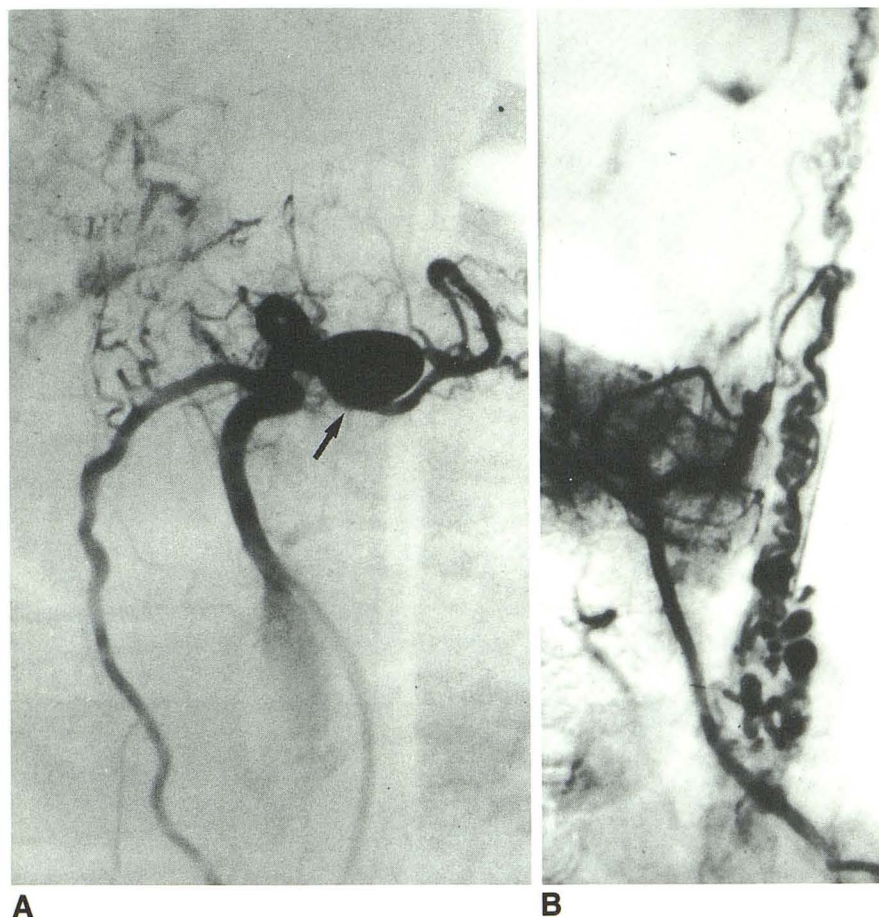


Fig. 5. Case 14.

A, Aneurysm (arrow) of the dural radiculo-medullary artery, anteroposterior view of left fifth intercostal artery angiogram, which feeds a vertebral angioma in a case of metamerism angiomatosis.

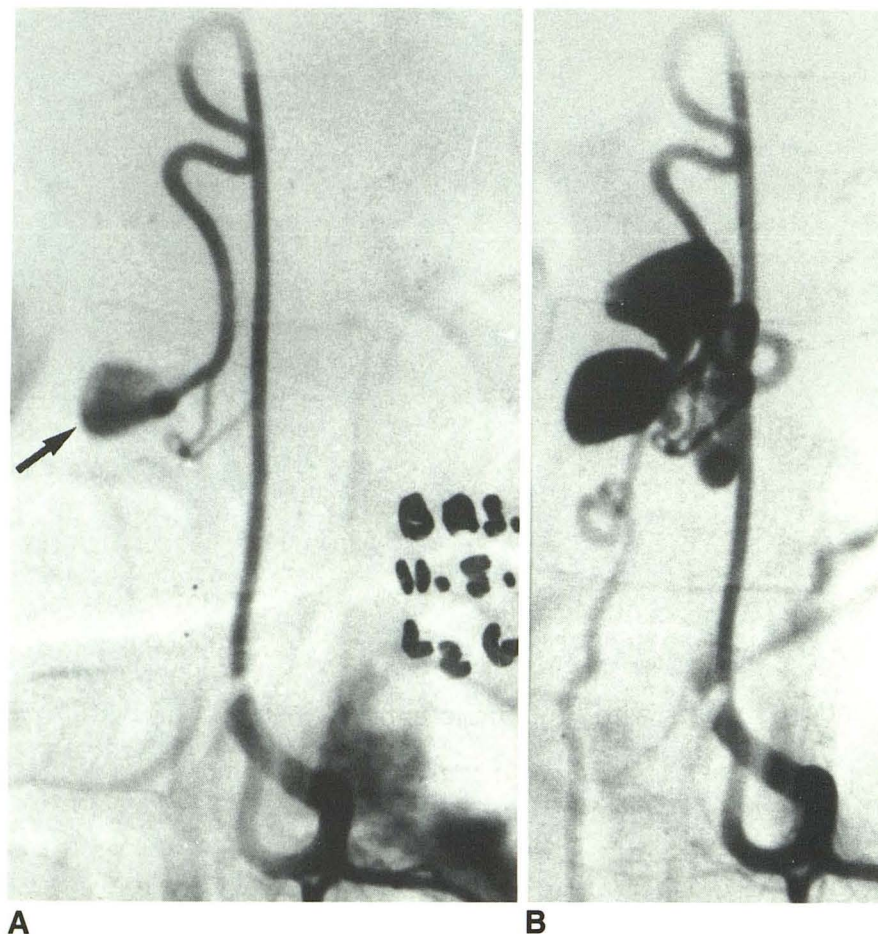
B, Lateral view of right fifth intercostal artery angiogram visualizes both spinal intramedullary AVM and the associated metamerism angiomatosis (vertebral angioma).

Some authors (38) assert that the risk of the development of an AVM-associated cerebral aneurysm and the risk of its bleeding increase with age. In contrast to the cerebral lesions (38, 40, 42, 45), we can not confirm this in the spinal location. As previously reported (17, 19), the incidence of SAH increases in the presence of an associated SA. Based on a statistical analysis, we conclude that there is a higher frequency of bleeding when an AVM is associated with a SA than when there is an isolated AVM ($P < .05$). In both cases (intramedullary AVMs with or without an associated SA) SAH is more frequent in cervical lesions. In Herdt's 1971 series (19) of 50 patients with spinal vascular malformations, SAH occurred in three cases; all three had associated SAs. The authors affirm that bleeding was never observed in patients who did not have coexistent aneurysms. This surprisingly low incidence of bleeding compared with our series (53) of intramedullary AVMs may be explained by the probability that the 1971 series included different types of spinal vascular malformations, including the most common, dural AV fistulas, which typ-

ically do not bleed, and were not recognized at that time. The source of bleeding is usually unknown and has been studied only in the cerebral location. The results in the literature are varied (28, 29, 43, 47) and it is impossible to conclude whether bleeding originates from the AVM or the aneurysm. The published results are in favor of a shared responsibility. It has been reported (54) that, in the brain, the coexistence of both lesions is a poor prognostic factor, associated with a 7% risk of hemorrhage per year as compared to 1.7%/year for patients with AVM alone. In another study (52), the association of an aneurysm with an AVM was not found to correlate highly with hemorrhage, while intracranial aneurysms were shown to be statistically significant in the history of bleeding.

The association of an aneurysm with an AVM has been studied in the cerebral location (26–50). This coexistence in the brain has been reported with an incidence between 2.7% and 16.7% (28–30, 34, 39, 41, 45, 47). Three theories have been suggested to explain this association in the brain (28, 29, 33–35, 37, 42, 46, 47): 1) hemodynamic

Fig. 6. Type II extra (peri) medullary AV fistula; no SA seen; anteroposterior view. Early (A) and late (B) arterial phase. In the literature, the venous ectasia at the site of the AV shunt (arrow) is often referred to as a SA.



factors, 2) a disorder of vascular development, and 3) a coincidence. Most authors (28, 33, 34, 36, 46, 47) support the hypothesis that increased blood flow and hemodynamic stresses in the feeding vessels to the AVM result in development of the aneurysm. Although the hypothesis that both lesions are due to the same developmental abnormality has been thought unlikely by some (40, 48), other authors (37, 45) believe that a combination of the first and second theories is more plausible. Defective vessel walls may favor the development of an aneurysm. Some authors (42) report defects in vascular collagen that may be essential in the formation of aneurysms in early life. Other authors (30) report that the coexistence of these lesions is coincidental and without any causal relationship. More recently (36, 38), cerebral aneurysms associated with an AVM have been classified into intralesional aneurysms, aneurysms proximal to the AVM, and remote or dysplastic aneurysms. The proximal (to the AVM) aneurysms seem to be AVM flow-dependent; they appear on arteries hemody-

namically related to the AVM (distal locations along the vascular pedicle, or proximal location along the feeding system to the AVM) and their topography is unusual for intracranial aneurysms. The remote or dysplastic aneurysms seem to be congenital; they develop on arteries remote to and hemodynamically unrelated to the AVM and they follow the usual distribution pattern of berry aneurysms. The dysplastic aneurysms seem to be associated with the AVM only coincidentally (41).

In terms of SAs, the three etiologies suggested for intracerebral AVM-associated aneurysms can be evaluated. Because of the rarity of isolated SAs, it is difficult to believe that the association of SAs and AVMs is coincidental. In addition, the SAs were located on the feeders of the AVM, suggesting the existence of a relationship between these two lesions. We feel that in some cases the SAs are flow-dependent and related to the associated AVM. In one of our patients (case 11), the SA was not present on the initial angiogram. Subsequent studies showed the develop-

ment of the SA on a sulco-commissural artery of the ASA. Similar results have been reported for cerebral aneurysms (28). While the other SAs were located on the spinal arteries in the subarachnoid space, this SA was the only one on a sulco-commissural artery, raising the possibility that it could be a pseudoaneurysm. This is deemed unlikely because there was no history of intercurrent bleeding. Although high flow to the AVM seems to be a frequent cause of SAs, the high frequency of metameric angiomatosis in our series suggests that an underlying disorder of vascular development must play a role in some cases. The fact that intramedullary AVMs with a SA are found to be associated with metameric angiomatosis with only a slightly higher frequency than isolated AVMs (respectively 43% and 32%) could suggest that the presence of metameric angiomatosis and a SA is coincidental. However, we feel that this finding is significant. We stress again that almost half of our SAs were found in patients with metameric angiomatosis. The presence or absence of a SA in metameric angiomatosis could be due to a different degree of expression of the vascular anomaly, as is seen in variable expression in other structures (skin, dura, etc). In addition, if we postulate that increased flow is the only factor responsible for the formation of SAs, it is difficult to explain why our SAs are associated only with intramedullary AVMs and why we have never found a SA associated with other high-flow lesions, such as extra (peri) medullary AV fistulas. Further findings that suggest a vascular developmental abnormality as a contributing factor include the patient with two SAs (case 8) and another with a SA on a dysplastic artery (case 12); both had metameric angiomatosis.

In conclusion, we have reported a relatively large series of true aneurysms of the spinal arteries and have differentiated them from other lesions often confused in the literature as SAs. Patients harboring AVMs and SAs bleed statistically more frequently than patients with isolated intramedullary AVMs. Although hemodynamic stresses in the feeding vessels to the AVM appear a frequent factor in the development of an associated aneurysm, the contribution of a vascular anomaly must be considered.

References

1. Riche MC, Reizine D, Melki JP, Merland JJ. Classification of spinal cord vascular malformations. *Radiat Med* 1985;3:17-24
2. Echols DH, Holcombe RG. Extramedullary aneurysm of the spinal cord. *New Orleans Med Surg J* 1941;93:582-583
3. Garcia CA, Dulcey S, Dulcey J. Ruptured aneurysm of the spinal artery of Adamkiewicz during pregnancy. *Neurology* 1979;29:394-398
4. Henson RA, Croft PB. Spontaneous spinal subarachnoid hemorrhage. *Q J Med* 1956;25:53-66
5. Kinal ME, Sejanovich C. Spinal cord compression by an intramedullary aneurysm: case report and review of the literature. *J Neurosurg* 1957;114:561-565
6. Kito K, Kobayashi N, Mori N, Kohno H. Ruptured aneurysm of the anterior spinal artery associated with pseudoxanthoma elasticum: case report. *J Neurosurg* 1983;58:126-128
7. Leech PJ, Stokes BAR, Apsimon T, Harper C. Unruptured aneurysm of the anterior spinal artery presenting as paraparesis. *J Neurosurg* 1976;45:331-333
8. Merry GS, Appleton DB. Spinal arterial malformation in a child with hereditary hemorrhagic telangiectasia. *J Neurosurg* 1976;44:613-616
9. Moore DW, Hunt WE, Zimmerman JE. Ruptured anterior spinal artery aneurysm: repair via a posterior approach. *Neurosurgery* 1982;10:626-629
10. Saunders FW, Birchard D, Willmer J. Spinal artery aneurysm. *Surg Neurol* 1987;27:269-272
11. Thompson RL. Aneurysm in the cervical spinal canal. *Med J Aust* 1980;1:220-220
12. Vincent FM. Anterior spinal artery aneurysm presenting as a subarachnoid hemorrhage. *Stroke* 1981;12:230-232
13. Yonas H, Patre S, White RJ. Anterior spinal artery aneurysm: case report. *J Neurosurg* 1980;53:570-573
14. Avman N, Özkal E, Gökben B. Aneurysm and arteriovenous malformation of the spinal cord. *Surg Neurol* 1979;11:5-6
15. Carosio JT, Brannan T, Budabin M, et al. Subarachnoid hemorrhage secondary to spinal arteriovenous malformation and aneurysm: report of a case and review of the literature. *Arch Neurol* 1980;37:101-103
16. Deeb ZL, Rosenbaum AE, Bensy JJ, Scarf TB. Calcified intramedullary aneurysm in spinal angioma. *Neuroradiology* 1977;14:1-3
17. Di Chiro G, Wener L. Angiography of the spinal cord: a review of contemporary techniques and applications. *J Neurosurg* 1973;39:1-29
18. Di Chiro G, Doppman JL, Dwyer AJ, et al. Tumors and arteriovenous malformations of the spinal cord: assessment using MR. *Radiology* 1985;156:689-697
19. Herdt JR, Di Chiro G, Doppman JL. Combined arterial and arteriovenous aneurysms of the spinal cord. *Radiology* 1971;99:589-593
20. Hopkins CA, Wilkie FL, Voris DC. Extramedullary aneurysm of the spinal cord: case report. *J Neurosurg* 1966;24:1021-1023
21. Kunc Z, Bret J. Diagnosis and treatment of vascular malformations of the spinal cord. *J Neurosurg* 1969;30:436-445
22. Miyamoto S, Kikuchi H, Karasawa J, Ikota T, Nagata I. Spinal cord arteriovenous malformations associated with spinal aneurysms. *Neurosurgery* 1983;13:577-580
23. Pia HW. Diagnosis and treatment of spinal angiomas. *Acta Neurochir (Wien)* 1973;28:1-12
24. Vogelsang H, Dietz H. Cervical spinal angioma combined with arterial aneurysm. *Neuroradiology* 1975;8:223-228
25. Yasargil MG, Delong WB, Guarnschelli JJ. Complete microsurgical excision of cervical extramedullary and intramedullary vascular malformations. *Surg Neurol* 1975;4:211-224
26. Aarabi B, Chambers J. Giant thrombosed aneurysm associated with an arteriovenous malformation: case report. *J Neurosurg* 1978;49:278-282
27. Arai H, Sugiyama Y, Kawakami S, Miyazawa N. Multiple intracranial aneurysms and vascular malformations in an infant. case report. *J Neurosurg* 1972;37:357-360

28. Azzam CJ. Growth of multiple peripheral high flow aneurysms of the posterior inferior cerebellar artery associated with a cerebellar arteriovenous malformation. *Neurosurgery* 1987;21:934-939
29. Batjer H, Suss RA, Samson D. Intracranial arteriovenous malformations associated with aneurysms. *Neurosurgery* 1986;18:29-35
30. Body-Wilson JS. The association of cerebral angioma with intracranial aneurysms. *J Neurol Neurosurg Psychiatry* 1959;22:218-223
31. Caram PC. Simultaneous occurrence of intracranial aneurysm and angioma. case report. *J Neurosurg* 1959;16:230-232
32. Caram PC, Sharkey PC, Alvord EC. Thalamic angioma and aneurysm of the anterior choroidal artery with intraventricular hematoma. *J Neurosurg* 1960;17:347-352
33. Cronqvist S, Troupp H. Intracranial arteriovenous malformation and arterial aneurysm in the same patient. *Acta Neurol Scand* 1966;42:307-316
34. Hayashi S, Arimoto T, Itakura T, et al. The association of intracranial aneurysms and arteriovenous malformation of the brain. *J Neurosurg* 1981;55:971-975
35. Higashi K, Hatano M, Yamashita T, Inoue S, Matsumura T. Coexistence of posterior cerebellar artery aneurysm and arteriovenous malformation fed by the same artery. *Surg Neurol* 1979;12:405-408
36. Kondziolka D, Nixon BJ, Lasjaunias P, Tucker WS, Terbrugge K, Spiegel SM. Cerebral arteriovenous malformations with associated arterial aneurysms: hemodynamic and therapeutic considerations. *Can J Neurol Sci* 1988;15:130-134
37. Koulouris S, Rizzoli HV. Coexisting intracranial aneurysm and arteriovenous malformation: case report. *Neurosurgery* 1981;8:219-222
38. Lasjaunias P, Piske R, Terbrugge K, Willinsky R. Cerebral arteriovenous malformations (CAVM) and associated arterial aneurysms (AA). *Acta Neurochir (Wien)* 1988;91:29-36
39. Minamikawa J, Kikuchi H, Karasawa J, et al. A case of spontaneous disappearance of aneurysm associated with arteriovenous malformation (abstr). 13th Annual Meeting of the Japanese Neuroradiological Society Neuroradiology. 1985;27:92
40. Miyasaka K, Wolpert SM, Prager RJ. The association of cerebral aneurysms, infundibulae, and intracranial arteriovenous malformations. *Stroke* 1982;13:196-203
41. Okamoto S, Handa H, Hashimoto N. Location of intracranial aneurysms associated with cerebral arteriovenous malformation: statistical analysis. *Surg Neurol* 1984;22:335-340
42. Ostergaard JR. Association of intracranial aneurysm and arteriovenous malformation in childhood. *Neurosurgery* 1984;14:358-62
43. Perret G, Nishoka H. Report of the cooperative study of intracranial aneurysm and subarachnoid hemorrhage. VI. Arteriovenous malformation: an analysis of 5435 cases of crani-cerebral arteriovenous malformations and fistulae reported to the cooperative study. *J Neurosurg* 1966;25:467-490
44. Reigh EE, Lemmen LJ. Cerebral aneurysms and other intracranial pathology. *J Neurosurg* 1960;17:469-476
45. Sekhar LN, Heros RC. Origin, growth, and rupture of saccular aneurysms: a review. *Neurosurgery* 1981;8:248-260
46. Shenkin HA, Jenkins F, Kim K. Arteriovenous anomaly of the brain associated with cerebral aneurysm: case report. *J Neurosurg* 1971;34:225-228
47. Suzuki J, Onuma T. Intracranial aneurysms associated with arteriovenous malformations. *J Neurosurg* 1979;50:742-746
48. Voigt K, Beck U, Reinshagen G. A complex cerebral vascular malformation studied by angiography: multiple aneurysms angiomas and arterial ectasia. *Neuroradiology* 1973;5:117-123
49. Waga S, Itoh H, Kojima T. Posterior inferior cerebellar artery aneurysm associated with arteriovenous malformation fed by the same artery. *Surg Neurol* 1985;23:617-620
50. Yasargil MG. *Microsurgery*. Vol IIIa. New York: Thieme, 1984: 182-189
51. Doppman JL, Di Chiro G, Glaucy DL. Collateral circulation through dilated spinal cord arteries in aortic coarctation and extraspinal arteriovenous shunts: an arteriographic study. *Clin Radiol* 1969;20:192-197
52. Marks PM, Lane B, Steinberg GK, Chang PJ. Hemorrhage in intracerebral arteriovenous malformations: angiographic determinants. *Radiology* 1990;176:807-813
53. Biondi A, Merland JJ, Reizine D, et al. Embolization with particles in thoracic intramedullary arteriovenous malformation: long term angiographic and clinical results. *Radiology* 1990;177:651-658
54. Brown RD Jr, Wiebers DO, Forbes GS. Ruptured intracranial aneurysms and arteriovenous malformations: frequency of intracranial hemorrhage and relationship of lesions. *J Neurosurg* 1990;73: 859-863