



Get Clarity On Generics

Cost-Effective CT & MRI Contrast Agents

**FRESENIUS
KABI**

WATCH VIDEO

AJNR

Abnormalities of the septum pellucidum on MR scans in first-episode schizophrenic patients.

G Degreef, G Lantos, B Bogerts, M Ashtari and J Lieberman

AJNR Am J Neuroradiol 1992, 13 (3) 835-840

<http://www.ajnr.org/content/13/3/835>

This information is current as
of August 20, 2025.

Abnormalities of the Septum Pellucidum on MR Scans in First-Episode Schizophrenic Patients

Gustav Degreef,¹ George Lantos,^{2,3,5} Bernhard Bogerts,⁴ Manzar Ashtari,² and Jeffrey Lieberman¹

Purpose: and Methods: Cavities in the septum pellucidum have been widely regarded in clinical neurology or in autopsy series as incidental findings of little clinical importance; however, an association between this developmental anomaly and a diagnosis of psychosis has been reported. We compared MR brain scans of schizophrenic patients with normal control subjects to determine the prevalence of this finding in the two groups. **Results:** A cavum septum pellucidum was found in 14 of 62 (23%) schizophrenic patients and only one of 46 control subjects (2%). Pronounced enlargement of the cavum septum and a cavum vergae were seen only in two schizophrenic subjects. A partial agenesis of the corpus callosum was also seen in one of the schizophrenic cases with the largest cavum septum pellucidum. **Conclusions:** The increased prevalence of a cavum septum pellucidum, the cavum vergae, and partial callosal agenesis in schizophrenics support the hypothesis that anomalous development of the brain is an important aspect of this disorder. The disturbed structures are closely linked developmentally to the limbic system which has been implicated etiologically in studies of schizophrenia.

Index terms: Septum pellucidum; Schizophrenia; Brain, magnetic resonance

AJNR 13:835–840, May/June 1992

The contention that noncommunicating cavum septi are associated with neuropsychiatric disturbances has been a subject of much debate (1). Recently an association with this developmental anomaly and atypical psychoses has again been described (1).

This study was undertaken to determine if there was an increased prevalence of the cavum septum pellucidum (CaSep) in a group of schizophrenic patients compared to normal controls. The use of high-resolution MR imaging offers the opportunity to obtain excellent images in vivo. Unlike the obsolete pneumoencephalography (PnEG), magnetic resonance (MR) is noninvasive and offers advantages over computed tomography (CT) in that it utilizes no ionizing radiation, has multiplanar capabilities, and affords superior soft-tissue contrast.

Methods

MR scans of 62 schizophrenic patients were selected from a research protocol being conducted at this hospital. The 62 patients had entered the hospital in their first episode of schizophrenia before they received neuroleptic treatment. Diagnoses were determined by Research Diagnostic Criteria (RDC) (2) based on information from a structured diagnostic interview (SADS) (3) and confirmed by 1–3 years follow-up reevaluations. The diagnoses were consistent with existing clinical criteria (4).

Forty-six control subjects were recruited from medical center staff and the community through advertisements. All subjects gave written informed consent to have MR

Received June 4, 1991; accepted and revisions requested July 22; revisions received August 13.

This work was supported in part by USPHS Grants #MH00537, MH41646, MH41960, an APA Kempf Fund Award (G. Degreef), and a grant from Helen and Irving Schneider and Family.

¹ Department of Psychiatry, Hillside Hospital Division of the Long Island Jewish Medical Center, the Long Island Campus of the Albert Einstein College of Medicine, Glen Oaks, NY 11004.

² Department of Radiology, Long Island Jewish Medical Center, the Long Island Campus for the Albert Einstein College of Medicine, New Hyde Park, NY 11042.

³ Department of Neurology, Long Island Jewish Medical Center, the Long Island Campus for the Albert Einstein College of Medicine, New Hyde Park, NY 11042.

⁴ Department of Psychiatry, University of Düsseldorf, Bergische Landstrasse 2, Postfach 12 05 10, D400 Düsseldorf 12, Germany.

⁵ Address reprint requests to George Lantos, MD, Magnetic Resonance Imaging Center, Long Island Jewish Medical Center, New Hyde Park, NY 11042.

AJNR 13:835–840, May/June 1992 0195-6108/92/1303-0835

© American Society of Neuroradiology

scans. Patients and controls were screened for medical and psychiatric illness and history of substance abuse. None of the patients or controls had a history of substance dependence or current abuse, or history of chronic neurologic or medical illnesses or drug treatment (eg, corticosteroids) known to affect the brain. No schizophrenic cases demonstrated signs of raised intracranial pressure or gross neurologic deficits. Control and schizophrenic subjects had approximately the same age and race distribution. The demographic characteristics are shown in Table 1. Education was ranked according to the Hollingshead-Redlich Classification (5). Four patients exhibited gross changes in their MR scans not typically associated with schizophrenia (eg, evidence of infarction). These four subjects were dropped from the study and were not included in this sample. No patient or control subject had clinical or MR evidence of significant prior head trauma, such as extracerebral hematomas, post-traumatic encephalomalacia, or white matter shear injuries.

Subjects were scanned in a 1.0-T whole-body MR system (Magnetom, Siemens Medical Systems, Iselin, NJ) using a dedicated head coil. Brain images were acquired in the coronal and sagittal plane using a 50° angle nonselective gradient-echo (fast low-angle shot, FLASH) sequence with the parameters 40/15/1 (TR/TE/excitations). This sequence provided 63 contiguous slices of 3.1-mm thickness in 11 minutes. A standard T2-weighted sequence was used to acquire axial images with parameters 2500/25,90/1. The axial sequence obtains 16–20 parallel sections which are 7-mm thick with 2.1-mm gaps between sections. Images were displayed in a 256 × 256 matrix with no zoom factor and with an in-plane resolution of 1 mm × 1 mm. Video film hard copies were printed for visual qualitative evaluation. MR scans of all patient and control subjects were combined in random order and reviewed by a neuroradiologist (author G.L.) and psychiatrist trained in neuroanatomy (author B.B.). Each rating was assigned on the basis of a consensus between the two raters. The raters were blinded as to the clinical status of the subjects.

The presence of a CaSep was assigned via visual inspection and graded on a scale of 0 to 4: 0 represented absent, 1 questionable, 2 small, 3 moderate, and 4 large. The appearance of the grade 0, 1, 2, 3, and 4 CaSep and cavum vergae (CaVr) are illustrated in Figures 1 and 2.

TABLE 1: Demographic characteristics of schizophrenic and control subjects

	Control	First-Episode Schizophrenic
Sex		
Male/female	22/24	33/29
Age		
Mean (SD)	28.8 (7.5)	24.1 (5.8)
Education ^a	2.0 (0.9)	3.4 (1.1)
Duration of illness		
Years \bar{x} (SD)		1.02 (1.7)

^a 2 = college graduate, 3 = partial college, 4 = high school graduate.

Results

The summary of ratings of the CaSep from MR scans for the three groups are shown in Table 2. For the initial analysis subjects who had a grade of 0 or 1 were combined and rated as not having a CaSep. This was done since grade 1 cava were extremely small and probably represented the limits of ability of our high-resolution system to resolve the two leaves of the septum pellucidum. One subject had a grade 3 and one a grade 4 CaSep and both were first-episode schizophrenic patients.

A CaSep was found in 14 of the first-episode patients (23%), and only one of the 46 control subjects (2.2%). Statistical comparisons were performed using χ^2 analyses or Fisher's exact tests when expected cell sizes were less than five. Compared to the control group, the frequency of CaSep was significantly higher in the first-episode patients (Fishers Exact Test, two-tailed, $P < .003$) than in the control group. Including grade 1 cava in the analyses also revealed significant differences between first-episode schizophrenics and controls ($\chi^2 = 5.52$, $df = 1$, $P < .02$). No significant correlation between CaSep status and age was found in controls or schizophrenic subjects. Significant differences were found neither in age between schizophrenic patients with (mean, 25.4 years) and without (mean, 23.9 years) a CaSep, nor in gender rates. Fourteen schizophrenics (seven male and seven female) had a grade 2–4 CaSep and only one male control had a grade 2 CaSep. Twenty-two schizophrenic patients (14 male and eight female) had a CaSep grade 1 to 4 compared to seven controls (three male and four female) with grade 1 to 2 ($\chi^2 = 0.95$, $df = 1$, $P < 0.33$). There was no history of significant head trauma in any patients with a CaSep, nor did there appear to be any cases with a break in the septal laminae that would indicate a traumatic etiology.

Only two subjects had a CaSep: a female schizophrenic patient who had a grade 4 CaSep and the male schizophrenic with a grade 3 CaSep. In the schizophrenic patient with a grade 3 CaSep, an additional finding was the presence of a partial agenesis of the posterior portion of the corpus callosum (Fig. 3). No other schizophrenic or control subject demonstrated a similar abnormality of the corpus callosum or any other major brain malformation.

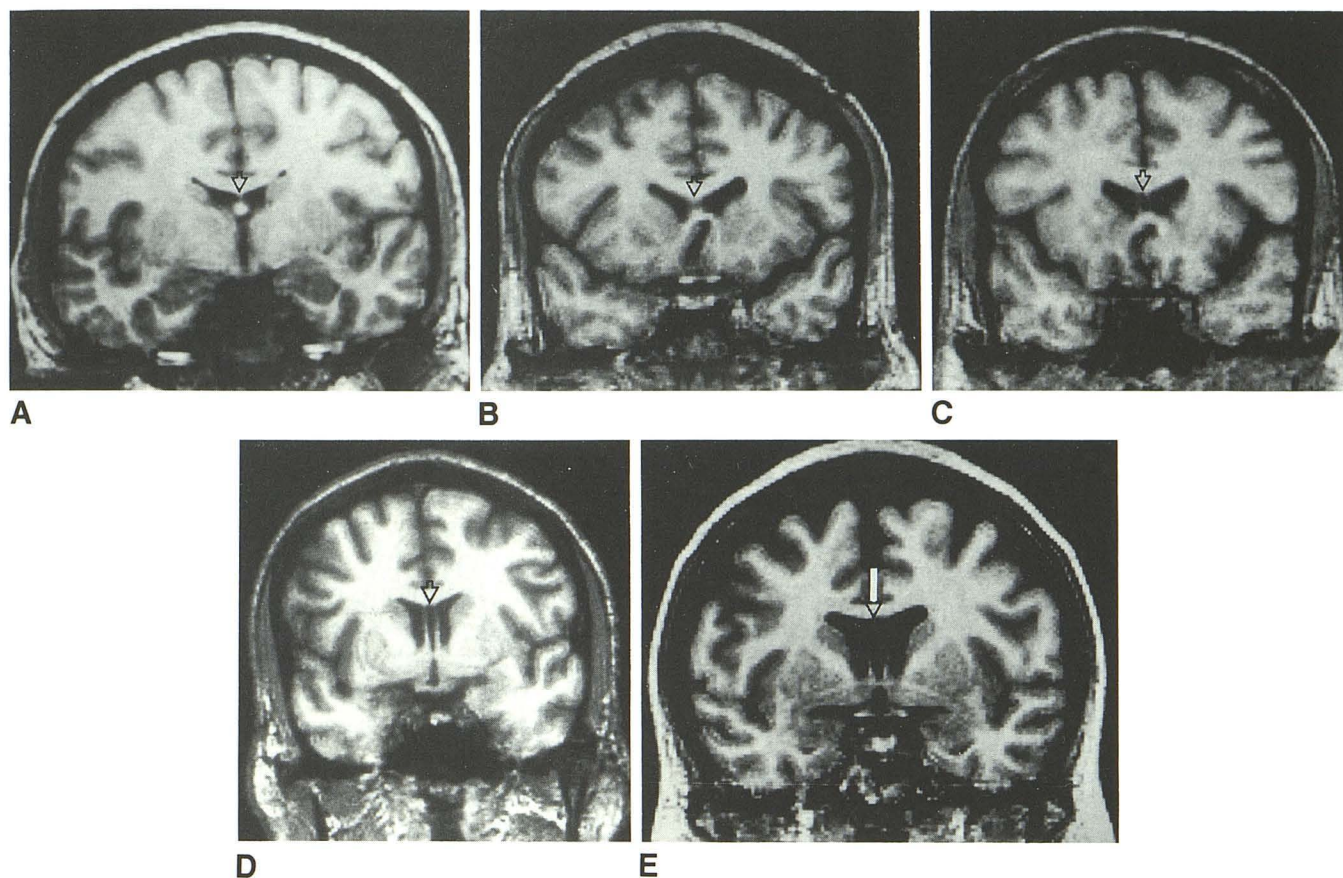


Fig. 1. Appearance of the cavum septum pellucidum on coronal MR scans (FLASH sequence 40/15/1 (TR/TE/excitations) with 50° flipangle). It appears as a midline cerebrospinal fluid containing space separated from the frontal horns by thin, parallel septa. A, B, C, D, and E, respectively, represent the normal, grade 1, 2, 3, and 4 cavum (*open arrowheads*). All scans are from schizophrenic patients: A, 26-year-old woman; B, 27-year-old man; C, 21-year-old man; D, 28-year-old man; E, 38-year-old woman.

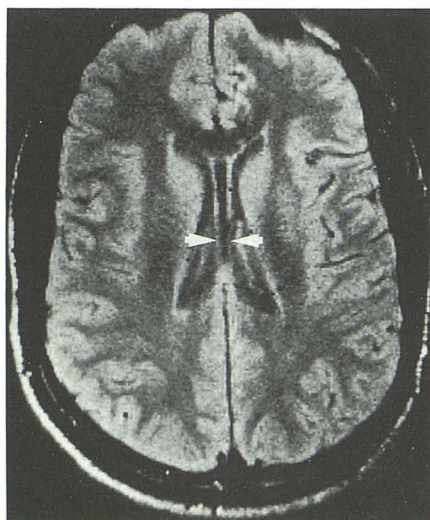


Fig. 2. The cavum vergae on axial T2-weighted MR scan (spin-echo pulse sequence 2500/25/1). Twenty-one-year old male schizophrenic patient with a grade 3 cavum extending posteriorly into the cavum vergae (*arrowheads*).

Discussion

The septum pellucidum is a thin triangular membrane consisting of two glial layers and fiber tracts which separate the frontal horns of the lateral ventricles (6, 7) and is bounded by the corpus callosum anterosuperiorly and the body of the fornix posteriorly. It consists of two thin laminae with a potential space (or cavum) between them. Two types of CaSep have been described: communicating and noncommunicating. A communicating CaSep is accompanied by a tear in the septal laminae through which its interior communicates with the ventricular system. Communicating CaSeps are usually associated with other neuropathologic abnormalities and are often found in boxers with traumatic encephalopathy (8, 9). A noncommunicating CaSep is a closed space and appears to be a developmental anomaly (7, 10). The portion of the CaSep lying posterior to an arbitrary vertical plane through the columns of the fornix is termed

Fig. 3. Partial agenesis of the corpus callosum (FLASH sequence 40/15/1 with 50° flipangle).

A, Midsagittal section in a 21-year-old male schizophrenic patient showing partial agenesis of the posterior portion of the corpus callosum (*arrow*).

B, Coronal section at the level of the pulvinar nucleus in the same patient, showing cingulate gyrus but no corpus callosum (*open arrows*).

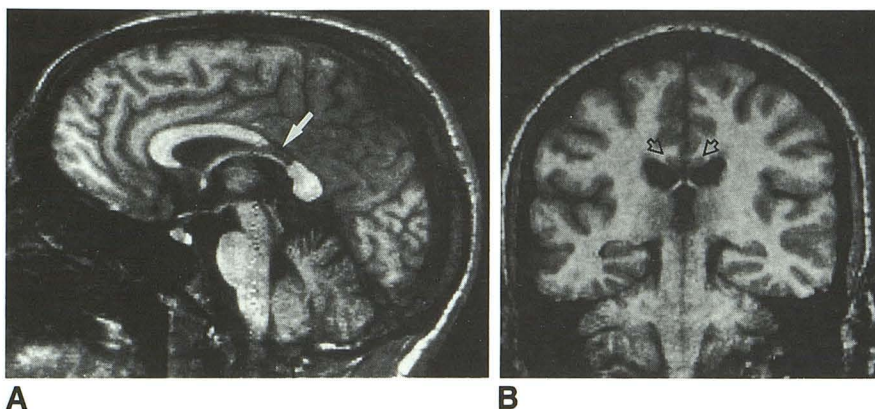


TABLE 2: Prevalence of the cavum septum pellucidum in schizophrenic and control subjects

	Control	First-Episode Schizophrenia
Grade	46	62
0	39	40
I	6	8
II	1	12
III	0	1
IV	0	1
I-IV	7	22
II-IV	1	14

the cavum vergae (CaVr). The CaSep and CaVr, if both are present, are essentially the same structure and usually communicate freely. At times they may be completely separated by the columns of the fornix or by a bridge of cerebral tissue (10). These two cavities are not part of the true ventricular system (11) although they are lined with ependyma (7, 12). In most, if not all, fetuses the two layers of the septum pellucidum are separated by a cavity of varying size (10, 13) that begins to disappear before birth but is seen in about 80% of infants at term (14). The CaSep usually shrinks to a vanishingly small slit long before adulthood (10) but persists and can be seen in a small percentage of adults (10, 15). The CaVr begins to contract posteriorly after about 6 gestational months and is absent at term in 70% of infants (14). The CaSep and CaVr vary greatly in size and there is considerable disagreement in the literature concerning their prevalence in normals (7, 10, 13, 16).

This study reports a significantly higher prevalence of CaSep in schizophrenic patients when compared to normal control subjects. We believe that, in earlier studies, the rate of detection of this structural abnormality was lower because the imaging techniques employed were less sensitive and more likely to cause partial volume effects (17). Prior CT studies acquired images with 8- to

10-mm slice thickness. In contrast, our MR technique acquires slices of 3.1-mm thickness. CaSeps smaller than 3 mm have been described in autopsy studies (9), and Shaw and Alvord (10) have noted that in the case of small cavities any postmortem technique short of thin coronal sections through precisely the right part of the septum may miss their presence entirely. It is also possible that the presence of CaSeps in schizophrenic patients has been overlooked because all previous CT studies in schizophrenic samples have been performed using the axial projection. Alternatively, the increased occurrence of CaSep in schizophrenic samples may have been overlooked in previous CT or MR studies because it was not the focus of attention.

The prevalence of a CaSep in our normal controls (using conservative criteria) was 2.2%, a figure that is similar to estimates in samples examined by means of PnEG and CT (1, 7, 15, 18). PnEG studies of mixed samples yield prevalence figures between 2% and 4% (7, 19, 20). The prevalence of such cava on CT in a mixed sample of 22,000 subjects was found to be 0.15% (1). Postmortem studies have yielded rates of 2%–30% in adults (7, 9, 10, 21). Differences in technique and the population selected are believed to be the factors most likely to be responsible for the variations in rates between postmortem studies (22).

Although postmortem studies may have higher resolution than both CT and PnEG and, therefore, might afford the detection of the very small CaSep, the tendency to include psychiatric subjects and subjects with neurologic disorders as "normals" in postmortem studies limits the value of such a comparison. The inclusion of patients who died in a psychiatric hospital (475/500 subjects) and subjects with neuropathologic evidence of head injury may account for the 28.4% rate noted by Corsellis et al (9). Schwidde (21) re-

ported a prevalence of CaSep of 20.3%, but his study included premature infants and subjects under age 10. It is actually unclear what types of subjects comprised Schwidde's (21) sample, since no mention is made whether subjects with gross developmental abnormalities or neurologic disorders were excluded.

When we used less stringent criteria (including grade 1 cava) the 15.2% rate in our controls is comparable, though somewhat lower, than a number of postmortem studies. The 15.2% rate in the controls using these liberal criteria is, however, still significantly lower than the 35% rate in our schizophrenic patients.

A cyst of the septum pellucidum is a type of noncommunicating CaSep which is a rare anatomic entity that occasionally acts as a mass and can present with neuropsychiatric symptoms. Case reports and series of cavum cysts have been described (18, 23–26). The CaSep is a different anatomic entity and rarely (if ever) expands (10, 25, 27). The degree of overlap between these two conditions is not entirely clear, but there is evidence that cystic cava may have a different embryologic derivation than CaSeps (25). A CaSep can easily be seen on coronal CT (and, from our experience, MR) scans, and the differential diagnosis from other fluid-filled midline cysts, cysts of the third ventricle, or from a cavum velum interpositum can easily be established (7, 23, 28). The cavum velum interpositum is a part of the subarachnoid space that lies above and posterior to the third ventricle and communicates posteroinferiorly with the cisterna corpora quadrigemina.

In clinical neurology, it is generally believed that CaSeps have little, if any, clinical significance (29). However, a relationship between a relatively wide cavum and a diagnosis of epilepsy or mental disorder has been alternately claimed and disputed. The increased prevalence of the CaSep and CaVr however, may indicate an arrest of normal maturation within a region of the brain with critical responsibilities for the integration of sensory and motor functions (30–32). One hypothesis of the pathogenesis of schizophrenia is that it is a developmental disorder that may be related to maldevelopment of limbic system structures (30).

The septum pellucidum blends into the septum verum (true septum) (6) which consists of a series of subcortical nuclei with rich interconnections to the hippocampus. The septum has thus been described as a nodal point or central relay station

in the limbic system (7). It is now clear that, by virtue of its inputs from most areas of the neocortex, amygdala, and brain stem, and its projections to cingulate cortex, hypothalamus, midbrain reticular formation, striatum, substantia nigra, and (via the pontine gray matter) cerebellum, this system can influence activity in most of the major neural circuits of the brain (31, 32).

It still remains to be shown, however, that the presence of a CaSep in any way implies the existence of dysfunction of the septohippocampal system. Nonetheless, the presence of a cavum suggests that efferent and afferent pathways to the septum verum may be disrupted. Since septal nuclei have extensive bidirectional projections to other limbic structures, factors leading to the development of a CaSep may also have affected these limbic structures and may in turn be closely related to the development of schizophrenia.

Rakic and Yakovlev (11) have clearly demonstrated that the development of the septum pellucidum and corpus callosum are intimately linked. The corpus callosum, the anterior commissure, and the hippocampal commissure, as well as the septum pellucidum, are integral parts of the commissural plate (11). A lesion in the commissural plate of the developing fetus may, therefore, influence the development of all these structures (33). The presence of a partial agenesis of the corpus callosum in one of the schizophrenic subjects with a large CaSep is consistent with these observations. In addition, abnormalities of the corpus callosum have been previously noted in schizophrenia (34, 35).

The presence of partial callosal agenesis and CaVr are further indications that alterations of normal developmental processes play a significant role in schizophrenia. If a CaSep results from an arrest of prenatal or postnatal development, then this might be reflected by psychological and behavioral problems dating to early infancy. In fact, delays in motor milestones as well as childhood emotional and conduct disorders have been noted in the histories of schizophrenic subjects (36). Neurologic abnormalities and behavioral differences have also been recently noted in home movies of the early infancy period of subjects who later developed schizophrenia (37).

In related investigations, several groups have reported that the septum pellucidum is either elongated (38, 39) or larger in area (40) in schizophrenic patients compared to control subjects. The relationship, if any, to CaSep was not reported.

In conclusion, it is suggested that CaSep may signify the presence of an underlying functional abnormality that is related to the pathogenesis of schizophrenia. We plan to investigate whether there are clinical correlates of this developmental anomaly and to examine the relationship of the CaSep to other subtle brain abnormalities that have been noted in schizophrenia.

Acknowledgment

We would like to thank Jeanine Springer for help with compilation and editing of the manuscript.

References

- Lewis SW, Mezey CG. Clinical correlates of septum pellucidum cavities: an unusual association with psychosis. *Psychol Med* 1985; 15:43–54
- Spitzer RL, Endicott J, Robins E. *Research criteria (RDC) for a selected group of functional disorders*. New York: Biometrics Research Division, New York State Psychiatric Institute, 1977:7–14
- Spitzer RL, Endicott J. *Schedule for affective disorders and schizophrenia (SADS)*. 3rd ed. New York: New York State Psychiatric Institute, 1977:1–78
- American Psychiatric Association. *Diagnostic and statistical manual of mental disorders: DSM III-R*. 3rd ed, revised. Washington, DC: American Psychiatric Press, 1988:187–198
- Hollingshead RB. *Two-factor index of social position*. New Haven, CT: Yale Station, 1965
- Andy OJ, Stephan H. The septum in the human brain. *J Comp Neurol* 1968;133:383–410
- Bruyn GW. Agenesis septi pellucidi, cavum septi pellucidi, CV and cavum veli interpositi. In: Vinken PJ, Bruyn GW, eds. *Handbook of clinical neurology*. Amsterdam: Elsevier/North Holland, 1977: 299–336
- Spillane JD. Five boxers. *Br Med J* 1962;2:1205–1210
- Corsellis JAN, Bruton CJ, Freeman-Browne D. The aftermath of boxing. *Psychol Med* 1973;3:270–303
- Shaw CM, Alvord EC. Cava septi pellucidi et Vergae: their normal and pathological states. *Brain* 1969;92:213–224
- Rakic P, Yakovlev PI. Development of the corpus callosum and cavum septi in man. *J Comp Neurol* 1968;132:45–72
- Liss L, Mervis L. The ependymal lining of the cavum septi pellucidi: a histological and histochemical study. *J Neuropathol Exp Neurol* 1984;23:355–367
- Laroche JC, Baudey J. Cavum septi lucidi, CV, cavum veli interpositi: cavités de la ligne médiane. Étude anatomique et pneumoencéphalographique dans la période néo-natale. *Biol Neonat* 1961;3:193–236
- Williams AL, Haughton VM. Congenital anomalies. In: *Cranial computed tomography: a comprehensive text*. St. Louis: Mosby, 1985: 316–349
- Nakano S, Hojo H, Kataoka K, Yamasaki S. Age related incidence of cavum septi pellucidi and CV on CT scans of pediatric patients. *J Comput Assist Tomogr* 1981;5:348–349
- Hughes RA, Kernohan JW, Craig WM. Caves and cysts of the septum pellucidum. *Arch Neurol Psychiatry* 1955;74:259–266
- de Groot J. *Correlative neuroanatomy of computed tomography and magnetic resonance imaging*. Philadelphia: Lea & Febiger, 1984
- Harwood-Nash DC. Congenital craniocerebral abnormalities. *Semin Roentgenol* 1977;12:39–51
- Bonitz G. Zur klinische-diagnostischen bedeutung des erweiterten und kommunizierenden cavum septi pellucidi. *Nervenarzt* 1969;40: 121–128
- Sonntag I, Nadjmi M, Lajosi F, Fuchs G. Anlagebedingte Gehirnanomalien der Mittellinie. *Nervenarzt* 1971;42:531–539
- Schwidde JT. Incidence of cavum septi pellucidi and cavum vergae in 1302 human brains. *Arch Neurol Psychiatry* 1952;67:625–632
- Swenson O. Nature and occurrence of the cavum septi pellucidi. *Arch Pathol* 1944;37:119–123
- Neciega EG, Peralta AG, Polaina M, Sureda B, Bautista J. Cyst of the septum pellucidum and Korsakoff's Psychosis. *Eur Neurol* 1989;29: 99–101
- Dandy WE. Congenital cerebral cysts of the cavum septi pellucidi (fifth ventricle) and cavum vergae (sixth ventricle): diagnosis and treatment. *Arch Neurol Psychiatry* 1931;25:44–66
- Ciric I, Zivin I. Neuroepithelial (colloid) cysts of the septum pellucidum. *J Neurosurg* 1975;43:69–73
- Cowley AR, Moody DM, Alexander E Jr, Ball MR, Lester DW. Distinctive CT appearance of cyst of the cavum septi pellucidi. *AJR* 1979;133:548–550
- Friede RL. *Developmental neuropathology*, 2nd ed. New York: Springer-Verlag, 1988:287–329
- Zellweger H, Van Epps EF. The cavum veli interpositi and its differentiation from cavum vergae. *AJR* 1959;82:793
- Ulrich H. Malformations of the nervous system, perinatal damage and related conditions in early life. In: Blackwood W, Corsellis JAN, eds. *Greenfields neuropathology*. London: Edward Arnold, 1976: 361–470
- Bogerts B. The neuropathology of schizophrenia: pathophysiological and neurodevelopmental implications. In: Mednick SA, Cannon TD, Barr CE, eds. *Fetal neural development and adult schizophrenia*. Cambridge, England: Cambridge University Press, 1990:153–173
- Swanson LW. The anatomical organization of septohippocampal projections. *Ciba Found Symp* 1978;58:25–43
- Swanson LW. The hippocampus and the concept of limbic system. In: Seifert W, ed. *Neurobiology of the hippocampus*. London: Academic Press, 1983:3–19
- Marburg O. So-called agenesis of the corpus callosum (callosal defect). *Arch Neurol Psychiatry* 1949;61:297–312
- Swayze VW, Andreasen NC, Erhardt JC, Yuh WTC, Alliger RJ, Cohen GA. Developmental abnormalities of the corpus callosum in schizophrenia. *Arch Neurol* 1990;47:805–808
- Coger RW, Serafinides EA. Schizophrenia, corpus callosum, and interhemispheric communication: a review. *Psychiatry Res* 1990;34: 163–184
- Fish B. Neurologic antecedents of schizophrenia in children: evidence for an inherited, congenital neurointegrative deficit. *Arch Gen Psychiatry* 1977;34:1297–1313
- Walker E, Lewine RJ. Prediction of adult-onset schizophrenia from childhood movies of the patients. *Am J Psychiatry* 1990;147: 1052–1056
- Johnstone EC, Owens DGC, Bydder GM, Colter N, Crow TJ, Frith CD. The spectrum of structural brain changes in schizophrenia: age of onset as a predictor of cognitive and clinical impairments and their cerebral correlates. *Psychol Med* 1989;19:91–103
- Mathew RJ, Partain CL, Prakash R, Kulkarni MV, Logan TP, Wilson WH. A study of the septum pellucidum and corpus callosum in schizophrenia with MR imaging. *Acta Psychiatr Scand* 1985;72: 414–421
- Uematsu M, Kaiya H. Midsagittal cortical pathomorphology of schizophrenia: a magnetic resonance imaging study. *Psychiatry Res* 1989; 30:11–20