



## Get Clarity On Generics

Cost-Effective CT & MRI Contrast Agents



FRESENIUS  
KABI

WATCH VIDEO

# AJNR

### **Brown tumor of the facial bones.**

R Gelman and F E Gellad

*AJNR Am J Neuroradiol* 1991, 12 (6) 1179-1181

<http://www.ajnr.org/content/12/6/1179.citation>

This information is current as  
of August 31, 2025.

# Brown Tumor of the Facial Bones

Russell Gelman<sup>1</sup> and Fouad E. Gellad

Brown tumors are expansile osteolytic lesions of bone, occurring in hyperparathyroidism. They occur more commonly in primary hyperparathyroidism, and tend to regress after the removal of parathyroid adenomas [1]. They are much less common in secondary hyperparathyroidism but have been reported [1]. Brown tumors occur most commonly in ribs, mandible, clavicle, and pelvis, and are uncommon in the facial bones [2, 3]. We report two cases, one of primary hyperparathyroidism and one of secondary hyperparathyroidism involving the paranasal sinuses.

## Case Reports

### Case 1

A 37-year-old woman had a 9-year history of chronic renal failure on dialysis. She presented with a nasal mass of approximately 6 months duration. Examination revealed a firm mass pushing the right nasal bones outward as well as a mass obstructing the right nasal fossa. Paranasal sinus radiographs revealed a large soft-tissue mass in the region of the right ethmoidal sinus with bone erosion of the medial orbital wall. Partial opacification of the right frontal and maxillary sinuses was present. A CT scan showed a mass arising in the right ethmoidal sinus causing destruction and expansion medially toward the nasal septum, inferiorly into the maxillary sinus, and laterally to involve the medial orbital wall. Scattered flecks of calcification were present within the soft-tissue component (Fig. 1).

Surgery revealed a hard, almost bonelike tissue obliterating and occupying the entire right ethmoidal sinus and involving the maxillary sinus. The nasal septum was not involved. The sphenoidal and frontal sinuses were clear of disease. The tumor was completely removed, as were the medial portion of the infraorbital rim, the nasal bone on the right, the entire ethmoidal sinus, and the medial maxilla. Histologic diagnosis of the specimen was Brown tumor.

### Case 2

A 39-year-old woman with sickle cell disease presented with a slowly enlarging left maxillary mass of 2 years duration. She also had symptoms of fatigue, decreased energy, occasional nausea and vomiting, nocturia and polyuria, constipation, and diffuse bone pain, especially in the hip and knee joints. A 3 × 4 cm firm, nontender

prominence was palpated in the left maxilla. A 2 × 2 cm firm nontender mass was felt in the inferior pole of the thyroid on the right side.

Plain radiographs of the face revealed an expansile mass occupying the majority of the left maxillary antrum causing destruction of the lateral maxillary wall. Diffuse osteopenia of the skull and other bones was present. Subperiosteal resorption of the radial side cortex of the fingers was present, especially in both index fingers. Early acroosteolysis was also present. A CT scan revealed an expansile aggressive process arising from the inferior wall of the maxillary antrum with bone and soft-tissue components (Fig. 2). A dynamic CT after a bolus injection of IV contrast medium showed the lesion to be moderately hypervascular. Results of needle and incisional biopsies of the maxillary lesion showed bone marrow fibrosis and multinucleated giant cell infiltration consistent with Brown tumor or reparative giant cell granuloma.

A right parathyroid adenoma was diagnosed and a partial parathyroidectomy was performed. The patient is being followed on an outpatient basis, as maxillary lesions tend to go into remittance after the adenoma is removed.

## Discussion

Brown tumors of the facial skeleton are rare. They are classically associated with primary hyperparathyroidism, but are being described with increasing frequency in secondary hyperparathyroidism as the life expectancy of patients on hemodialysis for chronic renal failure has increased [1, 2]. Previous reports have documented the presence of Brown tumors in the maxillary sinus, sphenoid sinus, orbits, temporal bones, and palate [1–8].

Brown tumors typically cause bone expansion rather than bone destruction, as they are the products of a benign, slow-growing process. Brown tumors are due to the direct effect of parathyroid hormone on bone. In primary hyperparathyroidism, a parathyroid adenoma is the cause in 81%, while other causes include hyperplasia (15%) and carcinoma (4%) [5]. In chronic renal failure, it is presumed that phosphate retention stimulates parathyroid hormone secretion [2]. Parathyroid hormone causes the conversion of potentially osteogenic cells from osteoblasts to osteoclasts. Increased osteolytic and

Received February 21, 1991; revision requested April 21, 1991; revision received May 21, 1991; accepted June 4, 1991.

<sup>1</sup> Both authors: Department of Radiology, University of Maryland Medical System, 22 S. Greene St., Baltimore, MD 21201. Address reprint requests to R. Gelman.



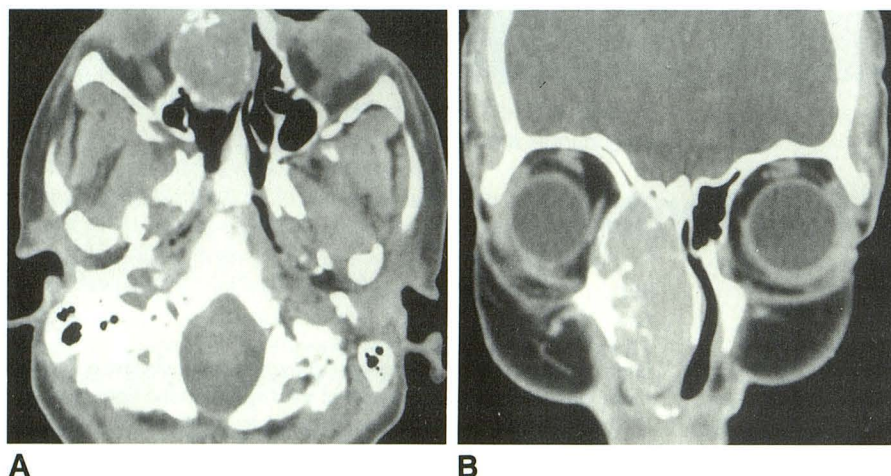


Fig. 1.—Case 1: 37-year-old woman with right ethmoidal Brown tumor.

A and B, Axial (A) and coronal (B) CT scans show destruction of right ethmoidal sinus with medial, inferior, and anterior extension. Scattered areas of calcification or bone fragments are present within soft-tissue mass.

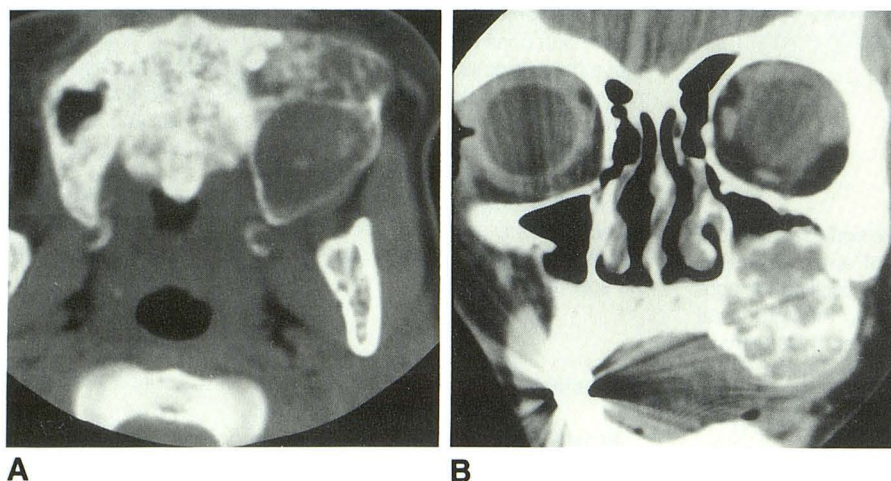


Fig. 2.—Case 2: 39-year-old woman with sickle cell disease and left maxillary Brown tumor.

A and B, Axial (A) and coronal (B) CT scans show mass arising from floor of left maxillary antrum with expansion and destruction of the antrum. Areas of calcification or bone fragments are present within soft-tissue mass.

osteoclastic activity occurs with depression of osteoblastic activity [6]. Osteoid is formed but with poor bony trabecular formation. Cysts may develop as a result of bleeding and tissue degeneration. The hemorrhagic stroma gives the mass the characteristic brown color observed surgically and histologically. Histologic studies of these lesions demonstrate osteoclastic giant cells, fibroblasts, and lipid-laden macrophages in a dense stroma with hemorrhage and hemosiderin [2, 6].

Bone lesions of the facial skeleton containing giant cells include Brown tumor, giant cell reparative granuloma, true giant cell tumor, aneurysmal bone cyst, and cherubism. These lesions often cannot be distinguished radiologically or histologically [1, 9]. The giant cell reparative granuloma probably represents a reparative reaction to a traumatic injury, although a history of trauma is not always obtained. Cherubism, an autosomal dominant disorder occurs in childhood and involves both mandibular rami and occasionally the maxilla. True giant cell tumors and aneurysmal bone cysts are identical to the

typical lesions seen elsewhere in the body, but are rare in the facial bones [1, 9].

Clinical and biochemical differences are important in differentiating these entities [2]. Calcium, phosphorus, parathyroid hormone, and alkaline phosphatase levels are important. Hypercalcemia, hypophosphatemia, and hypercalciuria are the characteristic changes in hyperparathyroidism, together with increased alkaline phosphatase and parathyroid hormone [2]. The presence of abnormal plasma calcium suggests the presence of an abnormal parathyroid hormone level, and further investigation of the parathyroid gland is indicated [5]. However, the absence of hypercalcemia does not rule out hyperparathyroidism [9].

The radiologic appearance of these lesions may be mimicked by salivary gland tumors, plasmacytomas, melanoma, lymphoma, and sarcoma [1]. Sinus carcinoma can also look very similar [10]. For this reason, the diagnosis of Brown tumor is often delayed [2].

Treatment of the underlying hyperparathyroidism and control of the hypercalcemia will usually result in gradual healing of the giant cell lesions [11], but the lesion may continue to expand [2, 10]. Surgical intervention may be needed for its complete elimination.

#### REFERENCES

1. Som PM, Lawson W, Cohen BA. Giant cell lesions of the facial skeleton. *Radiology* **1983**;147:129-134
2. Schweitzer VG, Thompson NW, McClatchey KD. Sphenoid sinus Brown tumor, hypercalcemia and blindness: an unusual presentation of primary hyperparathyroidism. *Head Neck Surg* **1986**;8:379-386
3. Rao P, Solomon M, Avramides A, Saxena A, Delano BG, Gold BM, Berger J. Brown tumors associated with secondary hyperparathyroidism of chronic renal failure. *J Oral Surg* **1978**;36:154-159
4. Robinson PJ, Woodhead P. Primary hyperparathyroidism presenting with a maxillary tumour and hydrocephalus. *J Laryngol Otol* **1988**;102:1164-1167
5. Shanmugham MS, Alhady SF. Hyperparathyroidism with osteitis fibrosa cystica in the maxilla. *J Laryngol Otol* **1984**;98:417-420
6. Rosen IB, Palmer JA. Fibroosseous tumors of the facial skeleton in association with primary hyperparathyroidism. *Am J Surg* **1981**;142:494-498
7. DePablos PL, Ramos I, De La Colle H. Brown tumor in the palate associated with primary hyperparathyroidism. *J Oral Maxillofac Surg* **1987**;45:719-720
8. Friedman WH, Pervez N, Schwartz AE. Brown tumor of the maxilla in secondary hyperparathyroidism. *Arch Otolaryngol* **1974**;100:157-159
9. Smith PG, Marrogi AJ, Delfino JJ. Multifocal central giant cell lesions of the maxillofacial skeleton. *J Oral Maxillofac Surg* **1990**;48:300-305
10. Silver JA, Baredas S, Bello JA, Blitzler A, Hilal SK. The opacified maxillary sinus: CT findings in chronic sinusitis and malignant tumors. *Radiology* **1987**;163:205-210
11. Smith GA, Ward PH. Giant cell lesions of the facial skeleton. *Arch Otolaryngol* **1978**;104:186-190