



## Discover Generics

Cost-Effective CT & MRI Contrast Agents



[VIEW CATALOG](#)

# AJNR

### **Venous infarction of the spinal cord resulting from dural arteriovenous fistula: MR imaging findings.**

E M Larsson, P Desai, C W Hardin, J Story and J R Jenkins

*AJNR Am J Neuroradiol* 1991, 12 (4) 739-743

<http://www.ajnr.org/content/12/4/739>

This information is current as of September 3, 2025.

# Venous Infarction of the Spinal Cord Resulting from Dural Arteriovenous Fistula: MR Imaging Findings

E-M. Larsson<sup>1</sup>  
P. Desai<sup>1</sup>  
C. W. Hardin<sup>2</sup>  
J. Story<sup>3</sup>  
J. R. Jenkins<sup>1</sup>

Three patients with spinal dural arteriovenous fistula presented with acute and/or progressive myelopathy. The thoracic cord was focally enlarged and poorly defined on MR images in two of the patients. One individual showed focal cord atrophy, and one demonstrated abnormal intrathecal vessels. In all patients MR studies revealed cord enhancement after IV administration of gadopentetate dimeglumine. The MR findings are believed to represent disruption of the blood-cord barrier associated with cord ischemia and/or infarction, which, in turn, is caused by venous stasis resulting from the fistula. The diagnosis in each case was confirmed by the combined results of myelography, spinal arteriography, and surgery. Surgical excision or embolization of the fistula produced a poor return of lost function but an arrest in the progression of paresis. One of the patients had constant severe back and leg pain postoperatively, and a follow-up MR study 5 months after surgery showed focal atrophy and persistent enhancement of the thoracic cord. The patient with preoperative focal cord atrophy had an MR examination 1 year prior to surgery, which revealed enhancement of the cord similar to that seen on the immediate preoperative MR study. This patient also had severe pain in the back and lower extremities preoperatively, which accompanied her progressive paraparesis.

It is believed that long-standing enhancement of the spinal cord in patients with dural arteriovenous fistula probably results from chronic progressive venous ischemia, which may be irreversible and cause pain of a central type.

*AJNR* 12:739-743, July/August 1991

Patients presenting with progressive signs and symptoms referable to spinal cord disease have long represented a difficult problem in regard to timely and accurate diagnosis. Invasive procedures such as conventional myelography and selective spinal angiography have greatly contributed to the definitive solution of this dilemma; however, MR imaging is proving to be increasingly important for evaluation of the spinal cord. In the case of spinal dural arteriovenous fistula (DAVF), thus far MR has demonstrated extramedullary flow-related signal voids, enhancement of the pathologic vessels themselves with IV administration of gadopentetate dimeglumine, enlargement and poor definition of the margins of the spinal cord, intramedullary signal changes on spin-echo sequences, and enhancement of the abnormal cord tissue with IV contrast administration [1-7]. The purpose of this study is to further evaluate the potential of MR imaging to diagnose the primary and secondary pathologic changes associated with DAVF of the spine and to correlate these findings and conventional diagnostic radiologic studies.

## Materials and Methods

Three patients presented with signs and symptoms related to the spinal cord (Table 1). MR of the spine was performed with a GE 1.5-T unit. Short TR/short TE, 500/15/2 (TR/TE/excitations), spin-echo sequences were obtained with and without contrast enhancement in

Received November 15, 1990; revision requested January 24, 1991; revision received February 13, 1991; accepted February 20, 1991.

<sup>1</sup> Department of Radiology, The University of Texas Health Science Center at San Antonio, 7703 F. Curl Dr., San Antonio, TX 78284-7800. Address reprint requests to J. R. Jenkins.

<sup>2</sup> Department of Radiology, St. Luke's Lutheran Hospital, San Antonio, TX 78229.

<sup>3</sup> Department of Neurosurgery, The University of Texas Health Science Center at San Antonio, San Antonio, TX 78284.

0195-6108/91/1204-0739  
© American Society of Neuroradiology



TABLE 1: Patient Summary: Spinal Dural Arteriovenous Fistulas

Case No.	Age	Sex	Signs/Symptoms	MR	Angiography	Therapy	Sequelae
1	73	M	Acute onset of paraplegia, bowel and bladder dysfunction	Swollen cord, abnormal vessels, cord enhancement	Dural arteriovenous fistula at T6	Transarterial embolization	Slightly improved lower extremity strength and sensation
2	67	M	Sudden onset of lower extremity weakness and numbness followed by progressive paraparesis	Swollen cord, cord enhancement (5 mo postop: focal atrophy, cord enhancement)	Dural arteriovenous fistula at T6	Surgical excision	Slightly increased lower extremity strength, new severe back pain and bilateral leg pain
3	58	F	Progressive paraparesis for 3 yr, bowel and bladder dysfunction, severe back pain and bilateral leg pain	Focal cord atrophy, cord enhancement (on two examinations with 1-yr interval)	Dural arteriovenous fistula at T5-T6	Surgical excision	Slightly improved lower extremity sensation and slight decrease of pain

the sagittal plane, and long TR/short-long TE (2500/30–80/1) sagittal sequences were also obtained. Conventional myelography with non-ionic water-soluble contrast agents was performed in all three individuals, followed by selective spinal arteriography with both conventional and digital subtraction imaging. One patient (case 2) had a follow-up MR examination 5–6 months after surgery, and another patient (case 3) had had MR imaging with sagittal short TR/short TE images with and without contrast enhancement 1 year before surgery.

## Results

In one of the three patients (case 1), MR images showed serpentine vascular abnormalities. The cord was swollen in two patients (cases 1 and 2) and showed focal atrophy in one patient (case 3). Signal intensity abnormalities (due to prolongation of T1 and/or T2) and enhancement of the cord were seen in all three individuals (Fig. 1). In case 3, an MR study obtained 1 year earlier showed focal atrophy and enhancement of the cord similar in appearance to the repeat preoperative study (Fig. 2). This patient experienced atypical chronic back and bilateral lower-extremity pain. Myelography confirmed the vascular malformation in two of these patients (cases 1 and 2) by demonstrating the intrathecal location of the enlarged draining veins (Fig. 1). The myelogram in patient 3 showed subtle tortuous filling defects in the upper posterior thoracic subarachnoid space that at the time were considered to be an equivocal finding but in retrospect were most probably pathologic. The selective spinal arteriogram defined the focus of the DAVF in all three patients (Fig. 1). All lesions filled from spinal radicular arteries in the thoracic region. Two patients had surgical ligation/resection of the fistula and one had transarterial embolization with liquid adhesives with resultant stabilization of paresis in each subject.

Patient 3 had a new onset of atypical severe back and bilateral leg pain after surgery. A follow-up MR examination 5 months postoperatively showed focal atrophy of the cord at the location of preoperative swelling but persistent enhancement (Fig. 2). The low signal intensity in the cord seen on preoperative short TR/TE images had normalized (Fig. 2). These findings are summarized in Table 1.

## Discussion

DAVF is the most common vascular anomaly of the spine, representing 80% of spinal disorders [8]. Men over 40 years old are affected more frequently than other population groups. The initial symptoms in DAVF are usually leg weakness and pain, but sensory loss and bowel and bladder dysfunction may be associated [9–11]. Most patients experience slowly progressive deterioration of neurologic function with or without remission; however, in some cases the symptoms may be acute in onset [9–11]. Physical activity often elicits an exacerbation of the symptoms. At surgery the vascular nidus of the arteriovenous shunt is found to be embedded in the dura covering a proximal nerve root extending into the adjacent dura of the spinal canal. Initially, the venous drainage is often directed cranially. Blood flowing through the fistula is carried to the intradural perimedullary coronal venous plexus, which becomes dilated, tortuous, and elongated. The absence of valves between the coronal venous plexus and the intramedullary radial veins facilitates the transmission of high venous pressure to the cord tissue, causing congestive myelopathy [9]. The observed progressive neurologic deterioration has been attributed to this increased venous pressure within the cord with resultant venous stasis and ischemia [12, 13]. Most DAVFs are localized to the lower half of the spine, which is compatible with an acquired pathogenesis dependent on an upright posture [9].

In patients with spinal DAVF, typical cord findings on MR consist of swelling of the affected segments with ill-defined margins, relatively low signal intensity on short TR/TE images, hyperintensity (even compared with CSF) on long TR/TE images, and contrast enhancement of involved areas [2, 4–7]. All these changes are believed to be due to the venous stasis resulting in edema, ischemia, and/or frank venous infarction of the spinal cord. The spread of venous hypertension away from the focus of the DAVF in the cranial and caudal directions causes damage to the cord over a long distance [14]. Therefore, the location of the shunt (fistula) does not necessarily correlate closely with the level of clinical symptoms. If no abnormal intraspinal vessels are seen on MR, the differential diagnosis of the MR findings outlined



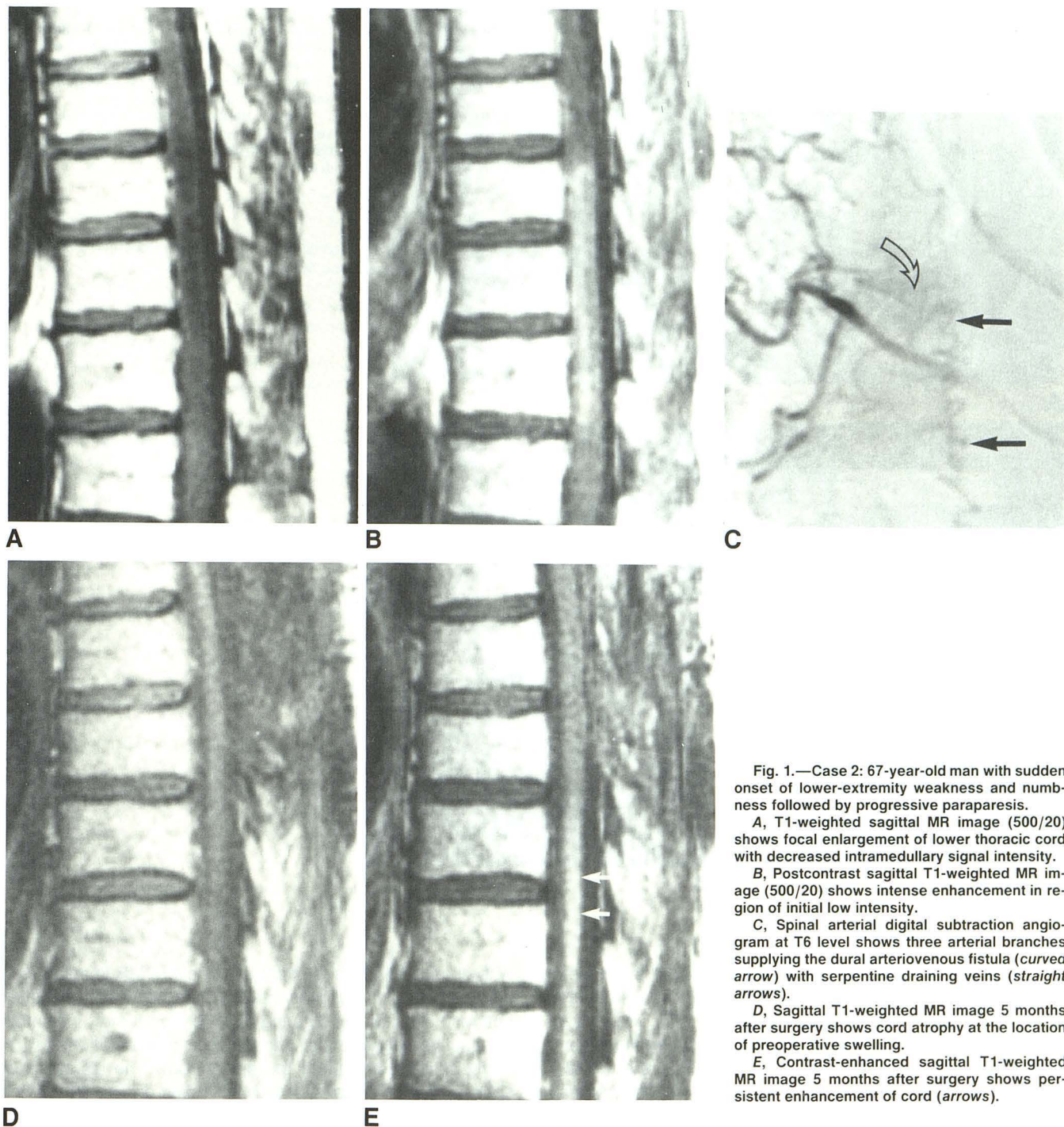


Fig. 1.—Case 2: 67-year-old man with sudden onset of lower-extremity weakness and numbness followed by progressive paraparesis.

A, T1-weighted sagittal MR image (500/20) shows focal enlargement of lower thoracic cord with decreased intramedullary signal intensity.

B, Postcontrast sagittal T1-weighted MR image (500/20) shows intense enhancement in region of initial low intensity.

C, Spinal arterial digital subtraction angiogram at T6 level shows three arterial branches supplying the dural arteriovenous fistula (curved arrow) with serpentine draining veins (straight arrows).

D, Sagittal T1-weighted MR image 5 months after surgery shows cord atrophy at the location of preoperative swelling.

E, Contrast-enhanced sagittal T1-weighted MR image 5 months after surgery shows persistent enhancement of cord (arrows).

above include intramedullary tumor, inflammation, active demyelination, acquired ischemia of arterial origin, or, rarely, infarction due to venous thrombosis without the presence of DAVF. The postoperative reduction of cord swelling on MR as well as of intramedullary signal changes have been reported previously [7]. However, the persistent enhancement of the ischemic cord lesion on contrast-enhanced images, as seen in our case 2 postoperatively (Fig. 1), has, to our knowledge, not been described by other investigators. This

persistent enhancement with contrast material combined with some degree of remaining intramedullary high signal intensity on non-contrast-enhanced long TR/TE images in our patient most likely represents irreversible ischemic cord damage.

The histopathologic changes in the cord seen at necropsy in untreated cases of DAVF include altered intramedullary capillaries and veins with thick hyaline walls [15]. Recent or organized older thrombus may be seen within these intramedullary vessels. In addition, the gray and white matter of



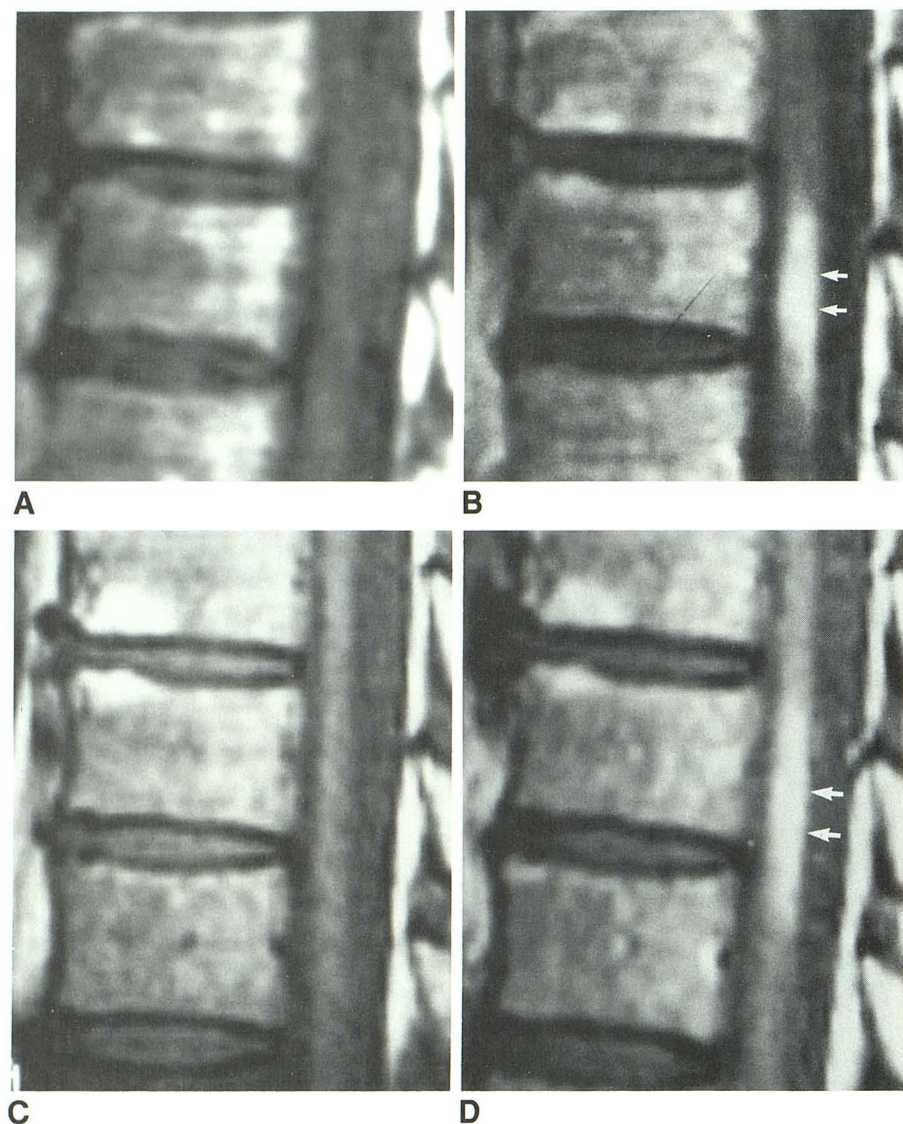


Fig. 2.—Case 3: 58-year-old woman with progressive paraparesis, bowel and bladder dysfunction, and pain in back and both legs.

A and B, Pre- (A) and postcontrast (B) sagittal T1-weighted MR images show focal atrophy and enhancement of cord (arrows in B).

C and D, Repeat pre (C) and postcontrast (D) sagittal T1-weighted MR images 1 year later demonstrate same findings as in A and B (arrows in D).

the cord are affected by an unusual form of incomplete necrosis [15]. Possibly, this partial necrosis is related to the chronic contrast enhancement pattern on MR, which was seen in two of the subjects in this series. This enhancement pattern appears to occur over a longer time than that usually seen in infarcts of the brain. The chronic cord enhancement was noted both pre- and postoperatively (case 3, Fig. 2).

The ischemic cord damage may cause an interruption of somatosensory pathways (deafferentation). It has been suggested that so-called "central pain" is the result of spinothalamic deafferentation (e.g., at the cord level). This denervation results in neuronal hypersensitivity in unnamed neurons, which induces pain in susceptible patients [16]. The severe pain noted in our two patients with long-standing enhancement may therefore represent central pain activated by chronic ischemic cord damage.

In summary, in patients presenting with acute and/or progressive signs and symptoms involving the lower extremities,

with or without bowel/bladder dysfunction, MR imaging coupled with the clinical presentation may allow differentiation between such widely differing disorders as tumor, inflammation, active demyelination, and vascular malformation that directly or indirectly affect the spinal cord. The diagnosis of spinal DAVF is suggested by MR studies demonstrating the constellation of cord enlargement or even cord atrophy, abnormal cord intensity on all sequences, enhancement with contrast material of the cord itself as well as of abnormal intrathecal vessels, and associated flow-related signal voids on preenhancement studies. The detection of such characteristic findings warrants additional diagnostic studies (myelography followed by spinal angiography) for confirmation and detailed anatomic definition in order to expedite definitive treatment directed toward arresting the progressive pathologic process associated with DAVF. Pre- or postoperative long-standing contrast enhancement of the cord may be observed and is believed to be due to irreversible or chronic

progressive venous ischemia, which in some patients correlates with pain suggestive of a central origin.

#### ACKNOWLEDGMENT

We thank J. Murray for manuscript preparation.

#### REFERENCES

1. Di Chiro G, Doppman JL, Dwyer AJ, Patronas NJ, et al. Tumors and arteriovenous malformations of the spinal cord: assessment using MR. *Radiology* **1985**;156:689-697
2. Masaryk TH, Ross JS, Mochi MI, Ruft RL, Selman WR, Ratcheson RA. Radiculomeningeal vascular malformations of the spine: MR imaging. *Radiology* **1987**;164:845-849
3. Doppman JL, Di Chiro G, Dwyer AJ, Frank JL, Oldfield EH. Magnetic resonance imaging of spinal arteriovenous malformations. *J Neurosurg* **1987**;66:830-834
4. Minami S, Sagoh T, Nishimura K, Yamashita K, et al. Spinal arteriovenous malformation: MR imaging. *Radiology* **1988**;169:109-115
5. Terwey B, Becker H, Thron A, Vahldiek G. Gadolinium-DTPA enhanced MR imaging of spinal dural arteriovenous fistulas. *J Comput Assist Tomogr* **1989**;13:30-37
6. Dillon WP, Norman D, Newton TH, Bolla K, Mark A. Intradural spinal cord lesions: Gd-DTPA-enhanced MR imaging. *Radiology* **1989**;170:229-237
7. Isu T, Iwasaki Y, Akino M, Koyanagi I, Abe H. Magnetic resonance imaging in cases of spinal dural arteriovenous malformation. *Neurosurgery* **1989**;6:919-923
8. Thron AK. *Vascular anatomy of the spinal cord. Neuroradiological investigations of clinical syndromes.* Wien: Springer-Verlag, **1988**:65-105
9. Rosenblum B, Di Chiro G. Spinal AVM: a comparison of dural AVF and AVMs in 81 patients. *J Neurosurg* **1987**;67:795-802
10. Symon L, Kuyama H, Kendall B. Dural arteriovenous malformations of the spine. Clinical features and surgical results in 55 cases. *J Neurosurg* **1984**;60:238-247
11. Choi IS, Berenstein A. Surgical neuroangiography of the spine and spinal cord. *Radiol Clin North Am* **1988**;26:1131-1141
12. Aminoff MJ, Barnard RO, Logue V. The pathophysiology of spinal vascular malformations. *J Neurol Sci* **1974**;23:255-263
13. Kendall BE, Logue V. Spinal epidural angiomatous malformations draining into intrathecal veins. *Neuroradiology* **1977**;13:181-189
14. Hassler W, Thron A, Grote EH. Hemodynamics of spinal dural arteriovenous fistulas. An intraoperative study. *J Neurosurg* **1989**;70:360-370
15. Hughes JT. Disorders of the spine and spinal cord. In: Adams JH, Corsellis JAN, Duchen LW, eds. *Greenfield's neuropathology.* New York: Wiley, **1984**:799-806
16. Tasker RR. Pain resulting from central nervous system pathology (central pain). In: Bonica JJ, ed. *The management of pain.* Philadelphia: Lea & Febiger, **1990**:264-284