



Get Clarity On Generics

Cost-Effective CT & MRI Contrast Agents



FRESENIUS
KABI

WATCH VIDEO

AJNR

Value of subtraction images in the detection of hemorrhagic brain lesions on contrast-enhanced MR images.

S L Hanna, J W Langston and S A Gronemeyer

AJNR Am J Neuroradiol 1991, 12 (4) 681-685

<http://www.ajnr.org/content/12/4/681>

This information is current as
of August 30, 2025.

Value of Subtraction Images in the Detection of Hemorrhagic Brain Lesions on Contrast-Enhanced MR Images

Soheil L. Hanna¹
James W. Langston
Suzanne A. Gronemeyer

Contrast-enhanced T1-weighted MR images are known to improve the detection and conspicuity of CNS lesions; however, lesion enhancement may be indistinguishable from contiguous hemorrhagic areas of intrinsically increased signal intensity. In a series of cranial MR studies in 22 pediatric oncologic patients with evidence of subacute hemorrhage, we found that subtracting the unenhanced from the enhanced T1-weighted images was essential in 14 of the cases to visualize and/or characterize the enhanced tissue in the presence of adjacent hemorrhage. In six patients, a nodular pattern of enhancement suggestive of tumor was detected and/or outlined only after subtraction. In eight patients, linear benign-appearing enhancing margins were seen clearly only after subtraction. In the remaining eight patients, the presence and shape of enhancement was verified with subtraction.

Subtraction is a useful, simple, and rapid postprocessing procedure that does not increase scan time or require modification of standard pulse sequences. Subtraction separates the enhanced areas from adjacent bright hemorrhage.

AJNR 12:681-685, July/August 1991; *AJR* 157: October 1991

The benefit of gadopentetate dimeglumine-enhanced T1-weighted MR imaging in detecting brain tumors in children and adults has been reported [1, 2]. Contrast-enhanced MR imaging has also been found useful in detecting residual tumor and gliosis in postoperative patients [3]. However, it may be difficult or impossible to detect the presence or distinguish the shape of the enhanced region from adjacent bright subacute hemorrhage. In 22 cranial MR studies with evidence of subacute hemorrhage, we applied a simple subtraction technique that we have successfully used to evaluate contrast-enhanced MR images of musculoskeletal tumors [4]. Using the standard digital image subtraction software on our scanner, we subtracted the unenhanced T1-weighted images from the corresponding images obtained after administration of gadopentetate dimeglumine. The purpose of this study was to evaluate the use of image subtraction with contrast-enhanced MR imaging of hemorrhagic brain lesions.

Patients and Methods

During a 2-year period from August 1988 to July 1990, 93.3% of 829 pediatric oncologic patients with symptoms of intracranial disease due to known or suspected primary or secondary brain neoplasia were studied with cranial MR imaging before and after enhancement with gadopentetate dimeglumine. Of those, 22 patients had MR evidence of subacute hemorrhage. Subjects included six girls and 16 boys ranging in age from 9 months to 18 years (mean, 9.6 years). Their diagnoses are included in Table 1. Eleven of the 22 patients were examined 1 to 3 weeks after tumor resection to exclude residual tumor. Of the remaining 11 patients, one was examined for evaluation of a hemorrhagic primary tumor, five for known hemorrhagic metastases, and five for parenchymal hemorrhage with suspected underlying neoplasia. All studies were performed after obtaining written informed consent from the

Received September 17, 1990; revision requested December 21, 1990; revision received January 15, 1991; accepted January 23, 1991.

This work was supported in part by the National Cancer Institute, Cancer Center Support (CORE) grant P30CA21765 and by the American Lebanese Syrian Associated Charities.

¹All authors: Department of Diagnostic Imaging, St. Jude Children's Research Hospital, 332 N. Lauderdale, P.O. Box 318, Memphis, TN 38101, and Department of Radiology, University of Tennessee, Memphis, TN. Address reprint requests to J. W. Langston.

0195-6108/91/1204-0681
© American Society of Neuroradiology

TABLE 1: MR Subtraction Results in 22 Patients with Intracranial Hemorrhage

Case No.	Age (years)	Diagnosis	Postoperative Enhancement			Shape Determined Only After Subtraction		Imaging Impression
			Y/N	No. of Weeks Postop.	Seen Only After Subtraction	Y/N	Shape	
1	15	A	Yes	3	Yes	Yes	Linear	No tumor
2	3	M	Yes	2	No	Yes	Nodular	Residual
3	0.75	A	Yes	3	Yes	Yes	Linear	No tumor
4	15	A	Yes	3	No	No	Linear	No tumor
5	3	M	Yes	1	No	Yes	Linear	No tumor
6	10	GBM	Yes	2	No	Yes	Nodular	Residual ^a
7	13	GBM	Yes	2	No	Yes	Nodular	Residual
8	6	A	Yes	3	No	Yes	Linear	No tumor
9	4	E	Yes	2	Yes	Yes	Linear	No tumor
10	7	PNET	Yes	2	No	No	Linear	No tumor
11	7	GC	Yes	1	No	Yes	Nodular	Residual
12	9	ALL	No	—	Yes	Yes	Linear	No tumor
13	15	ALL	No	—	Yes	Yes	Linear	No tumor
14	5	ALL	No	—	Yes	Yes	Linear	No tumor
15	6	M	No ^c	—	Yes	Yes	Nodular	Tumor ^b
16	6	NB	No	—	Yes	Yes	Nodular	Tumor
17	15	RD	No	—	No	No	Nodular	Tumor
18	17	OS	No	—	No	No	Nodular	Tumor
19	17	OS	No	—	No	No	Nodular	Tumor
20	18	OS	No	—	No	No	Nodular	Tumor
21	3	M	No ^c	—	No	No	Nodular	Tumor
22	1	NB	No	—	No	No	Nodular	Tumor

Note.—A = astrocytoma, ALL = leukemia, E = ependymoma, GBM = glioblastoma multiforme, GC = gliomatosis cerebri, M = medulloblastoma, NB = neuroblastoma, OS = osteosarcoma, PNET = primitive neuroectodermal tumor, RD = rhabdoid.

^a Biopsy proved GBM.

^b Biopsy and serologically proved visceral larva migrans.

^c Hemorrhage in remote location from surgical site.

patients or their guardians and with approval of the institutional clinical trials review committee. The MR studies of all 22 patients showed intracranial regions with increased signal intensity on T1- and T2-weighted images consistent with methemoglobin [5]. The presence of subacute blood made the visual detection of possible intrinsic or adjacent enhancement difficult.

The MR examinations were performed on a 1.0-T Magnetom scanner (Siemens Medical Systems, Iselin, NJ). Routine evaluation included sagittal and transverse T1-weighted, 550/15/2 (TR/TE/excitations), images and double-echo spin-density and T2-weighted (2500/25–90/1) transverse images. A 256 × 256 matrix, 25-cm field of view, and section thickness of 5 mm with a 1-mm interslice gap were used in all sequences. Gadopentetate dimeglumine (Berlex Laboratories, Cedar Knolls, NJ) at a dose of 0.1 to 0.2 mmol/kg was then administered slowly via a previously installed vascular access device or peripheral IV route without moving the patient. Five min after administering the contrast material, transverse T1-weighted sequences were repeated using the same imaging parameters as those used for the precontrast transverse T1-weighted sequences. The transmitter and receiver attenuator values were held constant between the pre- and postcontrast images as were the gray scale adjustments.

Corresponding unenhanced and enhanced anatomic slices showing bright blood and possible adjacent enhancement were chosen for subtraction. The pre- and postcontrast images were reviewed on the monitor to determine if motion had occurred between the unenhanced and enhanced T1-weighted images. In a few cases, slight in-plane motion was noted, and the images were pixel-shifted in the appropriate horizontal and/or vertical direction to correct image alignment. Subtraction was then performed by displaying the contrast-enhanced image and electronically subtracting the unenhanced image on a

pixel-by-pixel basis using the image subtraction function available as standard software on our system. Production of the subtracted image was typically completed in 10 sec. The resultant images reflected the enhancement provided by contrast material alone after subtraction of all unenhanced areas.

To determine the clinical utility of subtraction technique, we visually evaluated the unenhanced and enhanced T1-weighted images for the presence or absence of enhancement and the shape (linear or nodular) of the enhancing region, and then compared these findings with the subtracted images. Subtraction was considered useful if previously undetected enhancement was seen and/or the configuration of the enhancing region was better delineated.

Results

Subtraction was successfully performed in all 22 cases. None of the subtracted images showed uncorrectable misregistration due to rotatory patient head movement.

All 22 cases showed enhancement either around or within the subacute hemorrhagic areas. Subtraction improved contrast between the enhanced areas and adjacent bright subacute hemorrhage on all 22 patients, revealing only the enhanced regions contrasted against a muted background.

In eight of the 22 cases, subtraction was essential in the detection of enhancement, which was otherwise not visible because of the adjacent subacute hemorrhage. In six of the remaining 14 cases in which the presence of enhancement was visually detected without subtraction, subtraction was

necessary to differentiate a linear from a nodular pattern (Table 1).

A benign-appearing linear and peripheral pattern of enhancement was found in 10 cases, eight of which could only be separated from the adjacent subacute hemorrhage by subtraction. In the remaining 12 cases, a nodular enhancing configuration suggestive of tumor was present.

The subtracted images outlined the enhanced postoperative margins in all 11 postsurgical cases. Seven had a linear enhancement pattern consistent with gliosis or blood-brain barrier disruption, thus suggesting absence of residual tumor. Residual focal nodular enhancement was demonstrated in the remaining four patients (Fig. 1). In the second group (Table 1, cases 12–16), which included five patients with parenchymal hemorrhage who were studied to determine if underlying neoplasia was present, subtraction was necessary to demonstrate metastatic-like nodular enhancement in two patients as the underlying cause of hemorrhage (Fig. 2). In the remaining three patients, subtraction confirmed absence of associated nodular enhancement. In the third group, including six patients (Table 1, cases 17–22) with known intracranial hemorrhagic malignancy, the subtracted images highlighted the enhanced tumor component permitting more accurate measurement of tumor extent and subsequent monitoring of tumor response to therapy.

On the basis of the findings from the subtracted images, two patients underwent a stereotaxic biopsy procedure. One patient (case 6) had an enhanced nodular area at the resection margins that was precisely outlined only after subtraction; biopsy confirmed the presence of residual glioblastoma multiforme (Fig. 1). The other patient (case 15), treated for medulloblastoma, had unenhanced T1-weighted images

showing several hundred small, bright, parenchymal brain lesions. Subtraction disclosed that only three lesions enhanced, thus providing guidance for the subsequent biopsy, which aided in the serologic diagnosis of visceral larva migrans infection.

Discussion

Contrast-enhanced MR imaging has proved very useful for evaluating intracranial abnormalities [1], including pediatric brain tumors [2]. Contrast enhancement enables detection of areas with abnormal vasculature and/or disrupted blood-brain barrier and thus permits more accurate assessment of tumors than does unenhanced MR imaging alone, especially when separation of tumor from surrounding edema is difficult [1, 2]. Furthermore, contrast-enhanced T1-weighted images are useful in morphologically differentiating residual tumor from nonhemorrhagic postoperative gliosis and encephalomalacia, since all may have similar signal characteristics prior to contrast administration [3]. Typically, a linear pattern of enhancement around the margins of resection is more consistent with gliosis or blood-brain barrier disruption, while a focal nodular configuration is more consistent with residual tumor [3].

Not infrequently, the presence of bright subacute hemorrhage prevents appreciation of contiguous enhanced regions of similar increased signal intensity. The lack of contrast between bright blood and adjoining bright enhancement is caused by shortening of the T1 relaxation time of the contrast-enhanced areas to an extent comparable to the shortening due to methemoglobin in contiguous hemorrhagic regions [5]. Several diagnostic problems may be caused by this lack

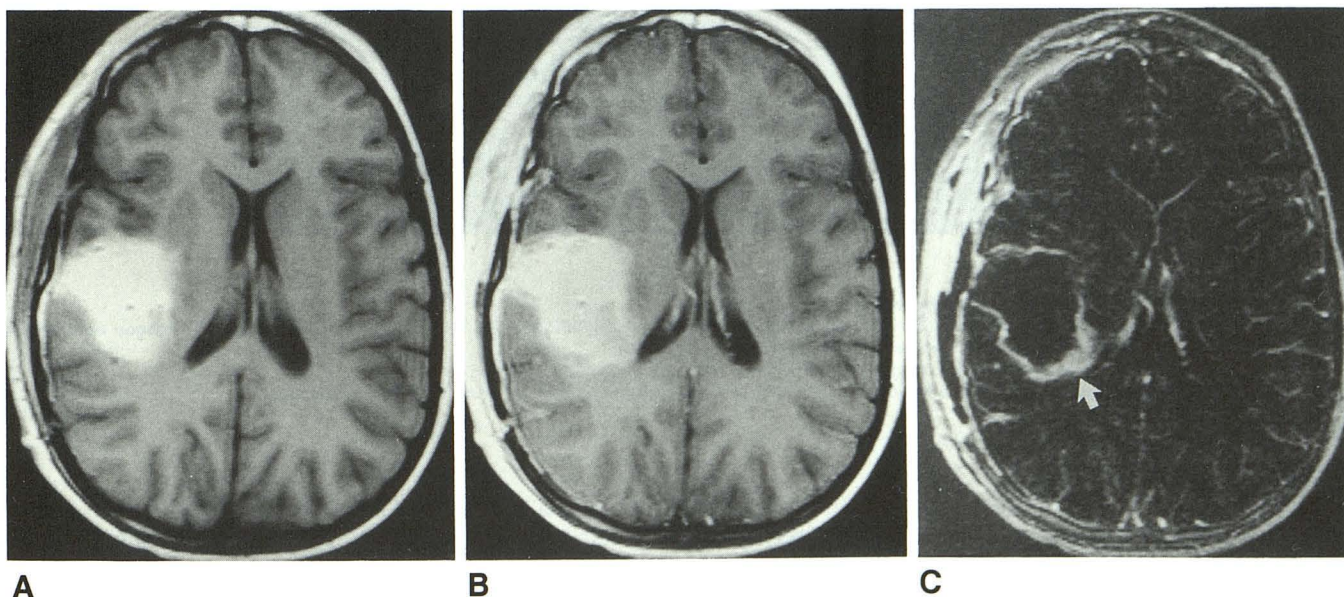


Fig. 1.—Postoperative MR images of a 10-year-old patient with right temporal glioblastoma multiforme.
A, Unenhanced transverse T1-weighted (550/15) image shows right postsurgical changes with a hyperintense area consistent with subacute hemorrhage.
B, Contrast-enhanced T1-weighted (550/15) image of same slice shows enhancement about the margins of resection that is difficult to distinguish from adjacent hemorrhage.
C, Subtraction of A from B clearly shows posteromedial nodular enhancement (arrow) consistent with residual tumor, which was confirmed by biopsy.

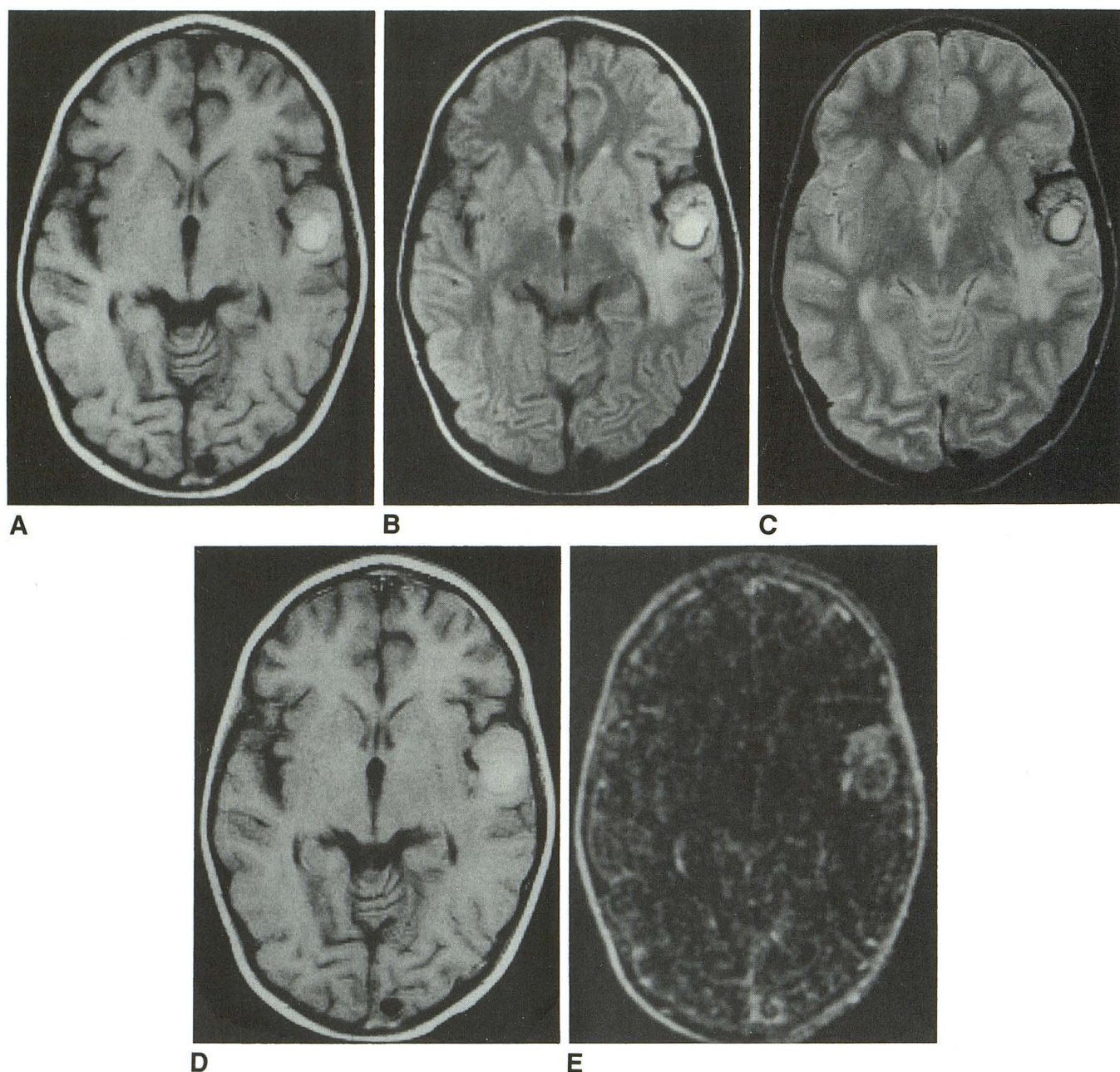


Fig. 2.—Six-year-old patient with known retroperitoneal neuroblastoma. A–C, Unenhanced transverse T1-weighted (550/15) (A) proton-density-weighted (2500/25) (B), and T2-weighted (2500/90) (C) images obtained at same level show a left temporal lesion consistent with subacute hemorrhage. D, Contrast-enhanced T1-weighted (550/15) image does not clearly show enhancement. E, Subtraction of A from D shows adjacent anterior nodular enhancement, suggesting that tumor caused the hemorrhage.

of contrast. First, it may preclude precise discernment of the enhanced boundaries of hemorrhagic malignant neoplasms and thereby prevent the accurate measurement of tumor extent necessary for monitoring tumor response to therapy. Second, the presence of postoperative subacute hemorrhage may prevent delineation of the surgical margins and subsequent differentiation of contiguous enhanced residual tumor from gliosis or blood-barrier disruption. Third, the occurrence

of cerebral parenchymal hemorrhage in patients with known systemic oncologic diseases such as the leukemias mandates exclusion of possible underlying enhanced neoplasm that could be masked by hemorrhage.

In theory, enhancement can be confirmed by measuring the mean signal intensity of regions of interest directly from the enhanced and unenhanced images, but this does not provide information about the shape of the enhanced region. Further-

more, quantifying signal intensities requires prior detection of sites of abnormality, which is not always possible. Subtraction can be performed more rapidly than can mean signal intensity measurements and also shows lesions that would otherwise have been missed (Fig. 2). Additionally, subtraction provides a global perception of the morphologic features of the enhanced regions that is necessary to distinguish a nodular from a linear configuration. This is demonstrated in Figure 1C, where the subacute blood has been subtracted, leaving linear enhanced resection margins consistent with gliosis or blood-brain barrier disruption [3]. However, by revealing the inner border of the enhanced lesion with subtraction, a nodular pattern of enhancement was readily visible posteromedially, prompting us to perform a stereotaxic biopsy that confirmed the presence of residual tumor. Other uses of subtraction in cranial MR imaging include differentiation of enhanced calvarial metastases from adjacent bright fatty marrow [6].

Subtraction may not be possible when rotatory head motion occurs in the interval between the pre- and postcontrast sequences producing uncorrectable misregistration of the subtracted images [4]; however, we did not encounter this problem in our series. Secure stabilization of the subject's head and consecutive acquisition of the unenhanced and enhanced T1-weighted images decrease the likelihood of motion.

In summary, image subtraction is a simple, rapid, postprocessing procedure that does not increase scan time or require modification of standard T1-weighted pulse sequences. Subtraction can differentiate enhancement from adjacent subacute hemorrhage and thus increase the level of confidence when the shape of the enhancing area is clearly demonstrated. Our experience indicates that without subtraction, intracranial lesions may be missed.

REFERENCES

1. Hesselink JR, Healy ME, Press GA, Brahme FJ. Benefits of Gd-DTPA for MR imaging of intracranial abnormalities. *J Comput Assist Tomogr* **1988**;12:266-274
2. Powers TA, Partain CL, Kessler RM, et al. Central nervous system lesions in pediatric patients: Gd-DTPA-enhanced MR imaging. *Radiology* **1988**;169:723-726
3. Bird CR, Drayer BP, Medina M, Reke HL, Flom RA, Hodak JA. Gd-DTPA-enhanced MR imaging in pediatric patients after brain tumor resection. *Radiology* **1988**;169:123-126
4. Hanna SL, Langston JW, Gronemeyer SA, Fletcher BD. Subtraction technique for contrast-enhanced MR images of musculoskeletal tumors. *Magn Reson Imaging* **1990**;8:213-215
5. Atlas SW, Grossman RI, Gomori JM, et al. Hemorrhagic intracranial malignant neoplasms: spin-echo MR imaging. *Radiology* **1987**;164:71-77
6. West MS, Russell EJ, Breit R, Sze G, Kim KS. Calvarial and skull base metastases: comparison of nonenhanced and Gd-DTPA-enhanced MR images. *Radiology* **1990**;174:85-91