



Get Clarity On Generics

Cost-Effective CT & MRI Contrast Agents

 FRESENIUS
KABI

[WATCH VIDEO](#)

AJNR

Anatomic localization of cerebral cortical function by magnetoencephalography combined with MR imaging and CT.

W W Orrison, L E Davis, G W Sullivan, F A Mettler, Jr and E R Flynn

This information is current as of August 7, 2025.

AJNR Am J Neuroradiol 1990, 11 (4) 713-716
<http://www.ajnr.org/content/11/4/713>

Anatomic Localization of Cerebral Cortical Function by Magnetoencephalography Combined with MR Imaging and CT

William W. Orrison¹⁻⁴
 Larry E. Davis^{2,5}
 Gary W. Sullivan⁶
 Fred A. Mettler, Jr.^{1,3,4}
 Edward R. Flynn⁶

Magnetoencephalography (MEG) monitors magnetic field amplitudes, which are time averages of evoked neuronal responses. This method can detect magnetic fields emanating from the brain and localize the neuronal source. The location of somatosensory neuronal sources for voluntary right thumb and right index finger flexions were determined in four normal volunteers by using a seven-sensor neuromagnetometer inside a magnetically shielded room. These neuronal sources were then identified on the individual's respective CT or MR scans, and correlation was accomplished by geometric calculations, direct cranial measurement, and surface marker identification. Specific functional magnetic fields were located over the appropriate sensory motor cortex; however, there was considerable variation in the exact site.

Magnetoencephalography combined with CT and MR may improve localization of normal and abnormal neurologic function.

AJNR 11:713-716, July/August 1990

Received December 27, 1988; revision requested February 13, 1989; revision received December 19, 1989; accepted December 21, 1989.

Presented at the annual meeting of the American Society of Neuroradiology, Chicago, 1988.

This work was supported in part by the Veterans Administration Research Service Department of Energy, Los Alamos, NM, and by Diasonics, Inc.

¹Department of Radiology, University of New Mexico School of Medicine, Albuquerque, NM 87131. Address reprint requests to W. W. Orrison.

²Department of Neurology, University of New Mexico School of Medicine, Albuquerque, NM 87131.

³Center for Noninvasive Diagnosis, University of New Mexico School of Medicine, Albuquerque, NM 87131.

⁴Department of Radiology, New Mexico Federal Regional Medical Center, Albuquerque, NM 87108.

⁵Department of Neurology, New Mexico Federal Regional Medical Center, Albuquerque, NM 87108.

⁶Los Alamos National Laboratory, Los Alamos, NM 87544.

0195-6108/90/1104-0713

© American Society of Neuroradiology

The electrical activity of the brain produces weak magnetic fields as a result of associated neuronal currents that are measurable outside the cranium with the use of sensitive magnetic detectors [1, 2]. Plotting spatial distribution of magnetic-field intensities enables three-dimensional localization of this neuronal activity [1, 3]. Determination of the specific location of neuronal activity can be directly translated to CT or MR images by geometric calculation, direct cranial measurement, and surface-marker identification. The location of somatosensory neuronal sources for voluntary right thumb and right index finger flexion were identified on corresponding MR and CT images in four normal volunteers.

Materials and Methods

Four subjects (three men and one woman) 21-43 years old were studied with a neuromagnetometer (Biomagnetic Technologies, Inc., San Diego) in a magnetically shielded room. All subjects completed an informed consent form and were evaluated according to UNM Human Research Review Committee approved protocol. Two subjects were scanned with CT in axial and coronal planes (GE-9800, General Electric, Milwaukee); and four subjects were imaged with MR, two on a 1.5-T superconducting system (Signa, General Electric, Milwaukee) and two on a 0.064-T permanent magnet (Access, Toshiba, South San Francisco).

The neuromagnetometer consisted of superconducting quantum interference devices (SQUID) and the superconducting detection coils immersed in a bath of liquid helium housed within a dewar (Fig. 1). The detection coil monitored the biomagnetic field directly, and was connected to a superconducting input coil inductively coupled to the SQUID. The electronics, located outside the dewar, monitored the magnetic flux changes within the SQUID and also amplified the signal [4, 5].

Seven independent signals or magnetic fields were monitored. The gradiometers were spatially separated in the following arrangement: one central coil surrounded by six coils in a 2-cm diameter equally spaced in a regular hexagon configuration. This seven-sensor instrument was located over the left posterior frontal and parietal cortex (Fig. 2). The subjects were

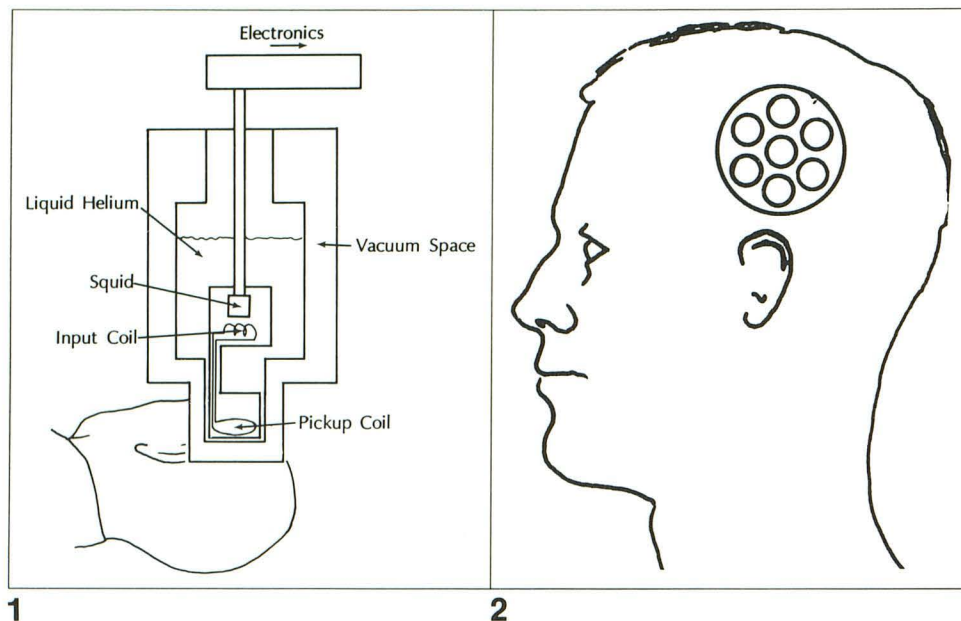


Fig. 1.—Schematic of neuromagnetometer arrangement including liquid helium dewar and SQUID system. The detection coil is located as close as possible to the subject.

Fig. 2.—Seven-sensor detection gradiometer array positioned over the parietal cortex.

initially evaluated at rest. The seven sensors were then used to record magnetic fields from a trial of 30 consecutive voluntary, self-paced, right index finger flexions or right thumb flexions. Recordings of magnetic activity represent change from resting baseline measurements considered as a zero reference point. Finger flexion occurred at the proximal metacarpal-phalangeal joint and at the proximal-middle phalangeal joint with eight repetitive examinations resulting in an average of 240 passes on each subject.

The exact location of the neuronal activity was determined by using isocontour mapping (Fig. 3). Neuronal activity was projected to the cranial surface and localized on corresponding CT and MR images by means of three methods:

1. Direct measurement. A direct measurement of the curved superior dimension of the coronal slice on the MR or CT scan was made on the display terminal. A line tangential to the skull was drawn at the location of the projected neuronal source, and a line perpendicular to this line was constructed. The depth of the neuronal activity was predicted by the MEG data as calculated from the distance between the peak positive and peak negative activities. This distance was measured internally on the perpendicular line [1].

2. Geometric calculation. Calculated measurements of the cranial surface from a skull model were plotted and the depth of the MEG neuronal activity from the skull surface was determined. These calculated coordinates were used to locate the source on corresponding CT or MR images, with the periauricular point and the outer canthus of the eye as references.

3. Surface marker identification. The midway position between the negative and positive magnetic fields was marked on the surface of the skull using a radiopaque catheter for CT and an oil-filled capsule for MR. The CT or MR examination was then performed with exact slices through the area of surface marker determination. The depth of the neuronal activity was determined by the MEG measurements and calculated on the respective axial, coronal, and sagittal slices.

Results

Successful localization of neuronal activity by MEG was accomplished in all four subjects with the magnetic field peaks

ranging from 196 femtotesla to 295 femtotesla expressed as the absolute average of both extrema (Table 1). Reference point determination on CT and MR scans was also successful (Fig. 4). The geometric calculation and direct skull measurement techniques were not reliably reproducible when compared with the surface marker method. Multiple attempts at repeating the geometric and direct measurement techniques were unsuccessful with variations up to 1 cm. The surface marker technique was more reproducible in all subjects. Direct coronal imaging of the surface marker was the most expeditious method for rapid determination of the focus of neuronal activity.

An unexpected finding in this small sample of subjects was a variation in thumb and forefinger location on the cerebral cortex. Although thumb and finger were in correct alignment, one subject had a high vertex location of thumb and forefinger activity and a second subject had a lower temporoparietal location of this activity. The difference between the remaining two subjects (with activity in the expected midparietal cortex as compared with the high or low locations) was not considered significant.

Discussion

Biomagnetic fields are extremely small compared with the earth's magnetic field and with ambient magnetic noise from electric motors, moving magnetic objects, power lines, and particularly indoor electricity [2]. An unshielded clinical setting may have background magnetic noise as much as 10,000 times the neuronal magnetic field.

Neuronal magnetic fields are also very small compared with the commonly used magnetic field measurements of Tesla and gauss. For example, typical neuronal activity is approximately 1×10^{-9} gauss as compared with the earth's magnetic field of approximately 5×10^{-1} gauss. MR imaging is per-

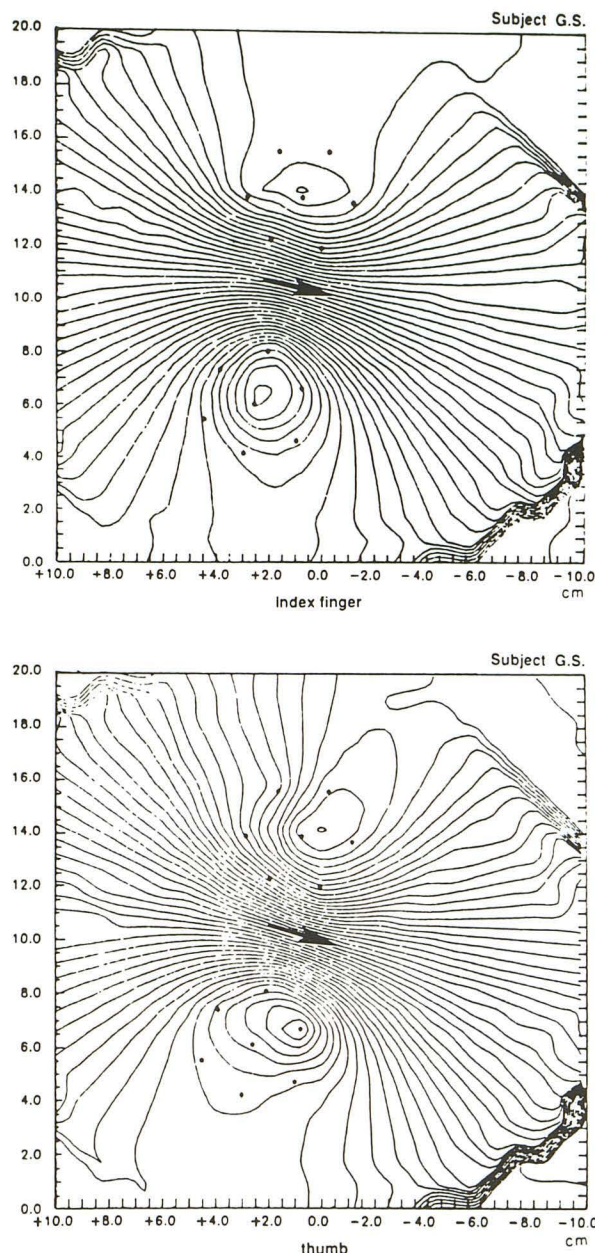


Fig. 3.—Isocontour maps of magnetic responses evoked by flexion of right index finger (top) and right thumb (bottom) measured from the left hemisphere in one subject. The graphs demonstrate the dipoles (arrows) in a coordinate system. Sensor locations (black dots) provide amplitude reference points.

formed clinically at 200 to 15,000 gauss (0.02 to 1.5 T). Owing to the extremely small amplitudes of neuronal magnetic fields, the units for neuronal activity are generally given in picotesla (pT); 1 pT equals 10^{-12} T, and the femtotesla (fT); 1 fT equals 10^{-15} T [4].

It is necessary to shield the MEG examination room from the relatively massive ambient (background) magnetic noise in order to evaluate these extremely small amplitudes. Therefore, radiofrequency and magnetic shielding are both required

TABLE 1: Magnetoencephalography and MR/CT Correlation

Case No.	Age (yrs)	Sex	Magnetic Activity (fT)	Cortical Location
1	43	M	196	Normal
2	21	M	295	High
3	39	F	220	Low
4	37	M	250	Normal

Note.—Magnetic activity = change in amplitude from baseline, fT = femtotesla = 1×10^{-15} T.

for MEG monitoring. The most significant factor in decreasing background noise is the gradiometer design of the coil [2, 4].

The extremely weak neuronal magnetic fields are monitored by the neuromagnetometer and subsequently displayed by plotting magnetic field lines (contour maps). These contour maps or isofield contours are plotted over the corresponding area of the brain. The contour map is a picture of the magnetic field amplitudes emanating from a neuronal source located in a sulcus or fissure, and plotted on the skull surface (Fig. 3). These isofield contours or maps of magnetic field activity determine the location of the neuronal source, which may be modeled as a current dipole [4, 6]. The resulting magnetic fields are positive (emerging from the brain) on one side of the neuronal source and negative (reentering the brain) on the opposite side. The neuronal source when modeled as a current dipole is located midway between the peak positive and peak negative magnetic fields (extrema). The depth of the primary source of the magnetic field is determined by the distance between the extrema [4, 6].

The three methods used for localization of neuronal activity demonstrated significant variation in the results. The direct measurement technique was difficult to reproduce because of inexact measurements for the location of the coronal slice and differences in measurements of distances on the curvature of the skull. The geometric calculation method was the least reproducible as a result of the inability to precisely transfer cranial calculated coordinates to the MR and CT images. The most reliable method was the surface marker technique. Factors limiting precise localization by this method include the size of the surface marker and potential errors in exact placement of the marker. The requirement for MEG localization prior to acquisition of the images is an additional limitation of this technique. The geometric calculation and direct skull measurement methods allow prior acquisition of the images if necessary.

The neuronal source derived from the magnetic fields is the point referenced on the CT or MR images. Localization or cortical mapping of points of neuronal activity on neurodiagnostic imaging is of potential value in many areas. These include epilepsy, coma, dementia, normal aging, mental illness, dyslexia, dominant hemisphere determination, preoperative planning, and the prognostic indications of cerebrovascular accidents and injury of the brain or spinal cord. Treatment planning for patients may also be influenced by knowledge of neuronal activity in areas of probable insult. The results of this study indicate the possibility that localization of normal and abnormal neurologic functions may require eval-

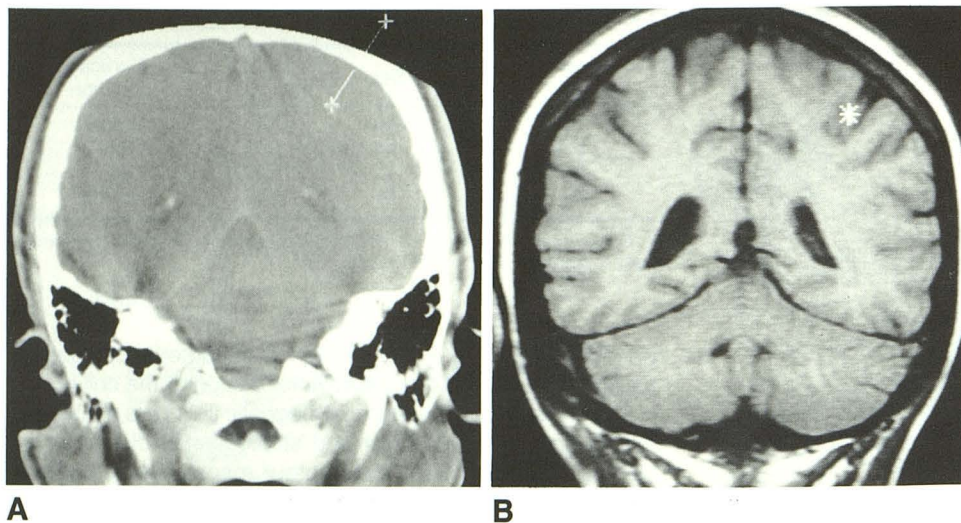


Fig. 4.—A, Coronal CT scan shows reference point determination of right index finger activity.

B, Coronal MR scan with reference point identified. Note that reference point is at inferior margin of sulcus (compare with A).

uation by both anatomic and physiologic neurodiagnostic methods.

REFERENCES

1. Williamson SJ, Romani GL, Kaufman L, Modena I, eds. *Biomagnetism: an interdisciplinary approach*. New York: Plenum, 1983:5-16, 130-132
2. Williamson SJ, Kaufman L. Biomagnetism. *J Magnetism Magnetic Materials* 1981;22:129-201
3. Erne SN, Hahlbohm HD, Lubbig H, eds. *Biomagnetism*. Berlin: de Gruyter, 1981:353-402
4. Romani GL, Williamson SJ, Kaufman L. Biomagnetic instrumentation. *Rev Sci Instr* 1982;53:1815-1845
5. Cohen D, Edelsack E, Zimmerman JE. Magnetocardiograms taken inside a shielded room with a superconducting point-contact magnetometer. *Appl Phys Letters* 1970;16:278-280
6. Grynszpan F, Geselowitz DB. Model studies of the magnetocardiogram. *Biophys J* 1973;13:911-925

The reader's attention is directed to the commentary on this article, which appears on the following pages.