



## Get Clarity On Generics

Cost-Effective CT & MRI Contrast Agents



FRESENIUS  
KABI

WATCH VIDEO

# AJNR

## **Transfemoral venous embolization of vein of Galen malformations.**

C F Dowd, V V Halbach, S L Barnwell, R T Higashida, M S Edwards and G B Hieshima

*AJNR Am J Neuroradiol* 1990, 11 (4) 643-648

<http://www.ajnr.org/content/11/4/643>

This information is current as  
of August 7, 2025.

# Transfemoral Venous Embolization of Vein of Galen Malformations

Christopher F. Dowd<sup>1</sup>  
 Van V. Halbach<sup>1,2</sup>  
 Stanley L. Barnwell<sup>1,2</sup>  
 Randall T. Higashida<sup>1,2</sup>  
 Michael S. B. Edwards<sup>2,3</sup>  
 Grant B. Hieshima<sup>1,2</sup>

Three infants with vein of Galen malformations, all presenting with congestive heart failure, underwent a total of five embolization procedures that employed a percutaneous transfemoral venous approach to catheterize the vein of Galen. In one instance, direct retrograde catheterization of feeding arterial pedicles to the vein of Galen and embolization of the fistulous connections was achieved via this route. The indications for transfemoral venous treatment included persistent symptoms despite transarterial and transthoracic embolization in one patient, an unsuccessful transarterial embolization attempt (complicated by catheter fracture) in another, and the inadvisability of transarterial embolization because of an excessive number of feeding arteries in a third. Complete obliteration of the malformation was achieved in one patient and significant flow reduction in the other two. Vein of Galen perforation with the catheter tip complicated one procedure. All three patients were stable after clinical follow-ups (9–12 months).

The transvenous route to the vein of Galen can be undertaken from a transfemoral approach, obviating surgical exposure of the torcular Herophili. In addition, we introduce the concept of direct retrograde catheterization of the feeding arteries to the vein of Galen malformation by a transfemoral venous approach, a procedure that has not been reported previously.

*AJNR* 11:643–648, July/August 1990

Vein of Galen malformations, also known as vein of Galen aneurysms, most often present in neonates as high-output congestive heart failure [1]. Even with aggressive medical therapy, the disease is uniformly fatal in this population [2–4], because the neonate succumbs to cardiac decompensation resulting from the high-flow intracerebral arteriovenous shunt. Neurosurgical clipping of the anomalous connections has offered little improvement in survival, with an 80–90% mortality [5]. Recent advances in transvascular embolization techniques have improved the prognosis in this devastating disease (Ciricillo S, unpublished data) [6, 7]. Staged embolization has become the treatment of choice to diminish arteriovenous shunting in the malformation, allowing improved cardiac function, often with the hope of more definitive therapy at a later age.

Transvascular procedures include transarterial particulate, balloon, or liquid adhesive embolization [5, 6] and direct transthoracic placement of metallic coils into the dilated vein of Galen draining the shunt [7]. We present and describe the percutaneous transfemoral venous catheterization and embolization of the vein of Galen in three patients, including direct catheterization and embolization of the feeding artery through the fistula, a method not reported previously in the treatment of vein of Galen malformations.

## Materials and Methods

Three male patients with vein of Galen malformations, all presenting with congestive heart failure during the first week of life, underwent a total of nine transvascular embolization

Received October 4, 1989; revision requested November 20, 1989; revision received December 20, 1989; accepted December 20, 1989.

<sup>1</sup>Department of Radiology, Neurointerventional Section, University of California, San Francisco, Medical Center, 505 Parnassus Ave., San Francisco, CA 94143. Address reprint requests to C. F. Dowd.

<sup>2</sup>Department of Neurological Surgery, University of California, San Francisco, Medical Center, San Francisco, CA 94143.

<sup>3</sup>Department of Pediatrics, University of California, San Francisco, Medical Center, San Francisco, CA 94143.

0195–6108/90/1104–0643  
 © American Society of Neuroradiology



procedures. The indication for treatment in all patients was to reduce the intractable cardiac failure.

Transarterial embolization was attempted in two patients. After placement of a 3-French polyethylene catheter into the vertebral artery, free particulate embolization with polyvinyl alcohol emboli (Unipoint Industries, Inc., High Point, NC) was performed (case 1). In another patient (case 2), an attempted transarterial embolization was thwarted by excessive tortuosity of the feeding arteries and was complicated by catheter fracture, necessitating surgical retrieval.

Transtorcular embolization was performed in two patients (cases 1 and 2). Surgical exposure of the torcular Herophili allowed placement of a 5-French introducer through the straight or falcine sinus to the vein of Galen. Embolization was carried out with 0.035-in. (0.089-cm) steel Gianturco coils (Cook Inc., Bloomington, IN) ranging in length from 3 to 5 cm.

Transfemoral venous catheterization and embolization of the vein of Galen was performed on four occasions (once in case 2 and three times in case 3). Under general anesthesia, the femoral vein was punctured with a 21-gauge needle, and placement of a 4- or 5-French femoral venous sheath allowed navigation of a 3.2- or 4.2-French Tracker catheter (Target Therapeutics, Mountain View, CA) through the transverse sinus, torcular Herophili, and straight or falcine sinus to the vein of Galen. Embolization agents included steel minicoils (Cook Inc.), platinum minicoils (Target Therapeutics) [8], and custom-cut segments of 4-0 silk suture (American Cyanamid Co., Danbury, CT).

Transvenous transfistula catheterization and embolization of arteries supplying the vein of Galen malformation was accomplished on one occasion. A percutaneously placed 5-French femoral venous sheath allowed navigation of a 4.2-French Tracker 25 catheter through the torcular Herophili and vein of Galen into feeding pericallosal and perforating arteries in a retrograde fashion. Embolization was performed with steel minicoils (Cook Inc.).

In the transvenous or transtorcular procedures, progress of embolization was monitored with real-time digital subtraction angiography (Diasonics, Salt Lake City, UT) via an arterial catheter. Control angiograms were obtained after all procedures. The clinical follow-up periods ranged from 9 to 12 months.

## Results

Control angiograms showed complete angiographic cure in one patient (case 2) and significant reduction of arteriovenous shunting in two (cases 1 and 3).

The three patients underwent a total of five percutaneous transfemoral venous embolization procedures with platinum or steel coils. In two patients (cases 2 and 3), coils were placed into the dilated vein of Galen. In the third patient (case 1), transvenous retrograde catheterization of two large arteriovenous fistulas was accomplished in one sitting, and embolization was carried out with multiple steel minicoils.

One complication was encountered when using the transfemoral venous approach (case 3). Perforation of the vein of Galen into the right lateral ventricle during catheter navigation was closed with a single steel minicoil and resulted in hydrocephalus, for which a ventriculoperitoneal shunt was required 2 weeks later.

## Case Reports

### Case 1

A 2-day-old boy developed intractable high-output congestive heart failure. A CT scan of the brain documented a vein of Galen malfor-

mation, confirmed by cerebral angiography, which revealed arteriovenous shunts of varying sizes supplied by thalamoperforating, choroidal, and pericallosal arteries draining to the dilated vein of Galen and then to a falcine sinus (Figs. 1A and 1B). Particulate embolization with polyvinyl alcohol particles was performed through the left vertebral artery on day 8 of life, with some reduction in arteriovenous shunting and improved cardiac function. Two weeks later, severe heart failure recurred. Surgical exposure and direct puncture of the torcular Herophili was followed by embolization with steel Gianturco coils into the varix. This further reduced arteriovenous shunting through the malformation, allowing cardiac function to stabilize. At age 2 years 2 months, the child's cardiac status remained stable, but he displayed significant language delay and mild spastic quadriplegia. He was referred for further embolization. After control carotid (Fig. 1C) and vertebral angiography were performed, a 5-French sheath was placed into the femoral vein, and a Tracker 25 catheter was navigated through the right transverse sinus, falcine sinus, vein of Galen, and retrograde through one of the arteriovenous fistulas into an enlarged pericallosal artery feeding the malformation (Figs. 1D and 1E). Embolization was carried out with multiple steel minicoils. The Tracker catheter was repositioned into a large thalamoperforating artery. Embolization was performed in the same manner. Postprocedure control carotid and vertebral angiograms showed markedly diminished flow through the malformation (Figs. 1F and 1G). Twelve months later, the child still had stable heart function, language delay, and mild spastic quadriplegia.

### Case 2

A full-term male infant developed severe congestive heart failure on the first day of life. A loud cranial bruit led to the CT diagnosis of a vein of Galen malformation. On day 8 of life, diagnostic angiography confirmed the presence of a vein of Galen malformation (Figs. 2A and 2B). Attempted transarterial catheterization of one of the posterior choroidal feeding arteries was thwarted by excessive tortuosity of the proximal feeding arteries. Manipulation of the catheter resulted in its fracture in the femoral artery, requiring surgical retrieval. One week later, direct surgical exposure of the torcular Herophili allowed direct puncture and embolization of the vein of Galen with Gianturco coils, with considerable reduction in arteriovenous shunting (Fig. 2C). One coil was thought to have perforated the varix. No extravasation of contrast material or pseudoaneurysm was demonstrated on control angiography immediately after this event, but a small thalamic hemorrhage was documented on cerebral sonography and CT scanning. When the cardiac status was stable at 6 months of age, the patient returned for further therapy to reduce the risk of neurologic injury from the malformation (Fig. 2D). A 4-French sheath was introduced into the femoral vein. Through this, a 3.2-French Tracker 0.018-in. (0.046-cm) catheter with a 12-cm distal segment was navigated to the vein of Galen (Fig. 2E). Embolic agents included 12 1.0-cm platinum coils and 20 cut pieces of 4-0 silk suture 1.0–2.5 cm in length. Postembolization control angiograms revealed no residual arteriovenous shunting through the malformation (Fig. 2F). The immediate postoperative course was complicated by fever of unknown source that lasted for several days and resolved without therapy. A possible cause was the use of silk suture to promote thrombosis. Also, increased asymptomatic hydrocephalus was noted on a follow-up CT scan; this may have been due to the mass effect of the coils in the vein of Galen. The patient was still well 9 months after this procedure, and was being monitored for regression or symptomatic hydrocephalus.

### Case 3

Development of severe congestive heart failure and auscultation of a cranial bruit on the first day of life led to the sonographic and CT



Fig. 1.—Case 1.

A, Left vertebral artery injection, anteroposterior projection, shows high-flow vein of Galen malformation supplied by thalamoperforating and posterior choroidal arteries.

B, Right common carotid artery injection, lateral projection, shows supply to vein of Galen malformation from pericallosal arteries (*straight arrow*), and perforating and posterior choroidal arteries via posterior communicating artery (*solid curved arrow*). Venous drainage is by way of falcine sinus (*open arrow*).

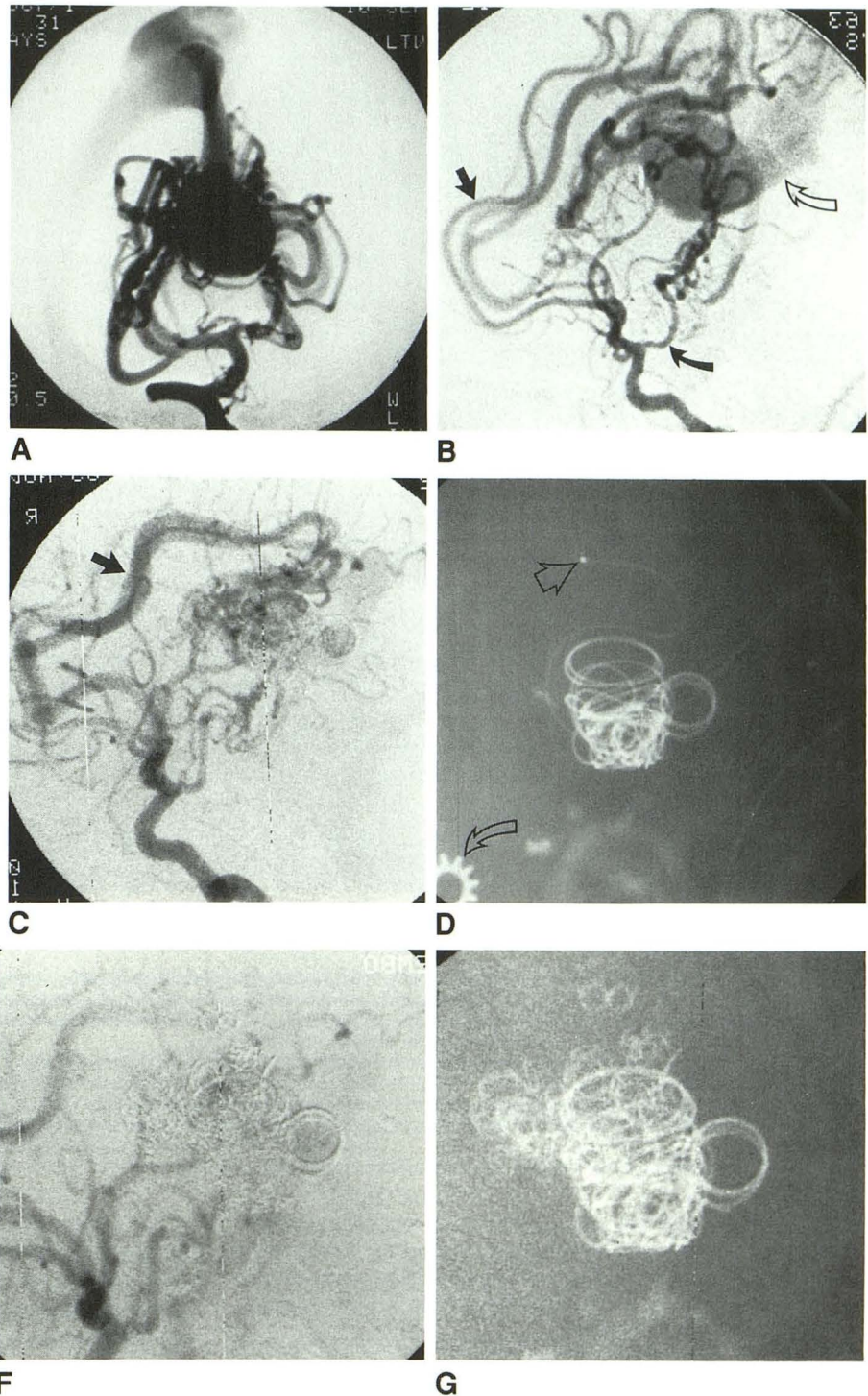
C, Right common carotid artery injection, lateral projection, 2 years later, after particulate and transthoracic coil embolization reveals diminished but persistent arteriovenous shunting through malformation, now supplied predominantly by pericallosal arteries (*arrow*).

D, Plain skull film, lateral projection, shows transfemorally placed Tracker catheter traversing falcine sinus, vein of Galen, and retrograde through fistula site, with tip in pericallosal feeding artery (*straight arrow*) in preparation for coil embolization. Platinum coils were placed during prior embolization. (Note 1-cm sizing washer [*curved arrow*] taped to side of patient's head to measure diameter of vessels for proper coil selection.)

E, Lateral projection, distal pericallosal artery injection via venous Tracker catheter placed retrograde across fistula site into feeding artery. Catheter was withdrawn to a more distal location in the feeding artery (at fistula site) prior to coil embolization.

F, Right common carotid artery injection, lateral projection, after steel coil embolization of two fistula sites and vein of Galen. Faint opacification of vein of Galen is present, with markedly diminished arteriovenous shunting compared with preprocedure angiograms.

G, Plain skull film, lateral projection, shows final appearance of morass of steel (faintly radiopaque) and platinum (strongly radiopaque) coil emboli in vein of Galen and feeding arteries.



diagnosis of a vein of Galen malformation. On day 8 of life, diagnostic angiography (Fig. 3A) was followed by transfemoral venous catheterization and embolization of the vein of Galen with steel minicoils (Fig. 3B), reducing the arteriovenous shunt. The procedure was complicated by catheter perforation of the vein of Galen into the right lateral ventricle. Immediate closure of the perforation site was achieved by placement of a single steel minicoil across the perforation site while withdrawing the catheter back into the vein of Galen. Forty additional Gianturco coils were deposited in the vein of Galen, resulting in diminished flow. A CT scan (Fig. 3C) after the procedure documented

hydrocephalus, which was monitored closely sonographically and clinically. Diagnostic angiography 3 days later demonstrated no pseudoaneurysm or contrast extravasation at the perforation site. Owing to persistent heart failure, a second embolization procedure was performed on day 15 of life, with transfemoral transvenous catheterization of the vein of Galen allowing embolization with 16 platinum coils of 1.0- to 2.5-cm lengths and 40 4-0 silk suture segments (Fig. 3D). This embolization procedure was repeated the following day with additional placement of coils due to persistent heart failure, which then abated. Mild residual arteriovenous shunting through the



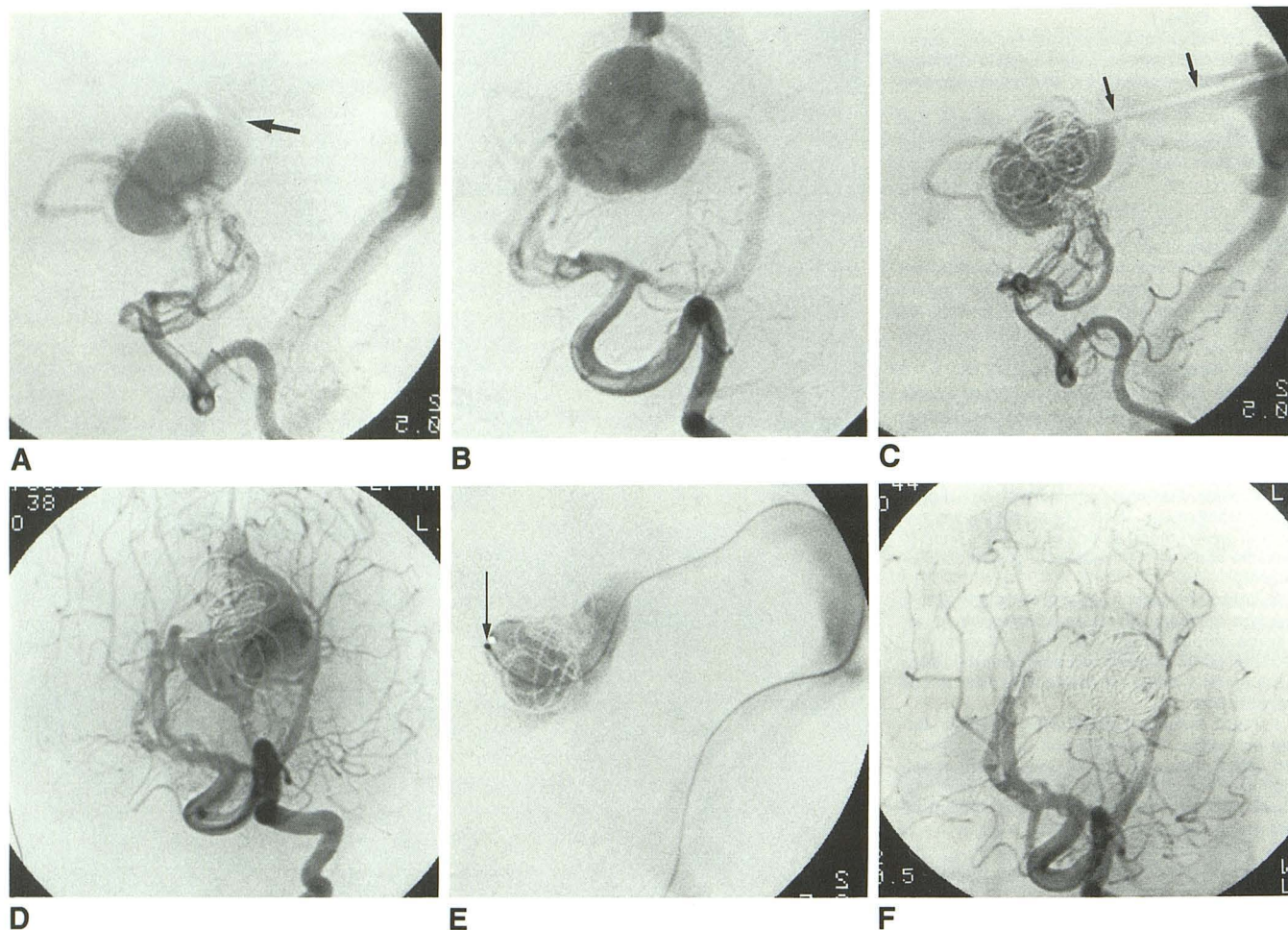


Fig. 2.—Case 2.

A and B, Left vertebral artery injections, lateral (A) and Towne's (B) projections, show posterior choroidal arterial supply to vein of Galen malformation prior to treatment. Abrupt angulation (arrow) at junction of vein of Galen and falcine sinus can hinder retrograde catheterization.

C, Left vertebral artery injection, lateral projection, reveals residual arteriovenous shunting through malformation after transthoracic placement of Gianturco coils. Note outline of 5-French catheter within falcine sinus (arrows).

D, Left vertebral artery injection, Towne's projection, 6 months later shows diminished but persistent arteriovenous shunting through malformation.

E, Vein of Galen injection, lateral projection, through Tracker catheter navigated retrograde through femoral vein and falcine sinus. Catheter tip (arrow) is at anterior aspect of vein of Galen in preparation for transvenous embolization with platinum coil and silk suture.

F, Left vertebral artery injection, Towne's projection, immediately after transfemoral venous embolization, reveals no residual flow through vein of Galen malformation.

malformation persisted (Fig. 3E). Increasing hydrocephalus required placement of a ventriculoperitoneal shunt 1 week later. The patient had complete clinical resolution of signs of heart failure, was without a cranial bruit or hydrocephalus, and had a normal head circumference 9 months after the last procedure.

## Discussion

Because of the extremely high mortality associated with vein of Galen malformations that present in the neonate, which often lead to cardiac failure and then death, it is critical to develop new methods of treatment to diminish arteriovenous shunting. Although transvascular embolization techniques have altered the otherwise dismal prognosis in this disease, these techniques have drawbacks.

The transthoracic approach requires a craniotomy for access to the straight or falcine sinus [7]. Complications of this technique include perforation of the vein of Galen by the embolization coil or catheter tip and perforation of the torcular Herophili or sinus by the puncture needle, which has resulted in fatal subarachnoid hemorrhage [9]. In our case 2, the small thalamic hemorrhage may have resulted from apposition of the stiff 5-French introducer and the thin wall of the dilated varix during coil insertion. Also, there is a high rate of anomalous venous drainage of the vein of Galen in the form of a falcine sinus. The presence of this variation coincident with the often present abrupt angle formed at the posterior aspect of the vein of Galen and proximal draining sinus hinders the ability to catheterize the vein of Galen from a transthoracic route. Advantages of the transthoracic approach include the



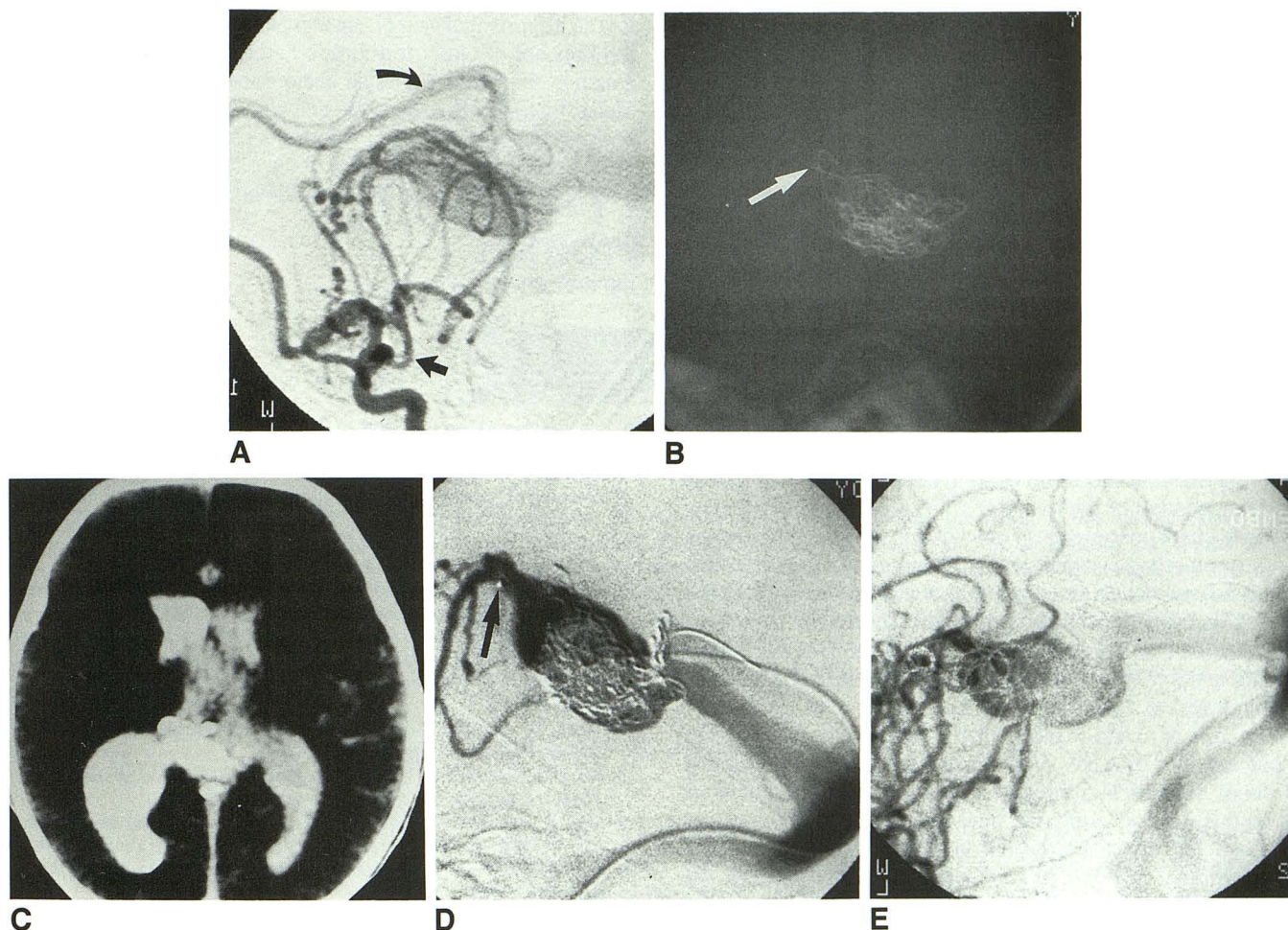


Fig. 3.—Case 3.

A, Left internal carotid artery injection, lateral projection, prior to treatment. Vein of Galen malformation is supplied by thalamoperforating and posterior choroidal arteries via posterior communicating artery (*straight arrow*) and by pericallosal artery (*curved arrow*).

B, Plain skull film, lateral projection, after transfemoral venous embolization of vein of Galen with steel coils. Coil at anterosuperior aspect of vein of Galen (*arrow*) is placed across site of vein perforation.

C, CT scan, transaxial projection, after first transfemoral venous embolization. Vein of Galen perforation by catheter tip has resulted in extravasation of contrast material into lateral ventricles and hydrocephalus.

D, Vein of Galen injection, lateral projection, through Tracker catheter placed via femoral vein. Midembolization control venogram during second embolization procedure shows catheter tip at fistula site at anterosuperior aspect of vein of Galen (*arrow*), with reflux of contrast material into feeding arteries. Note catheter course through smaller companion vein that runs parallel to straight sinus.

E, Left common carotid injection, lateral projection, after third and final transfemoral venous embolization, shows diminished but residual arteriovenous shunting through malformation.

ability to use larger coil emboli and to exert more torque control with the catheter.

Transarterial particulate embolization requires navigation of catheters through very small vessels in infants, which may preclude adequate distal catheter tip position for treatment. This method also risks embolization of normal cerebral arteries, proximal occlusion of feeding arteries by larger particles, wash-through of smaller particles, and recanalization of embolized vessels. The risk of embolization of normal arteries increases if nonselective free particulate embolization is undertaken [5].

The concept of transfemoral transvenous embolization has been applied in the treatment of indirect (dural) carotid-cavernous fistulas [10] and dural arteriovenous fistulas [11]. Our

technique involves placement of a sheath into the femoral vein, followed by navigation of a smaller catheter through the torcular Herophili to the vein of Galen. If the anomaly is a true vein of Galen malformation with direct shunting to the varix, coil embolization may be performed. This procedure would be precluded in cases in which dilatation of the vein of Galen resulted from an arteriovenous malformation elsewhere in the brain [12].

Retrograde catheterization through an arteriovenous fistula into the feeding arteries is possible as an extension of this technique. Direct localization of the catheter tip at the fistula site allows controlled coil embolization of the fistula itself, rather than relying on thrombosis within the varix immediately distal to the fistula site(s). This method also diminishes the



possibility of development of hydrocephalus from mechanical compression of the aqueduct by a mass of coil emboli in the vein of Galen.

The most feared complication in using the transfemoral venous approach is perforation of the wall of the vein of Galen, as occurred in case 3. Factors that increase this risk include extreme fragility of the thin, dilated vein of Galen, relative stiffness of the catheter or coil embolus, and failure to avoid direct apposition of catheter tip and varix wall at the moment of coil exit. Development of more pliable catheters with softer tips, and softer coils, perhaps with floppy ends or made of plastic, may decrease this risk of perforation.

It is essential to recognize such a perforation immediately. If perforation of the vein of Galen or another vascular structure is suspected, the catheter should *not* be withdrawn, as it may function to tamponade the perforation site. A tiny amount of contrast material should be used to document the perforation and the location of the catheter tip. If a perforation is found, reversal of anticoagulation (if used during the procedure) must be accomplished without delay. Closure of the perforation site is achieved with long coils that are positioned across the site as well as immediately outside and inside the punctured vessel. Documentation of lack of further extravasation or a pseudoaneurysm is made angiographically, once the catheter is withdrawn to an intravascular location.

The vein of Galen malformation is a spectrum disease. In those supplied by a few large fistulas, the treatment of choice is direct subselective transarterial embolization of the arteriovenous connections. This may be difficult in the neonate because the small arterial caliber may preclude adequate distal catheter position. In such circumstances, or when the malformation is supplied by many smaller feeders, a transvenous route should be used. If the arteriovenous connections are large enough, direct retrograde catheterization and embolization of the feeding arteries may be achieved by a transvenous route, as occurred in case 1.

We have described three patients who underwent five transvenous embolization procedures via femoral vein access

for the treatment of vein of Galen malformations. We introduce the concept of direct retrograde catheterization and embolization of the feeding arteries using this approach. Long-term clinical follow-up to assess the efficacy of transfemoral venous occlusion of vein of Galen malformations is still required. With more experience, a better idea of the effectiveness and drawbacks of this technique will be obtained.

## REFERENCES

1. Gold AP, Ransohoff J, Carter S. Vein of Galen malformation. *Acta Neurol Scand Suppl* 1964;40[II]:5-31
2. Hoffman HJ, Chuang S, Hendrick EB, Humphreys RP. Aneurysms of the vein of Galen. Experience at the Hospital for Sick Children, Toronto. *J Neurosurg* 1982;57:316-322
3. Johnston IH, Whittle IR, Besser M, Morgan MK. Vein of Galen malformation: diagnosis and management. *Neurosurgery* 1987;20:747-758
4. Amacher AL, Shillito J. The syndromes and surgical treatment of aneurysms of the great vein of Galen. *J Neurosurg* 1973;39:89-98
5. Edwards MSB, Hieshima G, Higashida R, Halbach V. Management of vein of Galen malformations in the neonate. *Int Pediatr* 1988;3:184-188
6. Berenstein A, Epstein F. Vein of Galen malformations: combined neurosurgical and neuroradiological intervention. In: McLaurin RL, Schut L, Venes JL, et al., eds. *Pediatric neurosurgery*. New York: Grune & Stratton 1982:637-647
7. Mickle JP, Quisling RG. The transthoracic embolization of vein of Galen aneurysms. *J Neurosurg* 1986;64:731-735
8. Yang PJ, Halbach VV, Higashida RT, Hieshima GB. Platinum wire: a new transvascular embolization agent. *AJNR* 1988;9:547-550
9. Goto K. Complication of the transthoracic approach in the treatment of vein of Galen malformations. Presented at the annual meeting of the working group in interventional neuroradiology, Val d'Isere, France, January 1989
10. Halbach VV, Higashida RT, Hieshima GB, Hardin CW, Pribam H. Transvenous embolization of dural fistulas involving the cavernous sinus. *AJNR* 1989;10:377-383
11. Halbach VV, Higashida RT, Hieshima GB, Mehringer CM, Hardin CW. Transvenous embolization of dural fistulas involving the transverse and sigmoid sinuses. *AJNR* 1989;10:385-392
12. Lasjaunias P, Rodesch G, Pruvost P, Laroche FG, Landrieu P. Treatment of vein of Galen aneurysmal malformation. *J Neurosurg* 1989;70:746-750