



Get Clarity On Generics

Cost-Effective CT & MRI Contrast Agents



FRESENIUS
KABI

WATCH VIDEO

AJNR

Facial skeleton remodeling due to temporomandibular joint degeneration: an imaging study of 100 patients.

K P Schellhas, M A Piper and M R Omlie

AJNR Am J Neuroradiol 1990, 11 (3) 541-551

<http://www.ajnr.org/content/11/3/541>

This information is current as
of August 13, 2025.

Facial Skeleton Remodeling Due to Temporomandibular Joint Degeneration: An Imaging Study of 100 Patients

Kurt P. Schellhas¹
Mark A. Piper²
Mark R. Omlie³

One hundred patients with recently acquired, externally visible mandibular deformity and no history of previous extraarticular mandible fracture were selected for retrospective analysis. All had been investigated clinically and with radiography, tomography, and high-field surface-coil MR imaging to determine the presence or absence and extent of temporomandibular joint degeneration. Temporomandibular joint degeneration was found in either one or both joints of each patient studied. Chin deviation was always toward the smaller mandibular condyle or more diseased joint, and many patients either complained of or exhibited malocclusion, often manifested by unstable or fluctuating occlusion disturbances. Three radiologically distinct forms of degenerative vs adaptive osteocartilaginous processes—(1) osteoarthritis, (2) avascular necrosis, and (3) regressive remodeling—involving the mandibular condyle and temporal bone were identified in joints most often exhibiting meniscus derangement. Osteoarthritis and avascular necrosis of the mandibular condyle and temporal bone were generally associated with pain, mechanical joint symptoms, and occlusion disturbances. Regressive remodeling was less frequently associated with occlusion disturbances, despite remodeling of the facial skeleton, and appears to result from regional osteoporosis. Forty patients (52 joints) underwent open arthroplasty procedures, including either meniscectomy or micro-surgical meniscus repair, at which time major radiologic diagnoses were confirmed. Surgical and pathologic findings included meniscus displacement, disk degeneration, synovitis, joint effusion, articular cartilage erosion, cartilage healing/fibrosis, cartilage hypertrophy, osseous sclerosis, osteophyte formation, osteochondritis dissecans, localized or extensive avascular necrosis, and decreased mandibular condyle mass and vertical dimension.

We conclude that temporomandibular joint degeneration is the principal cause of both acquired facial skeleton remodeling and unstable occlusion in patients with intact dentition and without previous mandible fracture.

AJNR 11:541-551, May/June 1990; *AJR* 155: August 1990

Received August 22, 1989; revision requested October 16, 1989; revision received November 7, 1989; accepted November 13, 1989.

Presented at the annual meeting of the American Society of Neuroradiology, Orlando, FL, March 1989. Presented in part at the annual meeting of the American Association of Oral and Maxillofacial Surgeons, San Francisco, September 1989.

¹ Center for Diagnostic Imaging, 5775 Wayzata Blvd., Suite 190, St. Louis Park, MN 55416. Address reprint requests to K. P. Schellhas.

² 111 Second Ave. N.E., Suite 1006, St. Petersburg, FL 33701.

³ 250 Central Ave. N., Wayzata, MN 55391.

0195-6108/90/1103-0541
© American Society of Neuroradiology

Disorders of occlusion and acquired facial skeleton deformity are common, yet the pathogenesis of these problems is generally not well understood. The relationship between mechanical temporomandibular joint (TMJ) symptoms, acquired mandibular deformity, and disturbances of occlusion has long been and continues to be a subject of controversy [1-11]. Recent clinical and laboratory investigations with MR imaging have defined TMJ pathology [12-19] and the relationship between joint degeneration and secondary manifestations, such as mechanical TMJ symptoms [5], pain [5, 20-22], facial skeleton deformity [21, 23, 24], and malocclusion [2, 4, 5, 21-24]. We analyzed the historical, clinical, and radiologic findings in patients whose primary complaints related to facial deformity and/or deranged occlusion, correlated this data with surgical and pathologic observations, and identified three degenerative/adaptive osteocartilaginous processes that cause predictable changes in the facial skeleton.

Materials and Methods

One hundred patients (86 females and 14 males, 11–69 years old) who had presented with acquired, externally visible facial-mandibular deformity and/or acquired (especially unstable) malocclusion and subsequently underwent radiologic investigation with radiography, tomography, and surface-coil MR were selected for retrospective study. Patients with either history or radiologic evidence of mandibular-facial fractures (other than articular surface fractures of the mandibular condyle) and secondary deformity/malocclusion were excluded from the study. Patients with a history of previous orthognathic surgery were excluded from the series, as were individuals with lifelong histories of facial deformity and/or anomalies of development. Many patients complained of acquired unsatisfactory facial contour, such as chin deviation to one side, with or without chin retrusion; poor occlusion between the upper and lower teeth; and jaw deviation toward one side with mouth opening. Occlusal problems included anterior open bite, posterior open bite, crossbite, and fluctuating symptoms such as episodic posterior open bite and/or crossbite. Occlusion-related complaints were more common than complaints about facial contour, as many patients (with mild mandibular asymmetry) were not initially aware of facial changes. Over one-half of the patients in the series either had a previous history of occlusal adjustment with dental braces or were undergoing orthodontic treatment at the time of the study. Accompanying clinical complaints at the time of initial evaluation included mechanical TMJ symptoms such as TMJ clicking, locking, asymmetric jaw motion, masticatory dysfunction, tinnitus, decreased and/or altered hearing, headache, facial pain, otalgia, and neck pain. Many patients had no mechanical TMJ symptoms. Patients were examined for abnormalities of dentition, such as loose or missing teeth, periodontal disease, and obvious caries.

Patients were routinely screened with radiography, including submentovertex and anteroposterior jaw-protruded radiographs of the skull and mandible. These were followed by closed- and open-mouth, cephalometrically corrected (obtained perpendicular to long axis of mandibular condyle) lateral TMJ tomograms, most often employing a routine of three closed-mouth views at 2- to 3-mm intervals between

the medial and lateral poles of the mandibular condyle, followed by a single, midcondyle open-mouth view. Lateral facial radiographs were obtained in each case. After screening radiographs and tomograms, patients were studied with surface-coil MR using a 1.5-T superconducting magnet (General Electric, Milwaukee, WI) and either a commercially available single or dual 3-in. (7.6-cm) surface-coil apparatus at one of two facilities in different states. Details of both single- and dual-coil MR technical parameters have been described previously [16, 18, 21, 22]. Acquisition details for T1- and T2-weighted images illustrated in this article are identified in the figure legends by TR/TE (e.g., 500/20 and 2200/80). The presence or absence of abnormality and stage [5, 24] of TMJ derangement were noted in each case. Joint effusions and alterations of mandibular condyle morphology and marrow signal were noted in each case [22].

Results

Clinical observation revealed either asymmetry or retrusion of the chin point in each patient (Figs. 1 and 2). Complaints related to occlusion such as crossbite, anterior open bite, and prematurity of posterior molar contact were confirmed with physical examination in each case (Figs. 1–3). Radiographic and tomographic findings were abnormal in each patient (Figs. 4 and 5). Radiographic observations included side-to-side asymmetry in mandibular condyle size, morphology, and orientation to the skull base; chin displacement to one side; chin retrusion; loss of posterior mandibular and facial height; and morphologic deformity of either one or both mandibular condyles (Figs. 1, 4, and 5) [2, 4, 21, 23, 24]. Chin deviation toward the smaller and/or more deformed mandibular condyle was present in each case [2, 4, 23]. In cases of unilateral condylar hypertrophy and prognathism, chin displacement was toward the smaller (normal or abnormal) opposite joint.

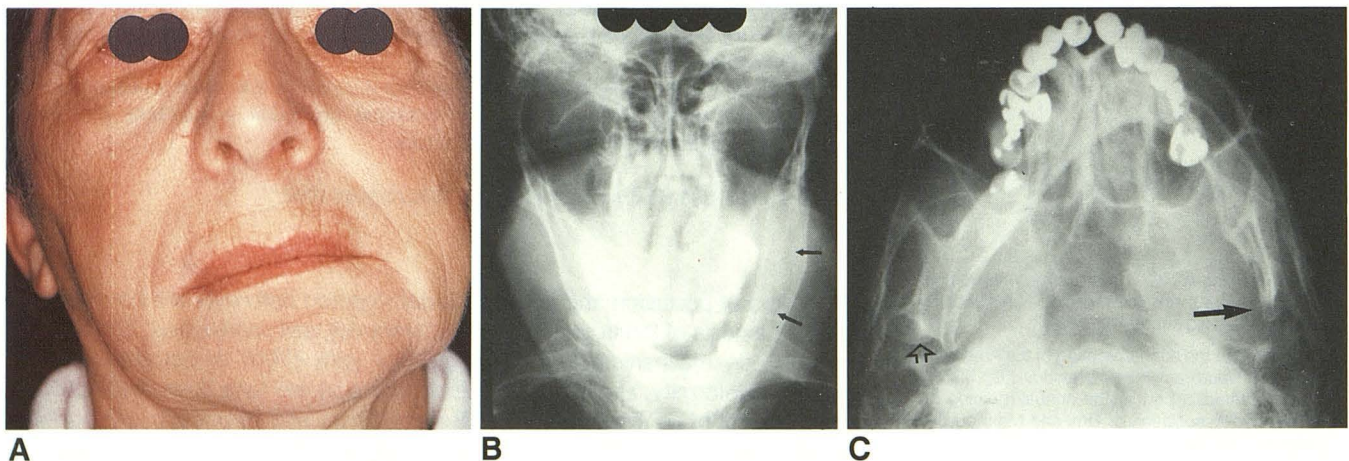


Fig. 1.—Acquired skeletofacial deformity due to advanced degeneration of left temporomandibular joint in 65-year-old woman with 6-year history of progressive chin displacement, left-sided preauricular pain, and restricted temporomandibular joint function.

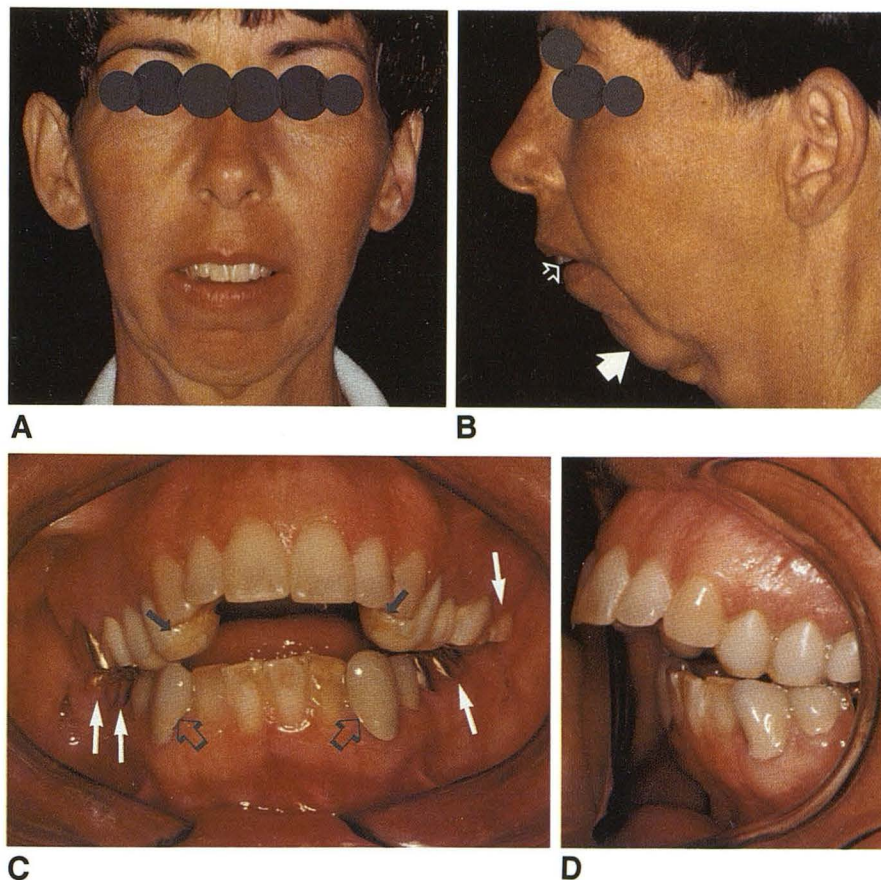
A, Frontal photograph of patient in centric (most comfortable state) occlusion reveals chin displacement toward left with tilting of lips.

B and C, Anteroposterior, jaw-protruded (B) and closed-mouth submentovertex (C) radiographs reveal chin displacement toward left, due to degeneration of left mandibular condyle (solid arrow, C). Note absent left-sided mandibular molars (arrows, B), further accentuating skeletofacial deformity. Open arrow points to normal right mandibular condyle. Lateral tomograms and MR (not shown) revealed severe condyle degeneration, suggesting old avascular necrosis and secondary osteoarthritis.

Fig. 2.—Progressive retrognathia and worsening anterior open bite owing to bilateral avascular necrosis of mandibular condyles in 42-year-old woman with 5-year history of progressive skeletofacial deformity (A and B) and worsening malocclusion and bilateral temporomandibular joint pain and dysfunction (C and D).

A and B, Frontal and lateral closed-mouth photographs reveal lip incompetence due to severe anterior open bite and mandibular recession (open arrow, B). Note retrusion of chin (solid arrow, B) and decreased posterior facial height.

C and D, Anterior and lateral dental photographs reveal large occlusal surface onlays (solid black arrows), porcelain crowns (open arrows), and marked intrusion of posterior molars and molar crowns (white arrows) due to progressive loss of posterior facial height.



Lateral tomographic findings included normal unilateral osseous anatomy and alterations in mandibular condyle size, height, morphology, and position within the glenoid fossa, including both articular space narrowing (osteoarthritis) and pathologic articular space widening (avascular necrosis [AVN] and regressive remodeling) (Figs. 4 and 5) [24]. Osseous sclerosis, cortical thickening, osteophyte formation, unilateral and bilateral loss of condylar mass and vertical dimension, and facial and generalized articular surface depressions were noted (Fig. 5). Three patients (five joints) with a history of pain, mechanical TMJ symptoms, progressive retrognathia, open bite, and loss of posterior mandible exhibited absence of the condyle and (either most or all) of the condylar neck (proximal mandibular segment), suggesting that AVN had led to osseous collapse and resorption (condylolysis) (Fig. 1). Decreased range of forward condylar translation was commonly observed.

MR findings included side-to-side asymmetry in condyle size and morphology (Fig. 6A); occasional normal joint anatomy (Fig. 6B); early to late stages of TMJ meniscus derangement (Figs. 6C, 6D, and 7) [5, 24]; joint effusion (Figs. 6C, 6D, and 7–9); alterations in mandibular condyle size, morphology, and marrow signal characteristics suggesting regional osteoporosis (Figs. 5, 7, and 8); articular (transchondral) fracture or osteochondritis dissecans (Fig. 9); osteoarthritis (Fig. 10); and either localized or extensive (entire con-

dyle and/or condylar neck) AVN (Figs. 11 and 12) [21, 24, 25]. Five joints with morphologic changes suggesting regressive remodeling exhibited increased marrow signal on T2-weighted images (Figs. 5, 7, and 8). Side-to-side skeletal variations and deformities were best delineated on conventional radiographs (Figs. 1 and 4). Side-to-side masticatory muscle asymmetry was noted on MR studies in cases of clinically obvious craniomandibular deformity [26]. Ten joints exhibited severe structural alterations that made it impossible to distinguish old AVN from osteoarthritis, suggesting that both processes may have occurred in these joints (Figs. 1, 3, and 10).

Surgical observations from 40 patients (52 joints) operated on for bothersome mechanical TMJ symptoms, pain, and radiologically demonstrated joint derangement believed to be responsible for progressive facial deformity and/or occlusal disturbance confirmed major radiologic diagnoses such as disease stage in each instance. Joints exhibiting radiographic-tomographic and MR findings suggesting osteoarthritis were uniformly found to have severely displaced and degenerated disks, with or without synovitis and joint effusion (Fig. 10). Perforation of the meniscus attachments (most often posterior) was encountered in each case of suspected osteoarthritis. Erosion of mandibular condyle and/or temporal bone articular cartilage was commonly observed, with or without evidence of cartilaginous healing and fibrosis. Small foci of

osteocondritis dissecans and osteophytes along articular surface margins were observed occasionally when these findings were not apparent on imaging studies, particularly when operative microscopy (magnification, $\times 10$) was used. Joints exhibiting radiologic characteristics suggesting either osteocondritis dissecans or AVN manifested variable condylar

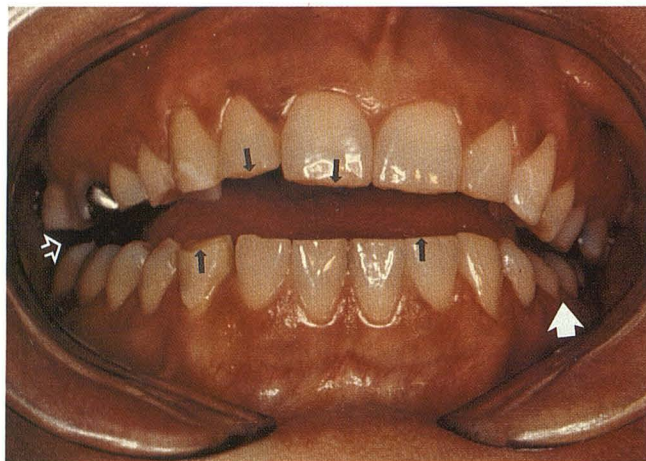

Fig. 3.—Rapidly progressive, asymmetric anterior open bite and right-sided posterior open bite (open arrow) with premature contact of posterior molars on left due to destruction of left condyle resulting in loss of posterior mandible height caused by permanent Proplast implant in a 30-year-old woman with progressive malocclusion, left temporomandibular joint pain, and worsening mechanical symptoms. Severe occlusal wear (black arrows), due to chronic bruxism, indicates prior occlusal contact. Note intrusion of left posterior molars (solid white arrow) compared with right side.

articular surface abnormalities, such as cartilage erosion, often with articular surface depression, with or without evidence of osteocartilaginous healing (Fig. 11) [21]. Joints that contained permanent alloplastic implants (especially Proplast, Vitek, Houston) and exhibited destructive soft-tissue and osseous changes uniformly contained foreign body-type granulomata (Fig. 3) [23]. Histologic study of removed osseous fragments revealed findings compatible with either osteocondritis dissecans or AVN. Core decompression of selected diseased condyles revealed areas of normal-appearing marrow, and areas of either bone softening or sclerosis with complete lack of bleeding in focal areas, proved to represent various stages of AVN at histology. Advanced stages of meniscus derangement, usually with perforation, were encountered in all cases of osteocondritis dissecans and AVN. Cases in which condylar "regressive remodeling" was diagnosed on imaging studies typically exhibited advanced-stage disk derangement, with or without perforation, with either intact or hypertrophic articular surface cartilage (Figs. 4–7) [24]. No hypertrophic osteophytes were seen in these cases.

Discussion

Mandibular and facial fractures are obvious causes of acquired facial deformity and malocclusion [27]. Destructive complications of TMJ arthroplasty with permanent implants are known to result in acquired facial deformities and unstable occlusions [23]. Loose and missing teeth will accentuate skeletal deformity and often aggravate symptoms in diseased TMJs (Fig. 1) [3]. In 1966, Boering [1] described "arthrosis

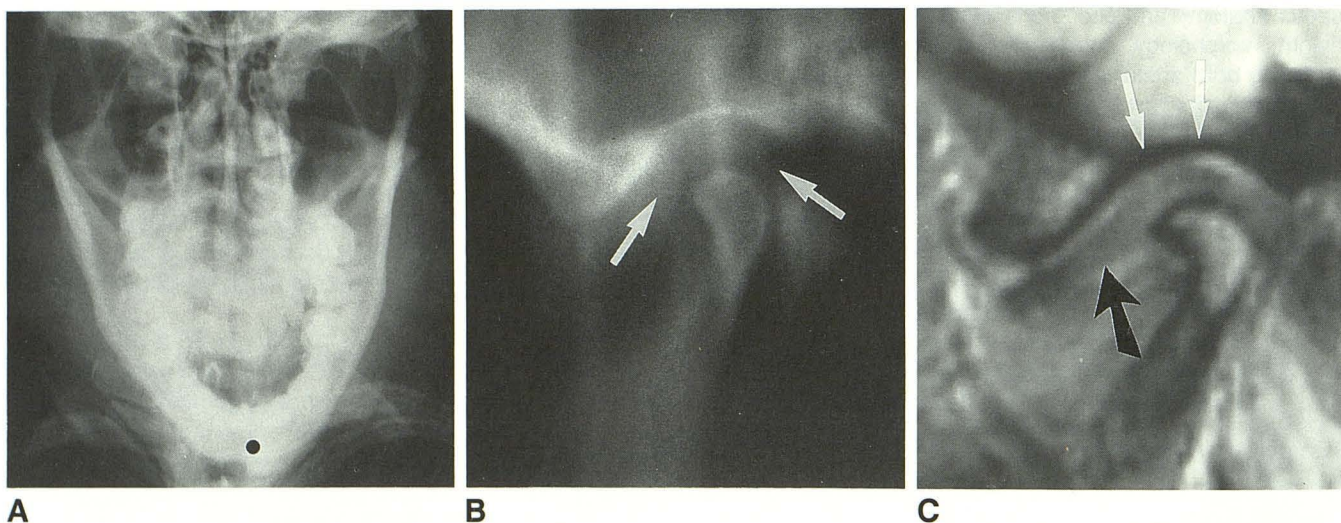


Fig. 4.—Regressive remodeling of left mandibular condyle causing slowly progressive skeletofacial deformity in a 33-year-old woman with 4-year history of episodic temporomandibular joint (TMJ) clicking, recently progressed to locking and episodic preauricular pain. Skeletal occlusion was stable at clinical evaluation, although intruded left posterior molars were found.

A, Open-mouth jaw-protruded frontal radiograph reveals chin (dot) displacement toward degenerated left TMJ.

B, Closed-mouth lateral TMJ tomogram (obtained with patient in centric occlusion) reveals pathologic widening of articular space, now occupied by articular cartilage and retrodiskal soft tissues, (arrows) with small mandibular condyle.

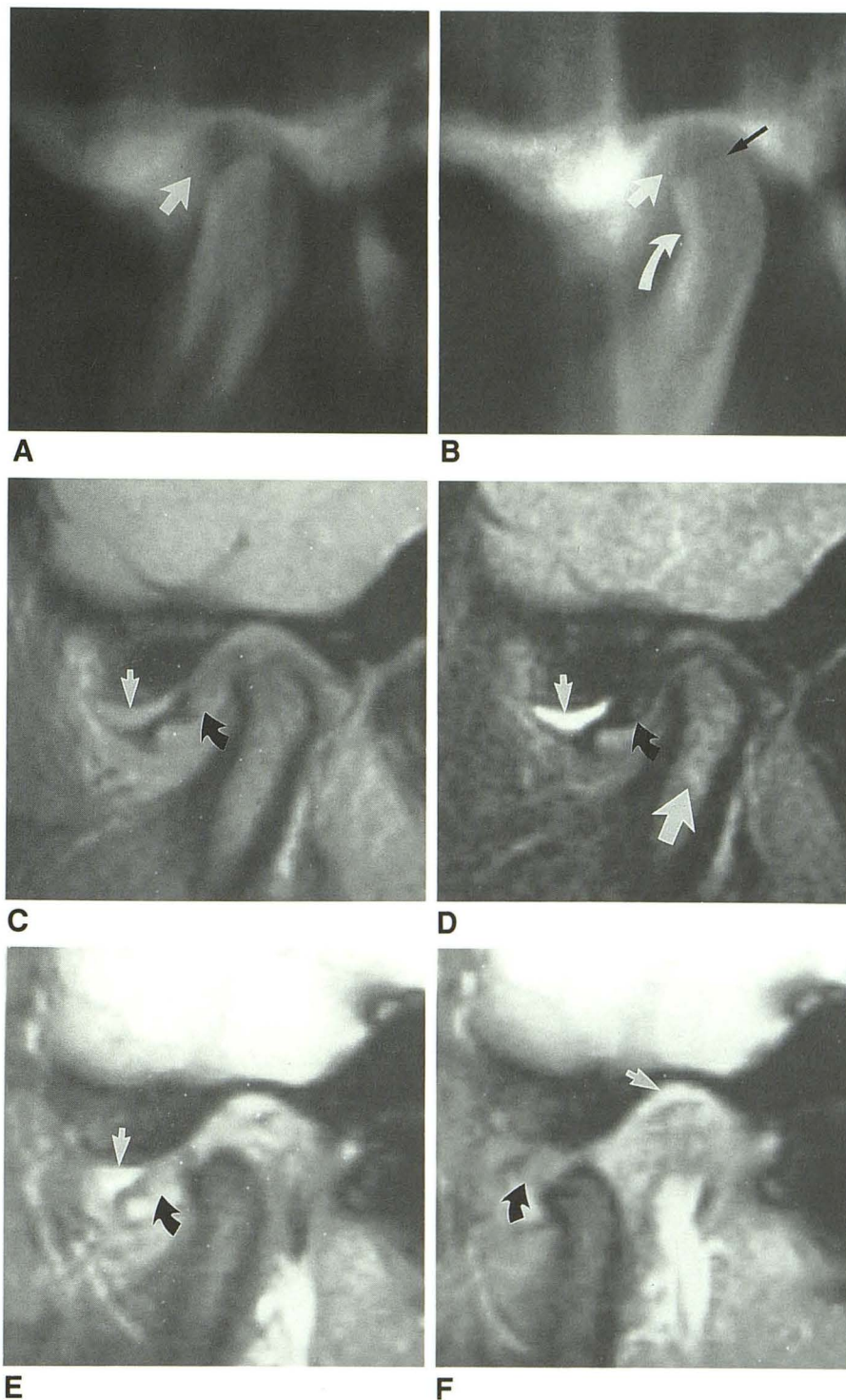
C, Closed-mouth sagittal 3-mm-thick MR image, 2200/25, reveals normal condylar marrow signal with anterior displacement and degeneration of meniscus (black arrow), nonreducing on open-mouth views (not shown). Note apparent osseous thickening, surgically proved to represent hypertrophic cartilage along articular surface of temporal bone superiorly (white arrows). Meniscus derangement and articular cartilaginous hypertrophy on both temporal bone and mandibular condyle were confirmed during meniscectomy.

Fig. 5.—Progressive loss of condylar mass and vertical dimension (regressive remodeling) over 16 months associated with surgically confirmed meniscus derangement in 24-year-old woman with painless clicking (A) that progressed to painful locking and episodes of posterior open bite (B–D) over a 16-month interval. There was externally visible displacement of chin toward deranged joint at time of second imaging (B–F).

A, Cephalometrically corrected lateral tomogram through midcondyle with mouth closed reveals normal condyle morphology and widened anterior articular space (arrow), suggesting anterior displacement of meniscus (not seen).

B, Lateral midcondyle tomogram 16 months later reveals persistent widening of anterior joint space (straight white arrow) with flattening of condyle surface (black arrow) compared with A. Note indentation of condylar neck (curved arrow), not present in A.

C–F, Sagittal closed-mouth MR images, 2200/20 (C) and 2200/80 (D), and half-open (E) and fully open (F) images, 30/13/short (30°) flip angle, reveal marked anterior displacement of degenerated meniscus (curved arrows) and large effusion (small white arrows). Note how meniscus is completely dislocated anteriorly relative to articular space on closed-mouth views (C and D) and fails to reduce with mouth opening (E and F). Slightly increased T2 signal from condylar marrow (large arrow, D) represents increased marrow fluid. Joint pain and occlusion disturbances did not recur during 12 months after meniscectomy.



deformans" to explain acquired mandibular deformity with ipsilateral lateral displacement of the chin with or without retrognathia due to underlying TMJ degeneration without fracture. On the basis of clinical investigations using two-compartment arthrography and correlative surgical observations, Wilkes [8, 9] described progressive meniscus derangement as the explanation for mechanical symptoms and

occlusion disturbances. Recent investigations have defined the progressive nature and pathologic stages of TMJ derangement [5, 24]. Adaptive cartilaginous and osseous processes have been shown to accompany the early stages of TMJ meniscus derangement, indicating that osteocartilaginous TMJ remodeling is a dynamic response to intraarticular soft-tissue disease [24, 28, 29]. Anomalous development,

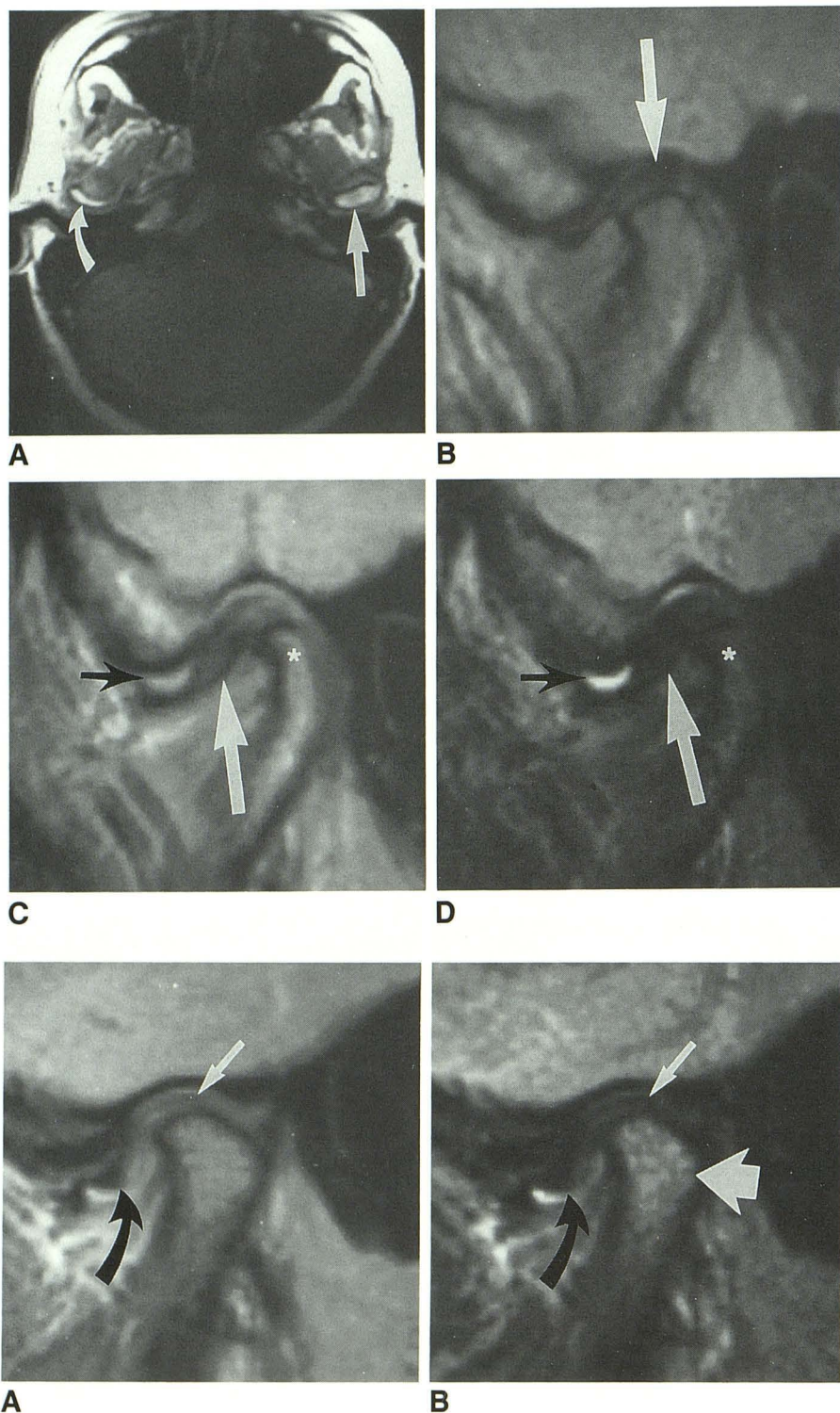


Fig. 6.—Skeletofacial deformity due to regressive remodeling of right mandibular condyle in 34-year-old woman with 3-year history of progressive right-sided temporomandibular joint pain and dysfunction. Skeletal occlusion intact at time of investigation.

A, Axial 5-mm-thick MR image, 500/20, obtained with dual temporomandibular joint surface-coil apparatus reveals small right mandibular condyle (curved arrow) and normal left condyle (straight arrow). Marrow signal is normal within both condyles.

B, Closed-mouth sagittal image, 2200/25, of left joint reveals normal meniscus (arrow) and osseous structures.

C and D, Closed-mouth images, 2200/25 (C) and 2200/80 (D), of right joint reveal anterior displacement and thickening of meniscus (white arrows) with upper-compartment effusion (black arrows) and normal marrow signal within small (compare with B) right mandibular condyle (asterisk).

Fig. 7.—Chronic headache, ear pain, and insidious occlusal changes due to nonreducing inflammatory temporomandibular joint arthropathy and regressive remodeling of mandibular condyle in 19-year-old woman.

A and B, MR images show advanced derangement with anterior displacement and deformity of meniscus (curved arrows); elongated, thinned, but intact posterior attachment (small white arrows); and increased marrow fluid (large white arrow) suggesting edema and transient regional osteoporosis. Radiographs (not shown) revealed this diseased condyle to be smaller than on opposite side. Chin was displaced toward degenerated joint.

mandibular condyle AVN [21, 23], and advanced stages of TMJ degeneration [5, 24] have been shown to result in acquired mandibular deformity (Figs. 1–12). Different variations of degenerative-adaptive osteocartilaginous changes on occasion are noted simultaneously within opposite joints of the same individual (Fig. 10). Osteoarthritis, AVN, and regres-

sive remodeling of the mandibular condyle coupled with facial deformity most often occur as a consequence of TMJ soft-tissue derangement (Fig. 13). Exceptions to this include (1) instances of direct-impact trauma to a normal joint leading to either osteochondral fracture or AVN and subsequent osteoarthritis, without damage to the meniscus and retrodiskal

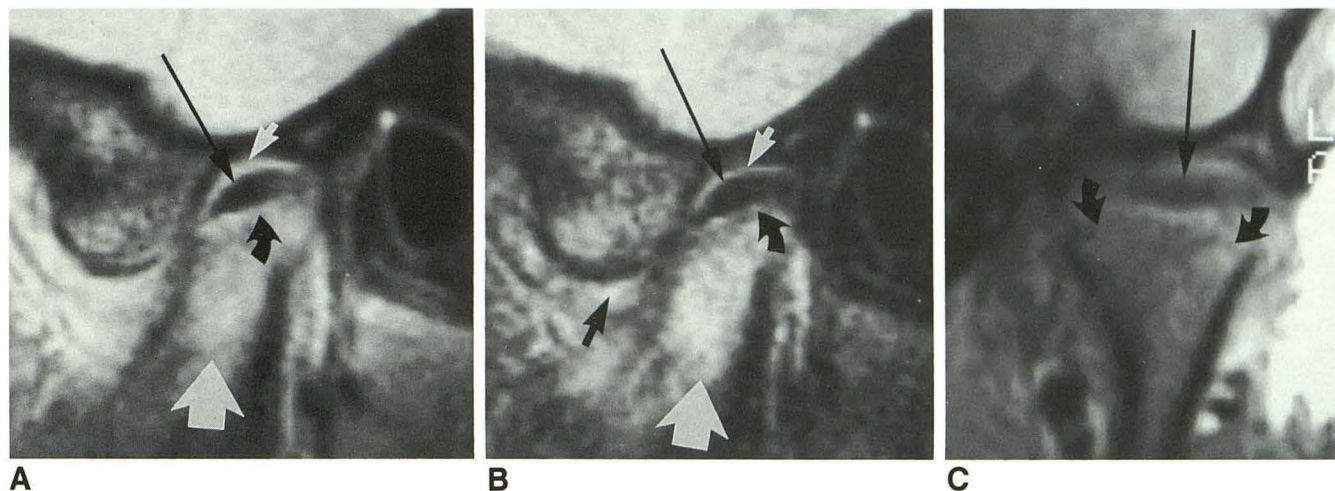


Fig. 8.—Headache, neck, and temporomandibular joint pain with progressive retrognathia due to condylar subsidence associated with normal meniscus in 12-year-old girl (in orthodontic braces at time of study) with proved juvenile rheumatoid arthritis. Tomograms (not shown) revealed bilateral articular surface infractions of mandibular condyles coupled with osseous demineralization, interpreted to represent osteoporosis.

A–C, Sagittal, 2500/20 (A) and 2500/80 (B), and coronal, 600/20 (C), MR images reveal normal meniscus (*long arrows*), joint fluid (*small straight arrows*), and depression of articular surface (*curved arrows*) of mandibular condyle (compare with Fig. 6B). Increased marrow signal (*large white arrows*) represents increased marrow fluid, believed to represent regional osteoporosis. Surgery was not performed.

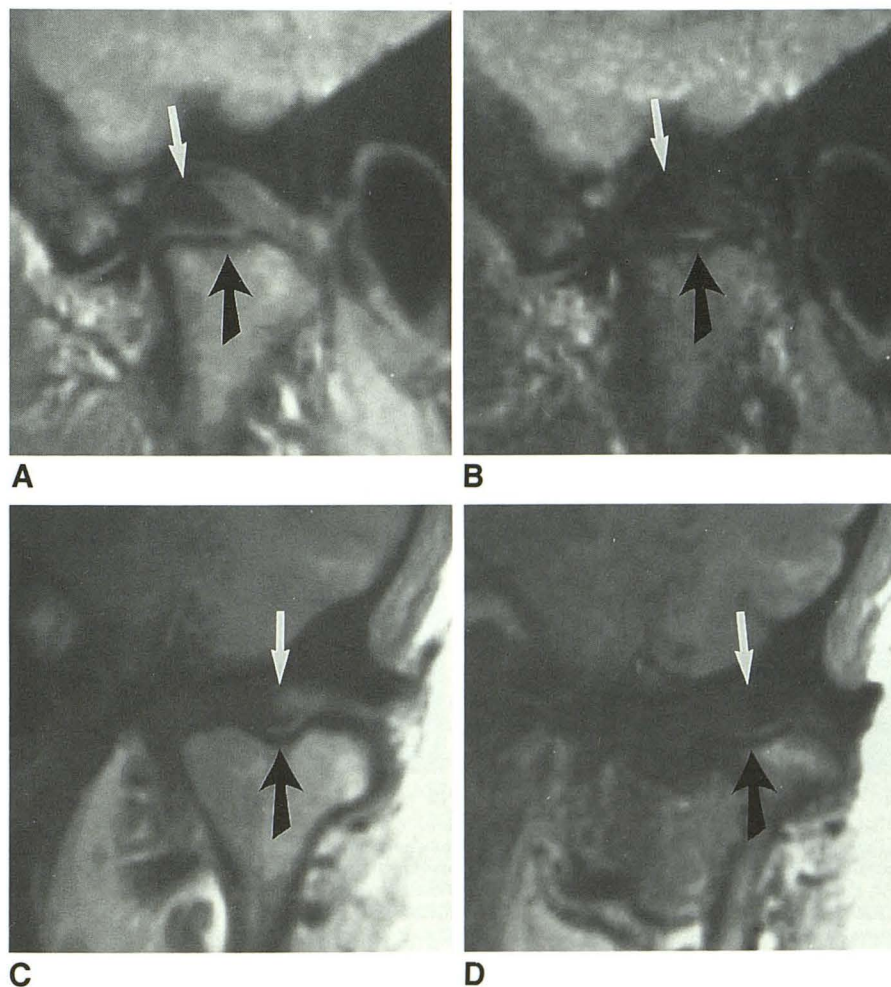


Fig. 9.—Mandibular condyle deformity due to old healed osteochondritis dissecans (transchondral fracture) sustained during jaw trauma 2 years before imaging in 32-year-old woman with clinically “frozen joints” and severely restricted mouth opening.

A and B, Sagittal closed-mouth MR images, 2200/25 (A) and 2200/80 (B), reveal depressed central articular surface (*black arrows*) in center of mandibular condyle beneath slightly thickened, but normally positioned, posterior band of meniscus (*white arrows*).

C and D, Adjacent coronal images, 800/20, 3 mm thick (D anterior to C), reveal depressed central articular surface of condyle (*black arrows*) beneath thickened meniscus (*white arrows*).

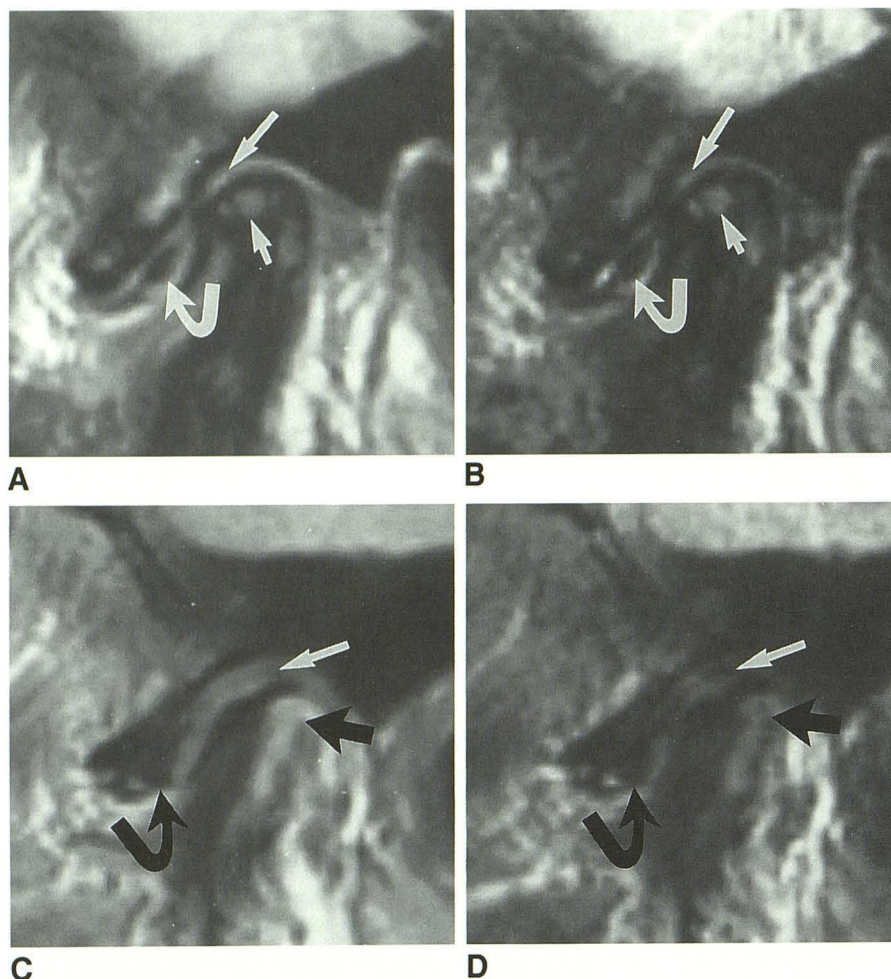


Fig. 10.—Advanced bilateral joint degeneration with features primarily of osteoarthritis (A and B) and regressive remodeling (C and D) in 50-year-old woman with long history of pain, joint dysfunction, episodic occlusal disturbances, and chin displacement toward C and D.

A and B, Sagittal images, 2200/25 (A) and 2200/70 (B), reveal severe displacement and degeneration of meniscus (curved arrows), narrowing of articular space (long straight arrows, compare with C and D), and subarticular cystic change (short straight arrows), tomographically confirmed.

C and D, Meniscus (curved arrows) is anteriorly displaced and degenerated. Note thinned but intact posterior attachment (white arrows) within maintained articular space (compare with A and B). Condyle (straight black arrows) exhibits predominantly regressive changes compared with A and B.

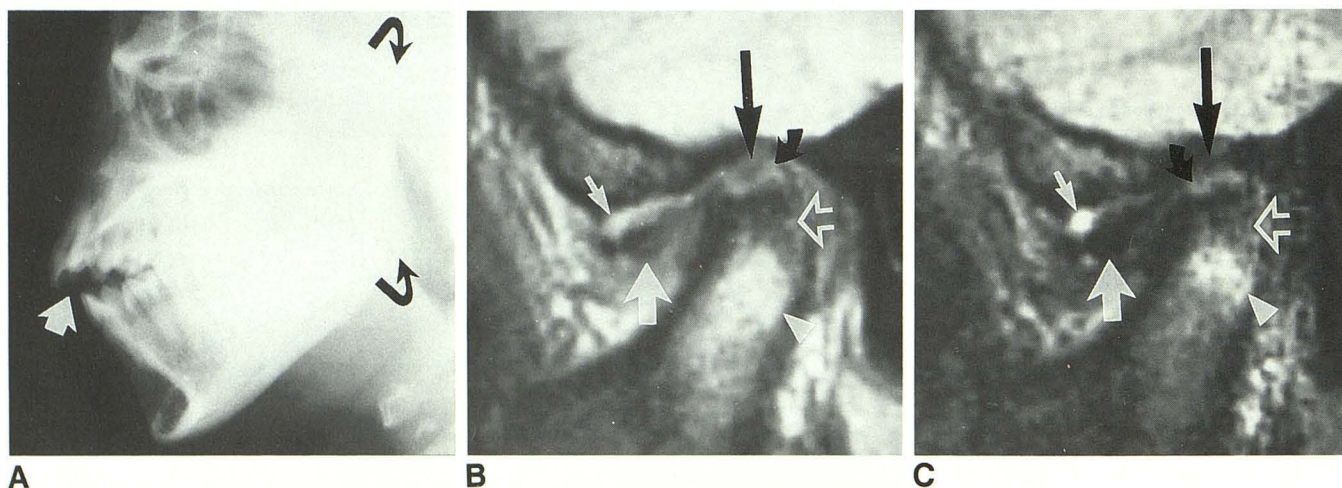


Fig. 11.—Rapidly progressive skeletofacial deformity and anterior open bite due to bilateral avascular necrosis of mandibular condyles in 29-year-old woman with 2-year history of bilateral joint pain and dysfunction and 10-week history of progressive retrognathia and anterior open bite.

A, Lateral radiograph reveals decreased vertical dimension in posterior mandible (curved arrows), chin retrusion, and anterior open bite (white arrow).

B and C, Closed-mouth sagittal, 2500/25 (B) and 2500/80 (C), MR images reveal surgically confirmed late-stage derangement of meniscus (large white arrows) and joint effusion (small white arrows). Healing, fractured cortical bone (straight black arrows) from articular surface lies above area of marrow edema (curved arrows). Zone of tomographically confirmed osseous healing and sclerosis (open arrows) lies above area of marrow edema in condylar neck (arrowheads). Pain was immediately relieved by meniscectomy, joint debridement, and reconstructive arthroplasty without alloplastic materials. Skeletal occlusion and facial deformity were stable and unchanged 15 months after surgery.

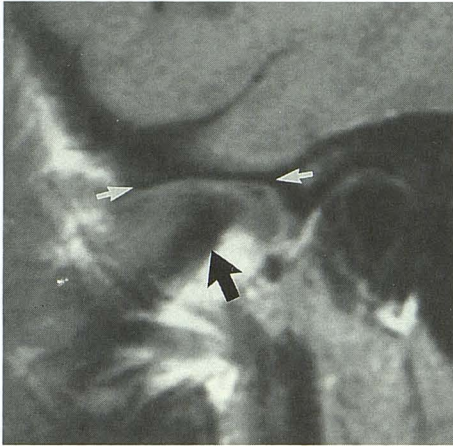


Fig. 12.—Severe condylar deformity and resorption (condylolysis) due to old avascular necrosis in a 29-year-old woman with history of mandibular injury during adolescence and progressive skeletofacial deformity and malocclusion in recent years. Sagittal image, 600/20, 3 mm thick, reveals complete loss of marrow signal within deformed condyle (black arrow). Flattening of articular surface of temporal bone (white arrows) is due to osseous remodeling.

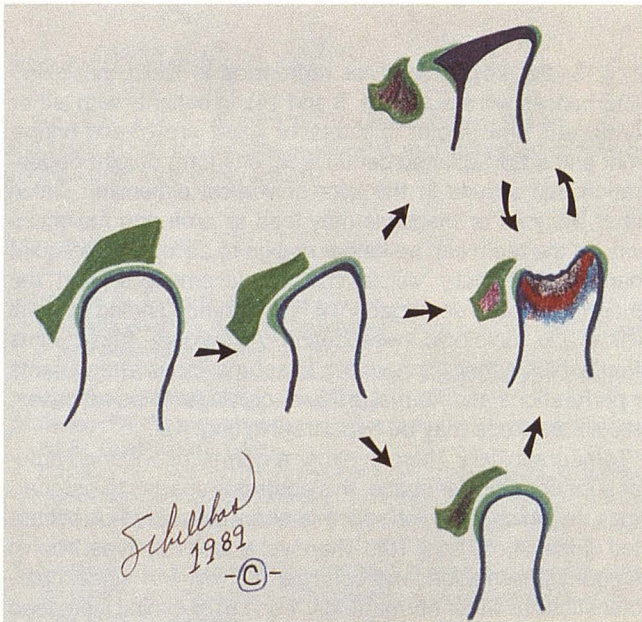


Fig. 13.—Proposed relationships between meniscus derangement, osteoarthritic remodeling, and joint degeneration. Normal mandibular condyle, articular cartilage, and meniscus are on far left. Early remodeling and deformity of mandibular condyle and cartilage due to overlying meniscus derangement is in middle. Osteoarthritis (upper right), avascular necrosis (middle right), and regressive remodeling (lower right) of mandibular condyle occur secondary to meniscus derangements in most cases. Straight arrows denote direction of disease progression. Note hypertrophic cortical bone and cartilaginous thickening along anterior margin of deformed condyle in osteoarthritis. Curved arrows denote how osteoarthritis and avascular necrosis of mandibular condyle may precede or follow one another. Note thickened articular cartilage beneath deranged meniscus in regressive remodeling and compare with normal joint on left.

soft tissues at the time of injury (Fig. 9); (2) barotrauma and systemic chemotherapy (especially steroids), which may directly insult the condylar marrow and lead to AVN; and (3) systemic inflammatory diseases such as rheumatoid arthritis

(Fig. 8) and the connective tissue disorders, which may lead to osteoarthritic degeneration without meniscus derangement [21]. In our experience, internally deranged joints appear to be more susceptible to additional insult and complications such as osteochondritis dissecans and AVN with episodes of trauma compared with normal joints [5, 21, 22, 24, 27].

Osteoarthritis

Osteoarthritis is the most commonly diagnosed degenerative joint disorder on radiologic studies and represents the end result of a wide variety of injurious processes [30]. In the TMJ, osteoarthritis (Fig. 10) is recognized both radiologically and surgically/pathologically by findings such as narrowing and/or obliteration of the articular space; mandibular condyle flattening; deformity and sclerosis; hypertrophic osteophytes at the articular surface margins; advanced displacement and degeneration of the meniscus, most often with perforation of disk attachments; and areas of erosion, healing, and marginal hypertrophy of the articular cartilage of the condyle and temporal bone (Figs. 10 and 13) [5, 24]. With the loss of articular cartilage, condyle flattening, and degeneration, there is progressive loss of vertical dimension within the condyle and condylar neck (proximal mandibular segment), often resulting in facial contour changes, as the chin moves posteriorly and laterally toward the ipsilateral degenerated joint (Figs. 13 and 14) [4, 5, 21–24, 31]. Most often, osteoarthritis produces insidious skeletal changes, allowing simultaneous ipsilateral dental intrusion and realignment accompanied by contralateral realignment and/or eruption to occur as adaptive responses to proximal skeletal changes (Figs. 3 and 14) [22, 24]. Major, long-term alterations in occlusion are avoided by this dental adaptation; however, fluctuating occlusion disturbances such as transient posterior open bite are common during episodes of joint inflammation. Most osteoarthritic joints ultimately reach a state of clinical and radiologic stability [5]. This state of clinical stability can be disrupted by injury, systemic illness, and occlusal manipulations, which result in joint inflammation and renewed skeletal remodeling [21, 24, 27].

AVN

AVN or aseptic necrosis of the mandibular condyle has been shown to be a common sequela of inflammatory joint derangement [21, 22]. Systemic disease, trauma, orthodontics, and orthognathic surgery all may lead to AVN of the condyle in a previously deranged joint; however, internal derangement of the TMJ with inflammation is the most common cause of AVN (Figs. 1, 2, 11, and 12) [21, 22, 32]. With AVN, the articular surface of the condyle loses structural integrity and is prone to mechanical failure (fracture), leading to loss of vertical dimension (Figs. 11–13) [2, 4, 21–25, 27, 32–36]. The rapid loss of vertical dimension frequently leads to major disturbances of occlusion, such as contralateral anterior open bite with ipsilateral posterior molar prematurity of contact and crossbite; this causes facial deformity and chin displacement toward the vertically collapsed joint (Figs. 1–3,

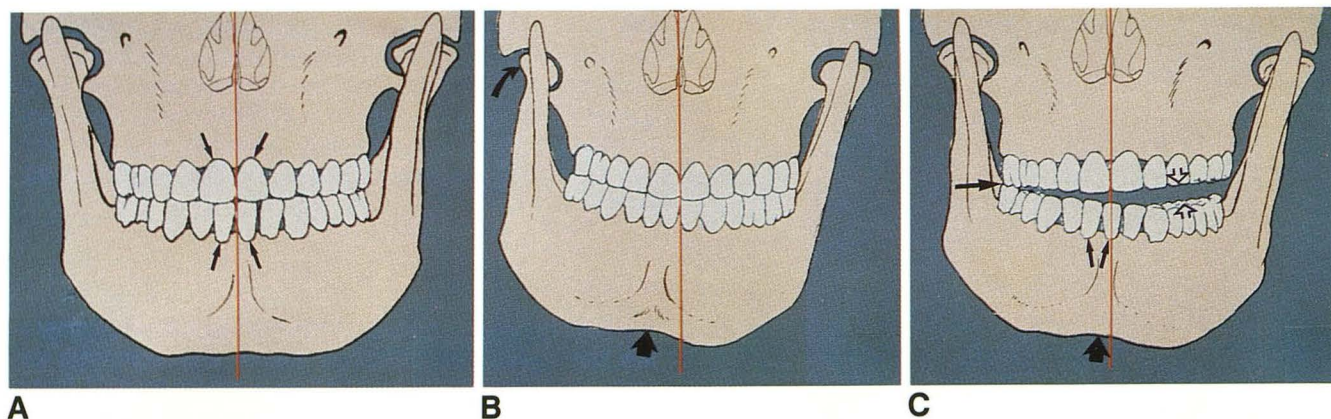


Fig. 14.—Effects of skeletal remodeling on occlusion and facial appearance.

A, Slow, symmetric temporomandibular joint degeneration permits maintenance of side-to-side facial symmetry and intact occlusion. Red vertical line divides central incisors (arrows).

B, Slow degeneration (regressive remodeling, osteoarthritis) of one temporomandibular joint and mandibular condyle (curved arrow) permits adaptive dental remodeling to maintain stable occlusion despite facial deformity. Note deviation of chin point (straight arrow) toward degenerated temporomandibular joint. Central incisors remain aligned relative to vertical line.

C, Sudden decreased vertical dimension in temporomandibular joint (acute avascular necrosis, fracture, rapid regressive remodeling) may lead to ipsilateral premature contact of posterior dentition (long arrow), contralateral open bite (open arrows), and shifting of lower teeth and mandible toward degenerated joint. Note how low central incisors (small arrows) have shifted relative to vertical line despite less deviation of chin (large short arrow) relative to B. This explains how small, but abrupt, changes in joint dimension may lead to catastrophic occlusion disturbances.

11, and 14) [2, 4, 21, 23, 24]. Various stages of AVN are often observed within the same joint on long TR/short and long TE MR studies, representing areas of ischemia, inflammation, necrosis, and repair (Fig. 11) [21, 22, 24]. Many cases of mandibular deformity are a result of AVN. AVN may develop within a quiescent osteoarthritic joint if the joint is stressed by trauma; iatrogenic manipulation; barotrauma; and/or systemic inflammatory illness, such as connective tissue disorder, pancreatitis, or exogenous steroid administration (Fig. 13) [21]. AVN leads to secondary osteoarthritis.

Regressive Remodeling

Regressive remodeling is clearly both a degenerative and adaptive process that differs from osteoarthritis and AVN clinically and radiologically [24]. In regressive remodeling, the osteocartilaginous response to meniscus displacement and degeneration is generally characterized by slow, insidious osseous remodeling and resorption leading to the loss of condylar mass and vertical dimension, without hypertrophic changes (Figs. 4–7 and 14). This loss of vertical dimension and mass appears to be mediated by osteoporosis (Figs. 5, 7, and 8) [36]. Regressive condylar changes begin in the earliest stages of meniscus derangement and are typified by subtle widening of the articular space adjacent to the displaced meniscus (Figs. 4 and 5), suggesting that meniscus displacement and thickening provide the noxious stimulus for subsequent osteocartilaginous remodeling (Fig. 13) [24]. Both the articular surfaces of the temporal bone and mandibular condyle are observed to undergo these adaptive changes (Figs. 4–7). This regressive-adaptive process is often, but not necessarily, accompanied by insidious, adaptive dental changes that maintain comfortable occlusion and further accommodate the meniscus derangement (Figs. 2, 3, and 14)

[2, 4, 5, 22, 24]. If condylar regression is rapid, occlusion disturbances will result (Figs. 8 and 14). In patients with either permanent oral (teeth) implants or fixed crown-and-bridge work and a fully splinted dental arch, any form of joint degeneration that results in the loss of vertical dimension within either the joint or mandible may lead to profound malocclusion, as the teeth can no longer realign to accommodate joint changes. Externally visible chin displacement toward the smaller and more deranged joint is a common finding at initial clinical and radiologic investigation. At surgery, these joints often exhibit either thinned, but intact meniscus attachments or perforations and normal articular cartilage. In some cases, articular cartilage may be hypertrophic (Fig. 4).

Tomographically, there is either a normal or widened anterior superior articular space; this contrasts sharply to osteoarthritis, in which the joint space is either narrowed or obliterated (Figs. 4, 5, and 10). There is a lack of hypertrophic osteophyte formation, and condylar marrow MR signal characteristics are either normal (Figs. 4 and 6) or exhibit increased marrow fluid (decreased T1 signal and increased proton density and T2 signal relative to normal marrow), suggesting increased metabolic activity due to transient osteoporosis and bone resorption (Figs. 5, 7, and 8) [36–40]. It is impossible to distinguish early condylar AVN (ischemia/edema phase) from what we propose represents transient, regional osteoporosis of the condyle and/or proximal mandibular segment on the basis of MR signal changes alone [40]. Clinical observations of MR signal changes in the appendicular skeleton and femoral head suggest that early marrow edema (stage I AVN) and transient, regional osteoporosis are identical, representing a spectrum of altered marrow physiology [38–40]. Radiologically observed morphologic changes and clinical observations help direct one toward a proper diagnosis. Joints exhibiting typical radiologic features of regressive remodeling

have been observed to undergo AVN and structural collapse after stress, such as injury, orthodontics, and/or orthognathic surgery (Fig. 13) [2, 21, 24, 27].

Clinicians must ask the questions: "Why is this face changing?" and "Why is this patient's occlusion unstable?" before endeavoring to alter skeletal relationships with dental appliances, orthodontic braces, and/or orthognathic surgical procedures. In the absence of obvious fractures and/or missing teeth, the answer to these questions most often will be TMJ disease. MR imaging will be required to establish and stage this disease. Both failed orthodontic occlusion adjustment and orthognathic surgery may result from underlying TMJ arthropathy, as TMJ disease is a progressive disorder that may be exacerbated by skeletal manipulations [5, 21, 24]. The effects of childhood TMJ internal derangement on facial growth and development need to be fully investigated with MR.

We recommend screening skull-mandible radiography, including submentovertex and open-mouth, jaw-protruded radiographs of the skull and mandible; this should be followed by closed- and open-mouth, lateral TMJ tomograms, followed by a surface-coil MR study of the TMJs and skull base in patients with acquired facial skeleton remodeling and/or deranged occlusion. Lateral radiographs of the mandible and facial bones are helpful in cases of anterior open bite, retrognathia, prognathism, and maxillary deficiency.

ACKNOWLEDGMENTS

We thank Jerry K. Brunsoman, Robert B. Gillum, Robert J. Keck, and Clyde H. Wilkes for clinical, surgical, and pathologic correlation in cases illustrated in this article.

REFERENCES

- Boering G. *Arthrosis deformans van het Kaakgewricht. Een klinisch en röntgenologisch onderzoek* (dissertation). Groningen, the Netherlands: Rijksuniversiteit te Groningen, 1966
- Schellhas KP. Unstable occlusion and temporomandibular joint disease. *J Clin Orthodont* 1989;23(5):332-337
- Dawson PE. *Evaluation, diagnosis and treatment of occlusal problems*, 2nd ed. St. Louis: Mosby, 1989
- Schellhas KP, Keck RJ. Disorders of skeletal occlusion and temporomandibular joint disease. *Northwest Dent* 1989;68(1):35-42
- Wilkes CH. Internal derangements of the temporomandibular joint: pathologic variations. *Arch Otolaryngol Head Neck Surg* 1989;115:469-477
- Schellhas KP, El Deeb M, Wilkes CH, et al. Three-dimensional computed tomography in maxillofacial surgical planning. *Arch Otolaryngol Head Neck Surg* 1988;114:438-442
- Farrar WB. Diagnosis and treatment of anterior dislocation of the articular disc. *NY J Dent* 1971;41:348-351
- Wilkes CH. Arthrography of the temporomandibular joint in patients with TMJ pain-dysfunction syndrome. *Minn Med* 1978;61:645-652
- Wilkes CH. Structural and functional alterations of the temporomandibular joint. *Northwest Dent* 1978;57:274-294
- Guralnick W, Kaban LB, Merrill RG. TMJ afflictions. *N Engl J Med* 1978;299:123-129
- Helms CA, Katzberg RW, Dolwick MF. *Internal derangements of the temporomandibular joint*. San Francisco: University of California San Francisco Radiology Research and Education Foundation, 1983
- Katzberg RW, Schenck JF, Roberts D, et al. Magnetic resonance imaging of the temporomandibular joint meniscus. *Oral Surg Oral Med Oral Pathol* 1985;59:332-335
- Harms SE, Wilk RM, Wolford LM, et al. The temporomandibular joint: magnetic resonance imaging using surface coils. *Radiology* 1985;157:133-136
- Katzberg RW, Bessette RW, Tallents RH, et al. Normal and abnormal temporomandibular joint: MR imaging with surface coil. *Radiology* 1986;158:183-189
- Harms SE, Wilk RM. Magnetic resonance imaging of the temporomandibular joint. *RadioGraphics* 1987;7(4):521-542
- Schellhas KP, Wilkes CH, Fritts HM, Omlie MR, Heithoff KB, Jahn JA. Temporomandibular joint: MR imaging of internal derangements and post-operative changes. *AJNR* 1987;8:1093-1101, *AJR* 1988;150(2):381-389
- Westesson P-L, Katzberg RW, Tallents RH, Sanchez-Woodworth RE, Svensson SA, Elpeland MA. Temporomandibular joint: comparison of MR images with cryosectional anatomy. *Radiology* 1987;164:59-64
- Schellhas KP, Wilkes CH, Omlie MR, et al. The diagnosis of temporomandibular joint disease: two compartment arthrography and MR. *AJNR* 1988;9:579-588, *AJR* 1988;151:341-350
- Katzberg RW, Westesson P-L, Tallents RH, et al. Temporomandibular joint: MR assessment of rotational and sideways disk displacements. *Radiology* 1988;169:741-749
- Schellhas KP, Wilkes CH, Baker CC. Facial pain, headache and temporomandibular joint inflammation. *Headache* 1989;29(4):229-232
- Schellhas KP, Wilkes CH, Fritts HM, Omlie MR, Lagrotteria LB. MR of osteochondritis dissecans and avascular necrosis of the mandibular condyle. *AJNR* 1989;10:3-12, *AJR* 1989;152:551-560
- Schellhas KP, Wilkes CH. Temporomandibular joint inflammation: comparison of MR fast scanning with T1- and T2-weighted imaging techniques. *AJNR* 1989;10:589-598, *AJR* 1989;152:93-98
- Schellhas KP, Wilkes CH, El Deeb M, Lagrotteria LB, Omlie MR. Permanent Proplast temporomandibular joint implants: MR imaging of destructive complications. *AJR* 1988;151:731-735
- Schellhas KP. Internal derangement of the temporomandibular joint: radiologic staging with clinical, surgical and pathologic correlation. *Magn Reson Imaging* 1989;7(5):495-515
- Resnick D, Goergen TG, Niwayama G. Transchondral fractures (osteochondritis dissecans). In: Resnick DK, Niwayama G, eds. *Diagnosis of bone and joint disorders*, vol. 5. Philadelphia: Saunders, 1988:2795-2812
- Schellhas KP. MR imaging of muscles of mastication. *AJNR* 1989;10:829-837, *AJR* 1989;153:847-855
- Schellhas KP. Temporomandibular joint injuries. *Radiology* 1989;173(1):211-216
- DeBont LGM, Boering G, Liem RSB, Eulerink F, Westesson P-L. Osteoarthritis and internal derangement of the temporomandibular joint: a light microscopic study. *J Oral Maxillofac Surg* 1986;44:634-643
- Stegenga B, DeBont LGM, Boering G. Osteoarthritis as the cause of craniomandibular pain and dysfunction: a unifying concept. *J Oral Maxillofac Surg* 1989;47:249-256
- Resnick DK, Niwayama G. Degenerative diseases of extraspinal locations. In: Resnick DK, Niwayama G, eds. *Diagnosis of bone and joint disorders*. Philadelphia: Saunders, 1988:1364-1479
- Helmy E, Bays R, Sharawy M. Osteoarthritis of the temporomandibular joint following experimental disc perforation in *Macaca fascicularis*. *J Oral Maxillofac Surg* 1988;46:979-990
- Reiskin AB. Aseptic necrosis of the mandibular condyle: a common problem? *Quintessence Int* 1979;2:85-89
- Sweet DE, Madewell JE. Pathogenesis of osteonecrosis. In: Resnick DK, Niwayama G, eds. *Diagnosis of bone and joint disorders*. Philadelphia: Saunders, 1988:3188-3237
- Mitchell DG, Rao VM, Dalinka MK, et al. Femoral head avascular necrosis: correlation of MR imaging, radiographic staging, radionuclide imaging, and clinical findings. *Radiology* 1987;162:709-715
- Lang P, Jergesen HE, Mosely ME, Block JE, Chafetz NI, Genant HK. Avascular necrosis of the femoral head: high-field-strength MR imaging with histologic correlation. *Radiology* 1988;169:517-524
- Resnick D, Niwayama G. Osteoporosis. In: Resnick D, Niwayama G, eds. *Diagnosis of bone and joint disorders*. 2nd ed. Philadelphia: Saunders, 1988:2022-2085
- Resnick D, Niwayama G. Transient osteoporosis of the hip. In: Resnick D, Niwayama G, eds. *Diagnosis of bone and joint disorders*, 2nd ed. Philadelphia: Saunders, 1988:2043-2053
- Bloem JL. Transient osteoporosis of the hip: MR imaging. *Radiology* 1988;167:753-755
- Wilson AJ, Murphy WA, Hardy DC, Totty WG. Transient osteoporosis: transient bone marrow edema? *Radiology* 1988;167:757-760
- Turner DA, Templeton AC, Selzer PM, Rosenberg AG, Petasnick JP. Femoral capital osteonecrosis: MR finding of diffuse marrow abnormalities without focal lesions. *Radiology* 1989;171:135-140