



Providing Choice & Value

Generic CT and MRI Contrast Agents



FRESENIUS
KABI

CONTACT REP

AJNR

Dural arteriovenous fistulas involving the inferior petrosal sinus: angiographic findings in six patients.

S L Barnwell, V V Halbach, C F Dowd, R T Higashida and G B Hieshima

This information is current as
of July 27, 2025.

AJNR Am J Neuroradiol 1990, 11 (3) 511-516
<http://www.ajnr.org/content/11/3/511>

Dural Arteriovenous Fistulas Involving the Inferior Petrosal Sinus: Angiographic Findings in Six Patients

Stanley L. Barnwell¹
 Van V. Halbach
 Christopher F. Dowd
 Randall T. Higashida
 Grant B. Hieshima

We report the angiographic findings from six patients with intracranial dural arteriovenous fistulas of the inferior petrosal sinus and describe the clinical presentation, vascular anatomy, and embolization techniques used in the treatment of this disorder. Dural arteriovenous fistulas at this site are rare; of 105 patients diagnosed with this abnormality, only six had lesions involving the inferior petrosal sinus.

The patients included three men and three women, ranging in age from 41 to 75 years. Patients presented with bruit, proptosis, abducens palsy, or loss of vision, and symptoms were present for up to 1 year prior to diagnosis. These presentations were similar to cavernous sinus arteriovenous fistulas. The arterial supply in all cases was from branches of the external carotid artery and in three cases from the meningohypophyseal trunk of the internal carotid artery. Venous drainage in four patients was via the cavernous sinus to the superior ophthalmic vein. The remaining two patients had drainage primarily to the jugular bulb. In four patients treatment was performed by introducing wire coils into the fistula from the transvenous route. This approach could be used even though the inferior petrosal sinus was thrombosed. One patient, treated early in the series, had only transarterial embolization with both liquid adhesives and particulate embolic agents. One patient had an asymptomatic fistula that was not treated. All patients were cured, as evidenced both angiographically and clinically during the follow-up period. Three patients experienced complications from angiography and treatment: two had transverse sinus thrombosis and one had a transient ischemic attack.

AJNR 11:511-516, May/June 1990

Dural arteriovenous fistulas (DAVFs) represent 10-15% of all intracranial arteriovenous malformations [1]. They occur most often in the region of the transverse, sigmoid, and cavernous sinuses, but may occur in any dural structure. Most DAVFs are thought to be acquired lesions caused by dural sinus thrombosis [2, 3].

During the past 10 years, over 105 DAVFs have been treated at our institution with a variety of treatment methods, including compression therapy, intravascular embolization, and surgery, or combinations of these. Of the 105 patients with DAVF that we treated, six (6%) had lesions involving the inferior petrosal sinus. Because of their deep location, complex arterial supply, and frequent drainage to the superior ophthalmic vein, DAVFs in this region present unique problems in their diagnosis and treatment. Surgical removal, which is often recommended for symptomatic DAVFs in the posterior fossa [4], is usually not feasible here because of the risk of damaging the lower cranial nerves or normal vascular channels. Intravascular embolization has emerged as an effective treatment for many DAVFs in other locations, and the results of this treatment for lesions in the inferior petrosal sinus are reported.

Subjects and Methods

The clinical and radiographic findings of six patients who were treated over the past 10 years for DAVFs involving the inferior petrosal sinus were reviewed. Patients' age ranged

Received August 24, 1989; revision requested October 16, 1989; revision received November 29, 1989; accepted December 4, 1989.

¹ All authors: Department of Radiology, Section of Interventional Neuroradiology, University of California, San Francisco, 505 Parnassus Ave., San Francisco, CA 94143. Address reprint requests to S. L. Barnwell.

0195-6108/1103-0511
 © American Society of Neuroradiology

from 41 to 75 years (mean, 60 years). The presenting signs and symptoms, arterial supply, venous drainage, treatment, and outcome are summarized in Table 1.

Results

Causes

The onset of symptoms was spontaneous in all patients; trauma was not a factor. One patient (patient 2) had angiographic findings of fibromuscular dysplasia involving the cervical carotid and vertebral arteries and may have been in a hypercoagulable state. One patient (patient 4) had undergone chemotherapy for lymphoma 4 months prior to the onset of symptoms related to the DAVF. One patient (patient 6) had a second fistula in the cavernous sinus and had

undergone a craniotomy for meningioma of the outer sphenoid ridge. Unlike the strong female predominance among patients with DAVF involving the cavernous sinuses [1], there was an equal distribution of men and women with lesions of the inferior petrosal sinus.

Presenting Symptoms and Signs

All but one patient (patient 5) presented with signs and symptoms similar to fistulas involving the cavernous sinus. These included bruit, proptosis, decreasing vision, and ocular movement palsies. Patient 5 presented with headaches and bruit over the mastoid. Patient 6 presented with cavernous sinus syndrome and loss of vision related to a fistula in the cavernous sinus. The fistula in the inferior petrosal sinus was asymptomatic.

TABLE 1: Inferior Petrosal Sinus Dural Arteriovenous Fistulas: Summary of Cases

Patient No.	Sex	Age (years)	Presenting Symptoms	Duration	Arterial Supply	Venous Drainage	Treatment (Embolic Agents)	Outcome	Complications
1	M	75	Bruit, diplopia, decreasing vision	1 year	Left IMA, AP, MMA	SOV, perimesencephalic veins, jugular bulb	TA (IBCA, hypertonic glucose, PVA, Gelfoam)	5 years, cured	TIA
2	F	52	Bruit, diplopia, proptosis	6 months	Left MMA, AP, MHT	SOV, jugular bulb	TV (platinum coils)	8 months, cured	Left transverse sinus occluded (asymptomatic)
3	M	63	Bilateral abducens palsies, decreasing vision, proptosis	3 months	Left IMA, MHT, PA, right IMA	SOV, jugular bulb	TV (platinum coils)	9 months, cured	None
4	M	41	Bruit, proptosis, diplopia, decreasing vision	6 months	Left ECA	SOV, superficial veins	TA (NBCA, PVA), TV (platinum coils)	3 months, cured	None
5	F	70	Bruit, headaches	6 months	Left AP, MHT, vertebral right AP	Jugular bulb, superficial veins	TA (PVA), TV (coils, 4-0 silk)	6 months, cured	Left transverse, sigmoid sinus, jugular bulb thrombus, cranial nerve IX, X, XII palsies (resolved)
6	F	72	Abducens palsy, decreasing vision, proptosis	1 year	Left MMA, STA	Jugular bulb	None		Asymptomatic, not treated

Note.—AP = ascending pharyngeal artery, ECA = external carotid artery, IBCA = isobutylcyanoacrylate, IMA = internal maxillary artery, MHT = meningo-hypophyseal trunk, MMA = middle meningeal artery, NBCA = *n*-butylcyanoacrylate, PA = posterior auricular artery, PVA = polyvinyl alcohol particles, SOV = superior ophthalmic vein, STA = superficial temporal artery, TA = transarterial, TIA = transient ischemic attack, TV = transvenous.

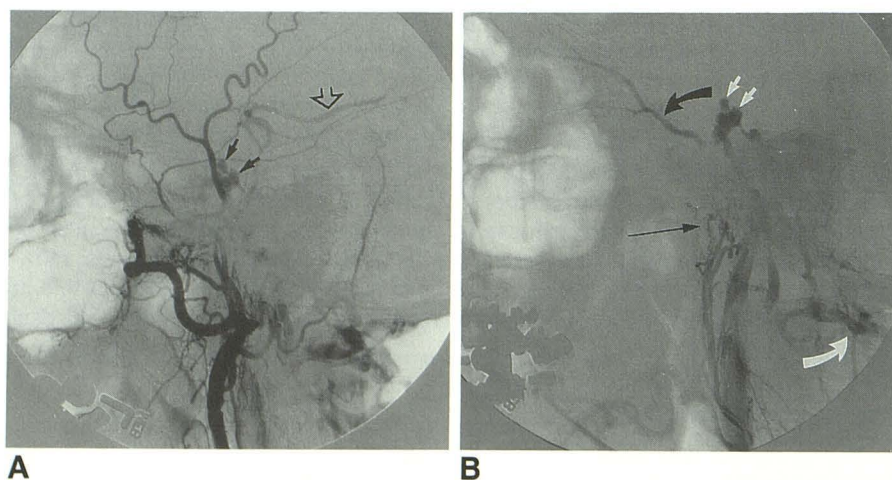


Fig. 1.—Patient 1.

A, Left external carotid artery injection, lateral view, shows venous drainage of dural arteriovenous fistula (DAVF) into cavernous sinus (closed arrows) and anterior pontomesencephalic veins and from there into interpeduncular veins and basal vein of Rosenthal (open arrow).

B, Left ascending pharyngeal artery injection, lateral view, shows DAVF (long thin arrow) involving the inferior petrosal sinus. Venous drainage is superior into cavernous sinus (small white arrows) and superior ophthalmic vein (curved black arrow), and posterior into cervical epidural venous plexus (curved white arrow).

Arterial Supply

In all patients, the dural fistula involved the left inferior petrosal sinus. Most often, the exact site of the fistula appeared to be at the inferior end of the sinus close to the jugular bulb.

The left external carotid artery supplied the fistula in all patients, usually from jugular and hypoglossal divisions of the neuromeningeal branch of the ascending pharyngeal artery. This artery may have anastomotic connections with the vertebral artery via the odontoid artery (patient 2). In two patients (patients 3 and 5), the contralateral ascending pharyngeal artery supplied the fistula. Additional supply frequently came from the meningohypophyseal trunk of the internal carotid artery. In one patient (patient 6) there was supply from the superficial temporal artery.

Venous Drainage

In four patients the predominant venous drainage was retrograde up the inferior petrosal sinus to the cavernous sinus, and then out through the superior ophthalmic vein. The particular drainage pattern was responsible for the clinical syndrome of proptosis, decreasing vision, and ophthalmoplegia. Three of these patients (patients 1, 2, and 3) (Figs. 1–3) also had some flow into the ipsilateral jugular vein, while in one (patient 4) (Fig. 4), the connection between the inferior petrosal sinus and jugular bulb was occluded. There were two patients (patients 5 and 6) with flow only into the jugular bulb and extracranial veins, because thrombosis of the superior portion of the inferior petrosal sinus had occurred. One of these patients (patient 6) had a second fistula involving the cavernous sinus (Fig. 5). The lack

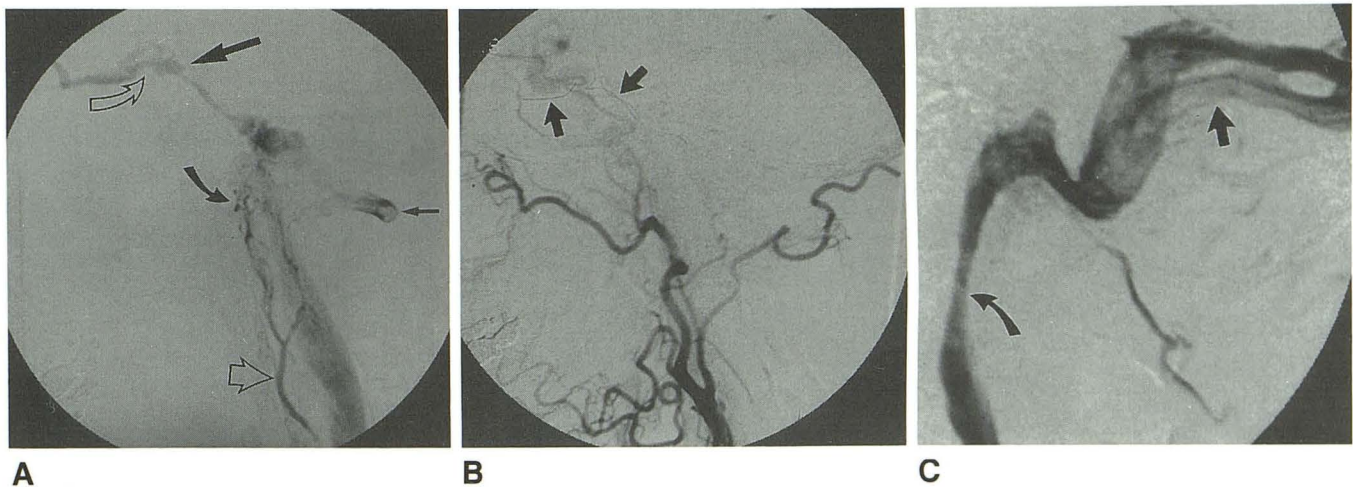


Fig. 2.—Patient 2.

A, Left ascending pharyngeal artery (open arrowhead) injection, lateral view, shows dural arteriovenous fistula (DAVF) of inferior petrosal sinus (curved closed arrow). Venous drainage is superior into cavernous sinus (large straight arrow) and superior ophthalmic vein (curved open arrow). Note filling of vertebral artery (small straight arrow) by an anastomosis.

B, Left external carotid artery injection, lateral view, shows complete absence of DAVF after transvenous embolization with wire coils (arrows).

C, Left internal carotid artery injection, late lateral view, shows occluded left transverse sinus (straight arrow). Venous drainage is out the right transverse sinus into right jugular vein (curved arrow).

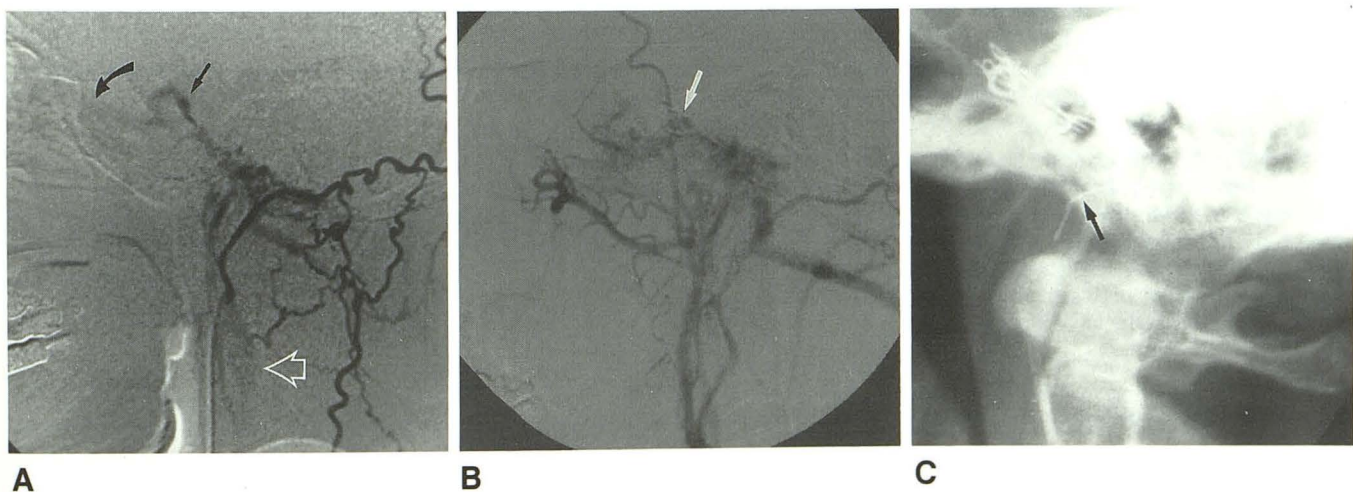


Fig. 3.—Patient 3.

A, Left occipital artery injection, lateral view, shows dural arteriovenous fistula (DAVF) of inferior petrosal sinus with venous drainage directed superiorly into cavernous sinus (straight arrow) and superior ophthalmic vein (curved arrow) and inferiorly into jugular vein (open arrowhead).

B, Left external carotid artery injection, lateral view, shows multiple platinum wire coils in inferior petrosal sinus (arrow). There is still flow through the fistula but venous drainage is entirely inferior and the superior ophthalmic vein no longer fills.

C, Skull radiograph, lateral view, shows multiple platinum wire coils in inferior petrosal sinus. One wire (arrow) refluxed into jugular bulb.

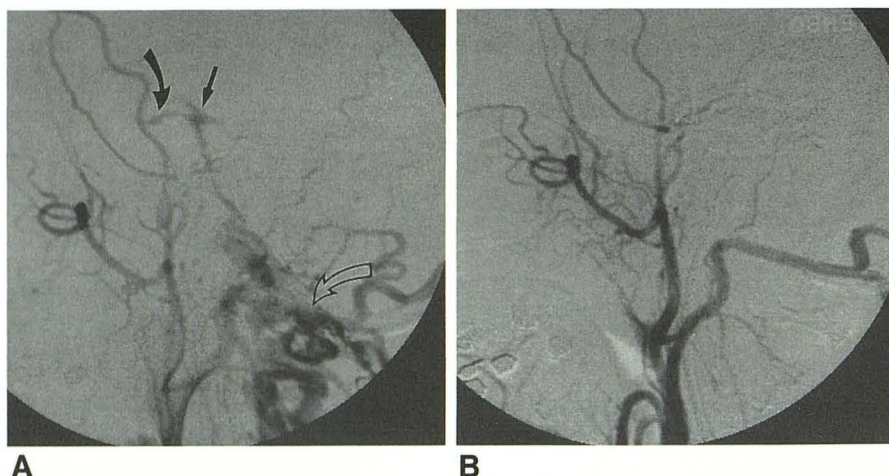


Fig. 4.—Patient 4.

A, Left external carotid artery injection, lateral view, shows dural arteriovenous fistula of inferior petrosal sinus. Venous drainage is directed superiorly into cavernous sinus (straight arrow) and superior ophthalmic vein (curved closed arrow) and through superficial cervical veins (curved open arrow).

B, Left external carotid artery injection, lateral view, after transvenous embolization shows complete obliteration of fistula.

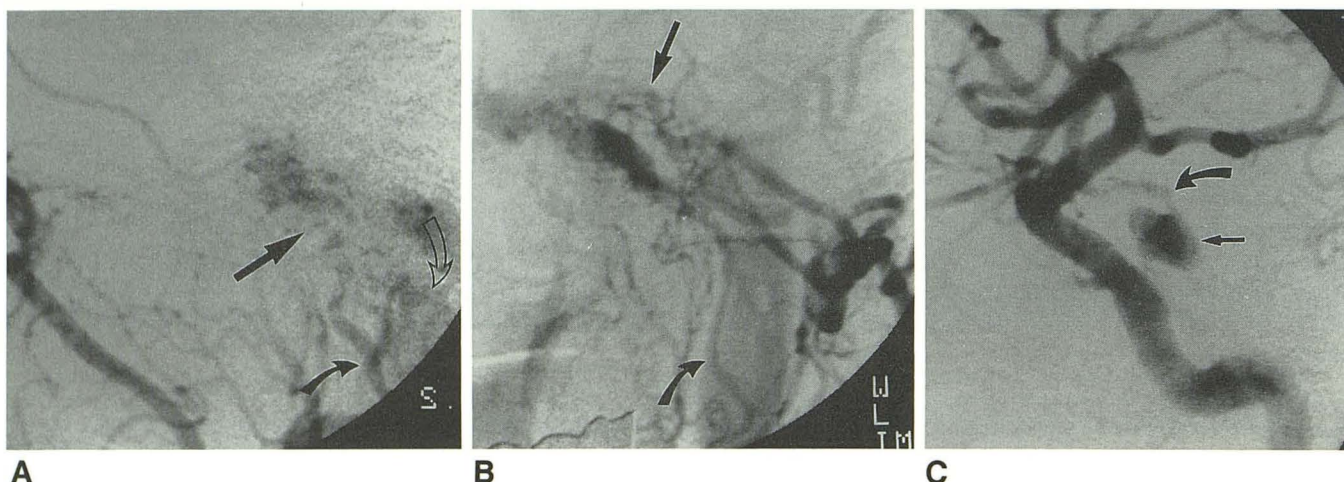


Fig. 5.—Patient 6.

A, Left external carotid artery injection, lateral view, shows dural arteriovenous fistula (straight arrow) of inferior petrosal sinus supplied by ascending pharyngeal artery (curved closed arrow). The venous drainage is to the jugular vein (curved open arrow). The inferior petrosal sinus was thrombosed above the fistula.

B, Left external carotid artery injection, anteroposterior view, shows inferior petrosal sinus fistula (straight arrow) draining to jugular vein (curved arrow).

C, Left internal carotid artery injection, lateral projection, shows dural arteriovenous fistula of cavernous sinus (straight arrow). Arterial supply is primarily from capsular artery of McConnell (curved arrow).

of flow into the cavernous sinus protected her eye from changes related to increased venous pressure.

In only one patient was there a venous drainage pattern that presented a higher risk of intracranial hemorrhage (patient 1, Fig. 1). There was drainage from the fistula into perimesencephalic veins and then into the basal vein of Rosenthal. No patients had cortical venous drainage into the supratentorial region.

Endovascular Treatment

Transvenous Embolization

Four patients were treated primarily by transvenous embolization. By means of the femoral transvenous route, a 7-French catheter was navigated into the jugular bulb. A 3.2-

French Tracker catheter (Target Therapeutics, Inc., San Jose, CA) was passed through the larger catheter and directed into the venous pathway, draining the fistula. Platinum coils (Target Therapeutics, Inc.) were then placed into the fistula site itself. In patient 5, more complete closure of the fistula from the venous side was accomplished by embolizing with 4-0 silk suture in addition to the coils.

In patient 4, the inferior petrosal sinus was occluded inferiorly and venous drainage was directed superiorly into the cavernous sinus and the superior ophthalmic vein. The absence of a visible communication between the jugular bulb and fistula did not rule out the possibility of approaching the fistula through the inferior petrosal sinus. We were able to navigate the guidewire into channels too small to be seen on the angiograms, and by placing the Tracker catheter through these small pathways we could deposit coils into the fistula.

Transarterial Embolization

By means of the femoral transarterial route, we performed embolization through feeding arteries in three patients (patients 1, 4, and 5). This technique was used as the only therapy in patient 1, who was treated early in the series. Three separate embolization procedures resulted in complete closure of the fistula. The feeding arteries were selectively catheterized and embolized with a combination of liquid adhesive (isobutyl cyanoacrylate) (Ethicon, Inc., Sommerville, NJ), particulate agents (polyvinyl alcohol and Gelfoam sponge) (Upjohn Co., Kalamazoo, MI), and hypertonic glucose (50%). The polyvinyl alcohol particles were 300–700 μm in size. Particles larger than 300 μm are unlikely to enter end arteries supplying cranial nerves and thus produce cranial nerve deficits.

Prior to performing embolization of the ascending pharyngeal artery, which via the neuromeningeal branch may supply the lower cranial nerves, functional territory was studied by injecting lidocaine (20 mg) and evaluating cranial nerve function. Dexamethasone (10 mg intravenously, 4 mg orally four times a day) was given if liquid adhesives were used to lessen the painful inflammatory response.

Patients 4 and 5 had combined transvenous and transarterial embolization. Liquid adhesive (*n*-butylcyanoacrylate) (CRX Medical, Raleigh, NC) and polyvinyl alcohol (Pacific Medical Industries, La Mesa, CA) were delivered into selected branches that supplied the fistula.

Treatment Results

The five patients who were treated all had clinical cure of the fistula with total resolution of signs and symptoms. Patients have been followed from 3 months to 5 years. In patients 2, 3, and 5 a follow-up angiogram demonstrated complete closure of the fistula. Patients 1 and 4 have had complete resolution of the clinical syndrome.

Complete angiographic closure of the fistula at the time of embolization occurred in only one patient (patient 4). The more common result was a marked reduction in the amount of flow into the fistula, which subsequently went on to thrombose.

One patient with multiple fistulas (patient 6) had transvenous therapy of the cavernous sinus fistula. The inferior petrosal sinus fistula was asymptomatic and was not treated; it will be followed clinically.

Complications

One patient (patient 5) developed extensive thrombosis of the ipsilateral transverse and sigmoid sinus and jugular bulb 1 week after the embolization. She developed significant loss of cranial nerves IX, X, and XII. These deficits improved after thrombolysis with urokinase of clot within the involved sinuses.

One patient (patient 2) developed thrombosis of the ipsilat-

eral transverse sinus after closure of the fistula (Fig. 4). There were no signs or symptoms related to this sinus thrombosis. The contralateral transverse sinus, which is normally dominant, was capable of handling the venous drainage.

One patient (patient 1) had short-term memory loss during the angiogram. This problem resolved within 24 hr.

Discussion

Dural arteriovenous fistulas involving the inferior petrosal sinus are rare. The frequency of these lesions is not known, and they have not been presented as a separate entity before this report.

Dural arteriovenous fistulas are usually considered to be acquired lesions [2, 3]. The fistulas develop in a sinus that has thrombosed and are thought to originate from small vessels that form in an organizing thrombus. Although most of these dural fistulas develop spontaneously, trauma and hypercoagulable states have been suggested as predisposing factors to the development of the fistulas [5]. In all our patients there was some degree of abnormal venous drainage. The connection between the inferior petrosal sinus and jugular bulb was occluded or stenosed, with most of the venous drainage directed superiorly into the cavernous sinus, or the connection between the cavernous sinus and inferior petrosal sinus was occluded and all flow was into the jugular bulb and superficial veins.

The presentation of patients with these lesions is related to the pattern of venous drainage. The usual case shows predominant outflow from the fistula into the cavernous sinus and then to the superior ophthalmic vein. The venous overload results in the same clinical picture of the much more common cavernous sinus arteriovenous fistula, with proptosis, ophthalmoplegia, and loss of vision [6–9]. In the one patient without flow superiorly into the cavernous sinus, the clinical syndrome was only bruit and headache. Although none of the patients presented with intracranial hemorrhage, one patient (patient 1) had a venous drainage pattern that is a risk for subarachnoid hemorrhage. Cortical venous drainage from a DAVF has been shown to be a risk factor for subarachnoid hemorrhage [6, 10–16]. Despite the small size of these fistulas, bruit was present in four of six patients. The proximity of the fistula to the ear may account for this symptom.

The clinical indications for treatment of DAVF of the inferior petrosal sinus are the same as for lesions of the cavernous sinus or other dural arteriovenous fistulas [6–13]. Four of the patients had worsening visual acuity or ocular movement paresis, with proptosis. The other patient had a loud, disabling bruit and headaches. The one patient with multiple DAVF (patient 6) had a cavernous sinus lesion that produced her clinical problems. Treatment was restricted to this symptomatic lesion, and the inferior petrosal sinus fistula was not treated.

The transvenous approach to embolizing these lesions has been most useful in achieving complete closure of the fistula. This technique has been shown to be successful in closing DAVFs at other sites and allows for the most direct approach

to the fistula [8–10, 17, 18]. Usually the fistulas drain into the ipsilateral jugular bulb, and this area can ordinarily be catheterized. The use of platinum coils has been shown to be successful in promoting thrombosis of DAVFs when placed into the venous drainage pathways. It is imperative that flow not be diverted into the orbit during embolization of these fistulas from the venous side. The embolic agents, usually coils or silk suture, must be placed in the inferior petrosal sinus between the fistula and the cavernous sinus. Although the pathway between the jugular bulb and inferior petrosal sinus may not always be evident angiographically, the small Tracker catheter and guidewire can often find a connection. It may be that some of these channels are filled with clot, and the Tracker catheter and guidewire can be gently pushed through these occluded pathways.

Two patients developed sinus thrombosis after the fistula was closed. This thrombosis is probably a result of the diminished flow into the sinus, with stasis and then thrombosis, or reflux of embolic agents (silk) into the jugular bulb. Damage to the sinus from catheters may be another cause of thrombosis, although this complication has not occurred during transvenous treatment of transverse or sigmoid sinus DAVFs.

The numerous arterial feeders make the transarterial approach difficult when the objective is to close the fistula completely. There are always numerous small arterial feeders, and occasionally the supply is bilateral. In addition, the anastomoses between the ascending pharyngeal artery and both internal and vertebral arteries may make transarterial embolization with liquid adhesives dangerous, and particulate embolic agents may not make a permanent occlusion. However, transarterial embolization is helpful in slowing down flow through the fistula, and may allow complete thrombosis even if the fistula is not completely obliterated at the time of the treatment. In four of the patients there was a small residual flow through the fistula at the termination of embolization, although complete thrombosis of the fistula eventually occurred, usually within 24 hr.

In summary, DAVFs of the inferior petrosal sinus are uncommon lesions that usually present with the same symptom complex as cavernous sinus DAVFs. Through the use of a combination of transvenous and transarterial embolization procedures these lesions may be cured with minimal risk to the patient.

REFERENCES

1. Newton TH, Cronqvist S. Involvement of the dural arteries in intracranial arteriovenous malformation. *Radiology* 1969;93:1071–1078
2. Chaudry MY, Sachdev VP, Cho SH, Weitzer I, Puljic S, Huang YP. Dural arteriovenous malformations of the major venous sinuses: an acquired lesion. *AJNR* 1982;3:13–19
3. Houser OW, Cambell JK, Cambell RJ, Sundt TM. Arteriovenous malformations affecting the transverse dural venous sinus: an acquired lesion. *Mayo Clin Proc* 1979;54:651–661
4. Sundt TM, Piepgras DG. The surgical approach to arteriovenous malformations of the lateral and sigmoid dural sinuses. *J Neurosurg* 1983;59:32–39
5. Brismar G, Brismar J. Spontaneous carotid cavernous fistulae: phlebographic appearance and relation to thrombosis. *Acta Radiol Diagn* 1976;17:180–192
6. Halbach VV, Hieshima GB, Higashida RT, Reicher M. Carotid cavernous fistulae: indications for urgent treatment. *AJNR* 1987;8:627–633
7. Halbach VV, Higashida RT, Hieshima GB, Reicher M, Norman D, Newton TH. Dural fistulas involving the cavernous sinus: results of treatment in 30 patients. *Radiology* 1987;163:437–442
8. Halbach VV, Higashida RT, Hieshima GB, Hardin CW, Yang PJ. Transvenous embolization of direct carotid cavernous fistulas. *AJNR* 1988;9:741–747
9. Halbach VV, Higashida RT, Hieshima GB, Hardin CW, Pribram H. Transvenous embolization of dural fistulas involving the cavernous sinus. *AJNR* 1989;10:377–383
10. Halbach VV, Higashida RT, Hieshima GB, Mehlinger CM, Hardin CW. Transvenous embolization of dural fistulas involving the transverse and sigmoid sinuses. *AJNR* 1989;10:385–392
11. Lasjaunias P, Ming C, Brugge KT, Atul T. Neurological manifestations of intracranial dural arteriovenous malformations. *J Neurosurg* 1986;64:724–730
12. Halbach VV, Higashida RT, Hieshima GB, Goto K, Norman D, Newton TH. Dural fistulas involving the transverse and sigmoid sinuses: results of treatment in 28 patients. *Radiology* 1987;163:443–447
13. Kosnik EJ, Hunt WE, Miller CA. Dural arteriovenous malformations. *J Neurosurg* 1974;40:322–329
14. Turner DM, Van Gilden JC, Mojtahedi S, Pierson EW. Spontaneous intracerebral hematoma in carotid cavernous fistula. *J Neurosurg* 1983;59:680–686
15. Vinuela F, Nombela L, Roach MR, Fox AJ, Pelz DM. Stenotic and occlusive diseases of the venous drainage system of deep brain AVMs. *J Neurosurg* 1985;63:180–184
16. Willinsky R, Lasjaunias P, Terbrugge K, Pruvost P. Brain arteriovenous malformations: analysis of the angio-architecture in relationship to hemorrhage (based on 152 patients explored and/or treated at the hospital de Bicetre between 1981 and 1986). *J Neuroradiol* 1988;15:225–237
17. Halbach VV, Higashida RT, Hieshima GB, Rosenblum M, Cahan L. Treatment of dural arteriovenous malformations involving the superior sagittal sinus. *AJNR* 1988;9:337–343
18. Halbach VV, Higashida RT, Hieshima GB, Wilson CB, Hardin CW, Kwan E. Treatment of dural fistulas involving the deep cerebral venous system. *AJNR* 1989;10:393–399