



Get Clarity On Generics

Cost-Effective CT & MRI Contrast Agents

**FRESENIUS
KABI**

[WATCH VIDEO](#)

AJNR

Reversal sign on CT: effect of anoxic/ischemic cerebral injury in children.

B K Han, R B Towbin, G De Courten-Myers, R L McLaurin and W S Ball, Jr

AJNR Am J Neuroradiol 1989, 10 (6) 1191-1198

<http://www.ajnr.org/content/10/6/1191>

This information is current as
of August 15, 2025.

Reversal Sign on CT: Effect of Anoxic/Ischemic Cerebral Injury in Children

B. Kim Han^{1,2}
 Richard B. Towbin³
 Gabrielle De Courten-Myers⁴
 Robert L. McLaurin⁵
 William S. Ball, Jr.¹

A retrospective study was performed to determine the clinical and pathologic features, etiology, and outcome of children with the reversal sign. The reversal sign, a striking CT finding, probably represents a diffuse, anoxic/ischemic cerebral injury. CT features of the reversal sign are diffusely decreased density of cerebral cortical gray and white matter with a decreased or lost gray/white matter interface, or reversal of the gray/white matter densities and relatively increased density of the thalami, brainstem, and cerebellum. Twenty children with the reversal sign were retrospectively analyzed. We divided the patients into three groups: (1) acute reversal, (2) intermediate group, and (3) chronic reversal. There were nine cases of trauma (seven of child abuse); nine hypoxia/anoxia incidents (birth asphyxia, drowning, status epilepticus); one bacterial meningitis; and one degenerative encephalitis. All acute- and intermediate-group patients had respiratory problems requiring ventilator support and intensive care. In five of seven patients who died, autopsy findings were consistent with anoxic/ischemic encephalopathy. Surviving patients have profound neurologic deficits with severe developmental delay. The CT reversal sign carries a poor prognosis and indicates irreversible brain damage.

AJNR 10:1191-1198, November/December 1989; *AJR* 154: February 1990

Received June 29, 1988; revision requested August 17, 1988; revision received May 8, 1989; accepted May 10, 1989.

Presented at the annual meeting of the International Society for Pediatric Radiology, Toronto, May 1987, and the International Society for Pediatric Neurosurgery, New York, July 1987.

¹ Department of Radiology, Children's Hospital Medical Center, Cincinnati, OH 45229.

² Present address: Department of Radiology, Rush-Presbyterian-St. Luke's Medical Center, 1653 W. Congress Parkway, Chicago, IL 60612. Address reprint requests to B. K. Han.

³ Department of Radiology, Children's Hospital of Michigan, Detroit, MI 48201.

⁴ Department of Pathology/Neuropathology, University of Cincinnati, College of Medicine, Cincinnati, OH 45267.

⁵ Department of Surgery, Section on Neurosurgery, Children's Hospital Medical Center, Cincinnati, OH 45229-2899.

0195-6108/89/1006-1191
 © American Society of Neuroradiology

An anoxic/ischemic insult may cause a variety of neuropathologic abnormalities, including neuronal necrosis, marmoration of basal ganglia and thalami, "watershed" infarcts, and periventricular leukomalacia [1-3]. Sonography and CT have been used as the primary imaging methods for evaluation of patients with acute anoxic/ischemic insults [4-13]. There are scattered reports describing diffuse cerebral edema on CT [14-17] and/or sonography [18]. We have noticed a distinctive CT appearance, the reversal sign, in a subgroup of patients with anoxic/ischemic cerebral injury. A few papers have reported similar CT findings [4, 6, 9] and increased echogenicity of the basal ganglia and thalami on sonography [10, 13].

The purpose of this study was to evaluate the clinical features, etiology, and outcome of the reversal sign in children. We have attempted to explain the pathophysiology of this disorder by correlating its pathologic features in 20 patients with the CT findings in 10 patients who had diffuse brain edema pattern and with the autopsy findings in 10 patients (five who had the reversal sign and five who had diffuse edema).

Materials and Methods

Twenty patients with the reversal sign on CT scan were retrospectively analyzed. The patient population consisted of eight girls and 12 boys, 3 weeks to 10 years old. The reversal sign was defined by diffusely decreased density of the cerebral cortical gray and white matter with a decreased or lost gray/white matter interface, or reversal of the normal gray/white matter densities and a relatively increased density of the thalami, brainstem, and cerebellum (Fig. 1).

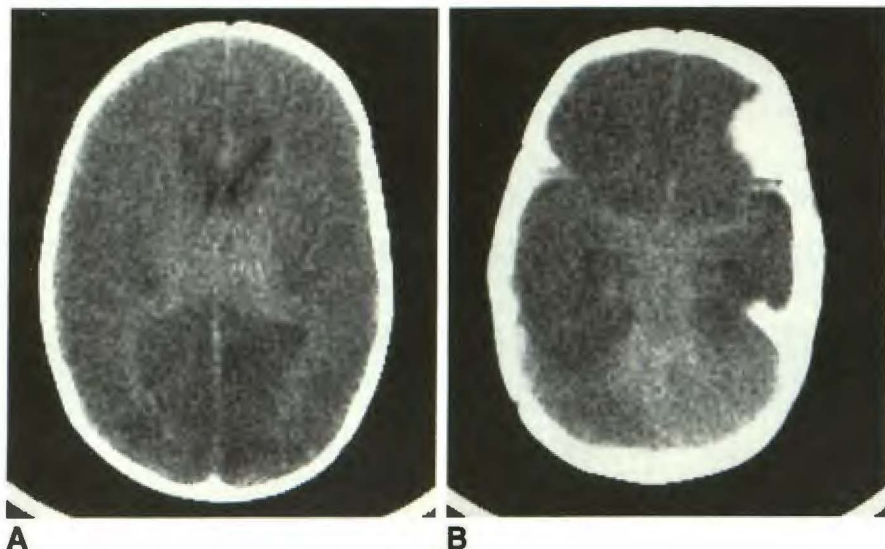


Fig. 1.—Acute reversal in 3-month-old abused child.

A and B, Axial CT scans show diffusely decreased density of cerebral cortex with relatively increased density of white matter causing reversal of gray/white matter densities. A relatively increased density is also seen in thalami, brainstem, and cerebellum.

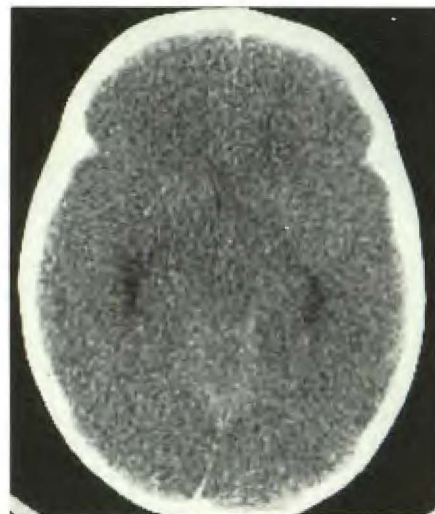


Fig. 2.—Diffuse edema in 1-year-old boy who presented with status epilepticus. Axial CT scan shows generalized decreased density throughout brain with lost gray/white matter interface. Ventricles are slitlike.

For comparison, the CT scans of a randomly selected group of 10 patients with diffuse brain edema pattern were evaluated. Diffuse edema was defined as generalized decreased density of the cerebrum with lost or diminished gray/white matter interface (Fig. 2). In this group, there were two girls and eight boys, ages 2 months to 9 years old.

All CT scans were obtained with a GE 8800 or 9800 scanner with contiguous 1-cm slices. Contrast-enhanced scans were obtained in nine patients. CT scans were reviewed qualitatively for gray and white matter density; sharpness of the gray/white matter interface; density of the basal ganglia, brainstem, and cerebellum; ventricular size and shape; and size of the extraaxial CSF spaces and cisterns.

Sonography was performed in 10 patients, ages 1 day to 11 months, on an ATL sector real-time unit in coronal and sagittal planes. Sonograms were reviewed for ventricular size, brain parenchymal echogenicity, sulci, and fissures.

The medical records of the children with the reversal sign and those with diffuse edema were reviewed for neurologic abnormalities, hospital course, etiology, and clinical follow-up.

The autopsy findings in 10 patients (five with reversal and five with diffuse edema) were reviewed. The extent and topographic distribution of the neuronal changes and edema in the cerebral cortex, cerebral hemispheric white matter, thalami, brainstem, and cerebellum were evaluated. Initially, we wondered if the low attenuation areas (e.g., cerebral cortex) on CT scans represented severely damaged brain and the relatively high attenuation areas (e.g., basal ganglia and thalami) represented less damaged brain. Therefore, the pathologic specimens were evaluated to see if there was any severity gradient in terms of neuronal damage and edema correlating with the CT findings.

Results

CT Findings

Patients with the reversal sign were divided into three groups. Group I (eight patients) were those with acute rever-

sal: these patients had the reversal sign on the CT scan performed at presentation (Fig. 1). Group II (six patients) was the intermediate group: these patients had diffuse edema at presentation changing to the reversal sign 2–22 days later (Fig. 3). Group III (six patients) consisted of those with chronic reversal: these patients had diffuse brain atrophy and/or cystic encephalomalacia with reversal sign (Fig. 4). In chronic reversal, the attenuation of the cerebral mantle is visually lower than in patients with acute reversal sign and has a density similar to that of CSF.

Follow-up CT findings are summarized in Figure 5. Four patients in group I had a follow-up CT scan 9 days to 3 weeks after presentation, and all showed chronic reversal sign (Fig. 6). Two of three patients in group II had a follow-up CT scan within 3–6 weeks that showed chronic reversal sign. In contrast, two patients with diffuse edema pattern had a follow-up within 4–6 weeks that showed diffuse brain atrophy but no reversal sign.

Contrast-enhanced scans were available in nine patients. None showed abnormal enhancement. In five patients, there was a subtle decrease in contrast between the areas of decreased attenuation and those of relatively increased attenuation resulting in a less apparent reversal sign (Fig. 7).

Clinical Data

Causes of reversal sign and diffuse edema pattern among our patients are summarized in Table 1.

In the reversal group, there were nine patients with trauma (seven resulting from child abuse), nine patients with anoxia (five caused by birth asphyxia, two cardiopulmonary arrests), and two others (one with viral encephalitis and one with degenerative encephalitis). All patients, with the exception of

Fig. 3.—4-month-old abused child in intermediate group.

A, Initial CT scan shows diffuse decreased attenuation throughout brain with lost gray/white matter interface consistent with diffuse edema. Subarachnoid hemorrhage is seen in interhemispheric fissure posteriorly.

B, 2 days later, CT scan shows generalized low attenuation throughout cerebrum, more severe on left. Relatively high attenuation is seen in region of basal ganglia, thalami, brainstem, and cerebellum.

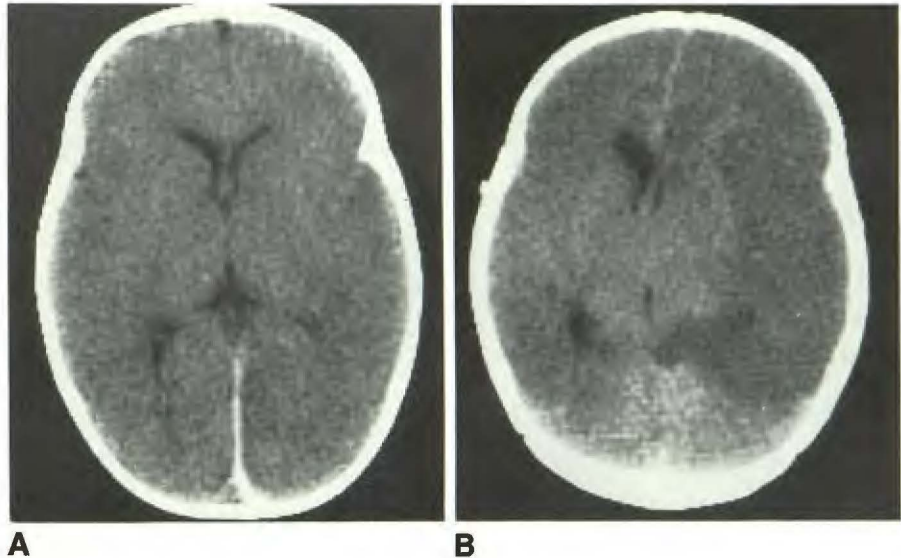
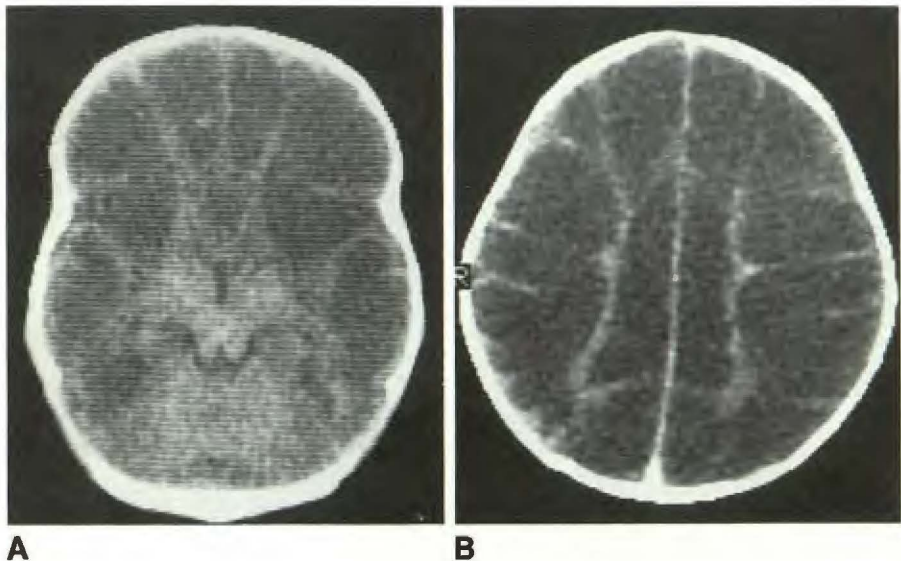


Fig. 4.—Chronic reversal in 3-week-old with history of fetal distress and birth asphyxia.

A and B, Axial scans show generalized decreased attenuation throughout brain with reversal of gray/white matter density. Density of parenchymal low attenuation areas was same as that of CSF, representing cystic encephalomalacia. Relatively high attenuation is seen in thalami, brainstem, and cerebellum. Volume of white matter is decreased.



one child in group III with degenerative encephalitis, had severe respiratory problems requiring ventilator support and a stay in the intensive care unit. Seven of the 20 patients with reversal sign died. Four of these were group I patients with acute reversal sign. One was a group II patient and two were group III patients with chronic reversal sign. All died within 7 days of the initial CT scan except for one with chronic reversal sign who died 5 weeks after the CT scan. All 13 surviving patients have profound neurologic deficits with severe developmental delay on clinical follow-up.

In the diffuse edema group, there were five patients with trauma (no cases of child abuse). Four patients suffered anoxic insults, including status epilepticus and drowning, and one patient had *Haemophilus influenzae* meningitis. All had severe respiratory problems requiring ventilator support and intensive care. Seven of 10 patients with diffuse edema died within 10 days of the initial CT scan. Two surviving patients

had severe neurologic deficits on clinical follow-up. One of three patients was lost to follow-up.

Sonographic Findings

Three patients had sonography during the acute stage of their illness. Four patients had sonography during the chronic stage. Three patients had serial sonography from the acute to chronic stages.

Four of six patients who had sonography during the acute illness, regardless of their classification on CT scan, showed a pattern of diffuse edema evidenced by increased parenchymal echoes, slit ventricles, and obliteration of sulci and fissures (Fig. 8). One patient had normal sonography during the acute illness. One patient with suspected aqueductal stenosis showed ventriculomegaly and evidence suggestive of diffuse

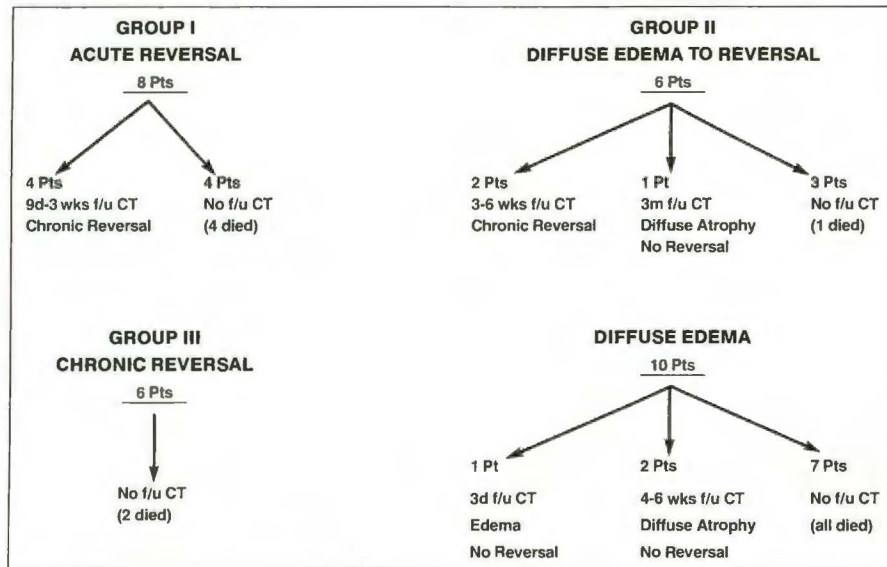


Fig. 5.—Follow-up CT findings in patients with reversal sign show progression of each group with time.

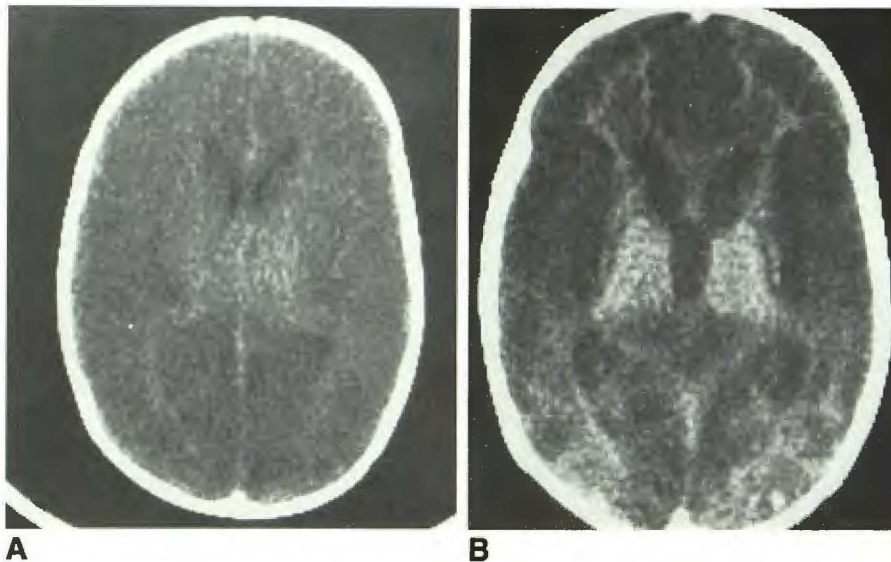


Fig. 6.—Acute to chronic reversal in 3-month-old abused child.

A, Initial CT scan shows acute reversal sign.
B, 2-week follow-up shows chronic reversal with evidence of brain atrophy.

brain edema. Among six patients who had sonography during their acute illness, one showed increased echogenicity in the caudate nucleus, and two showed subtle, increased echogenicity in the thalami. All seven patients who had sonography during the chronic stage showed evidence of diffuse brain atrophy. Four of them showed cystic encephalomalacia (Fig. 9). The caudate nucleus and thalami were diffusely echogenic in one patient (Fig. 9). The rest of the patients showed well preserved thalami even when there was extensive cystic encephalomalacia in the cerebral mantle.

Pathologic Findings

Reversal Group (five patients). In group I (four patients), two brain sections were available for study. One showed severe, acute neuronal necrosis and marked edema in the cerebral cortex and white matter. The other had petechial

hemorrhages within the brainstem, mild neuronal changes, and mild edema.

One patient in group II had extensive acute neuronal changes and edema without evidence of a severity gradient, either for neuronal damage or for edema. As in one group I patient, petechial hemorrhages were seen in the brainstem and cerebellum (Fig. 10).

Two brains with CT findings of chronic reversal (group III) were available for study. Both showed extensive gray and white matter atrophy with cyst formation and had a strong gradient of severity of damage decreasing from the cerebral hemispheres to the thalami, cerebellum, brainstem, and spinal cord (Fig. 11). In both cases, there was a prominent gliosis present in areas of neuronal loss. One brain showed severe neuronal depletion in the cerebral cortex, basal ganglia, and thalami. The latter two sites showed no cyst formation, but there were mineralized neurons in the thalami (Fig. 11C).

Fig. 7.—Acute reversal in 6-week-old abused child.

A, Precontrast scan shows reversal sign with relatively increased attenuation in basal ganglia, thalami, and brainstem. Subarachnoid and subdural hemorrhages are seen posteriorly.

B, Postcontrast scan shows subtle decrease in contrast between areas of decreased density and relatively increased density resulting in less apparent reversal sign. No area of significant enhancement is seen.

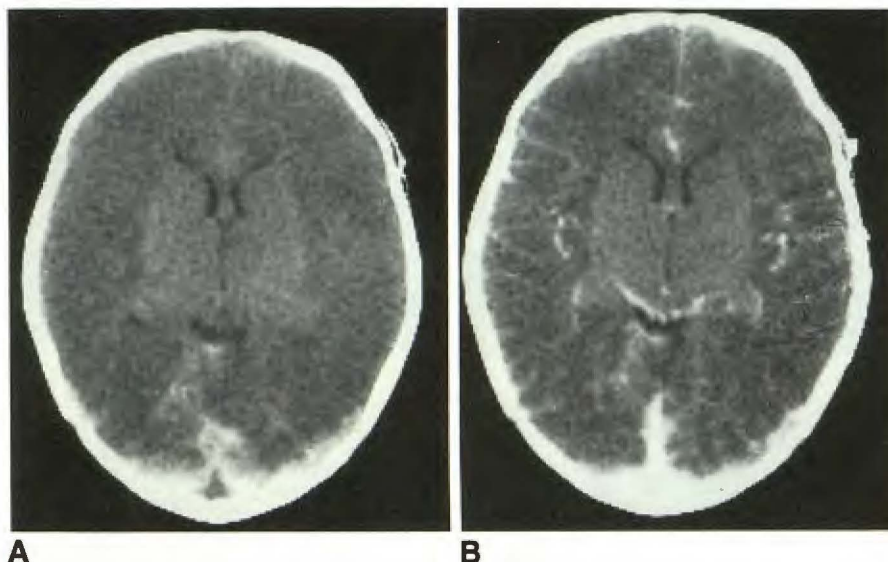


TABLE 1: Causes of Reversal Sign and Diffuse Edema

	Trauma	Anoxia	Other
Acute reversal	5 (3 child abuse)	3 (1 birth asphyxia)	0
Intermediate group	4 (4 child abuse)	1	1
Chronic reversal	0	5 (4 birth asphyxia)	1
Diffuse edema	5 (0 child abuse)	4	1

Diffuse Edema Group (five patients). All five patients showed a severe degree of gray and white matter edema and acute cytologic changes indicative of neuronal damage. In four of five cases, sufficient material was available to evaluate the topographic distribution and extent of neuronal changes and edema in the cerebral cortex, cerebral hemispheric white matter, thalami, brainstem, cerebellum, and cerebellar white matter. All four brains showed a definite gradient of neuronal changes most severely affecting the cerebral gray matter and to a much lesser degree the brainstem and cerebellum. In contrast, no gradient in the severity of edema was present in three of four patients in whom an approximately even degree of edema was seen supra- and infratentorially. These findings suggest that there is a good correlation between the extent of edema and decreased density on CT scans. However, the CT findings do not appear to correlate with the extent and distribution of neuronal damage. The fourth case revealed a normal cerebellum on CT that correlated with minimal neuronal changes and no evidence of edema in this site, whereas other structures, including thalami and brainstem, showed severe edema and moderately severe neuronal changes that correlated with decreased density on CT.

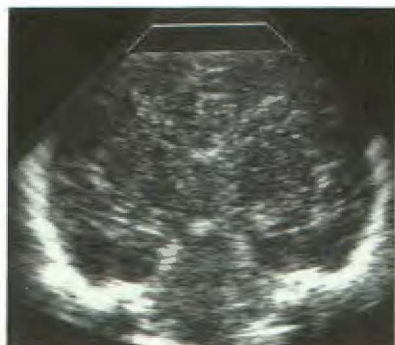Discussion

Over the last 6 years, we have noticed a distinctive CT appearance in a subgroup of patients with anoxic/ischemic

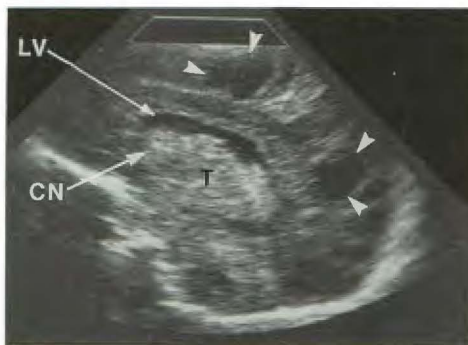injury, which we have termed the reversal sign. In children with the reversal sign, there is diffuse decreased attenuation of the cerebral cortex with a relative preservation of density in the thalami, brainstem, and cerebellum.

Shewmon et al. [4] reported four infants who showed areas of increased attenuation 1–2 weeks after severe brain ischemia; the structures most frequently involved were the basal ganglia and thalami, which enhanced after injection of contrast material. Autopsy of one infant revealed an extremely dense neovascular network that had almost completely replaced the parenchyma in the areas that showed increased attenuation on CT. These authors postulated that the hypoxia induces marked capillary proliferation in regions of normally high metabolism and capillary density. This pathologic change is a stage in the organization of ischemic brain damage reflecting the infant's vascular plasticity [4]. In our patients, however, none of those who had a contrast-enhanced scan showed significant enhancement in the areas of relatively high attenuation on precontrast scans. In fact, in five of nine patients who had contrast scans, there was a subtle decrease in the contrast between the central areas of relatively increased attenuation and the surrounding areas of decreased attenuation, resulting in a less apparent reversal sign.

In correlating the CT and pathologic findings in our patients with the reversal sign, we found that two patients with acute and intermediate reversal sign showed petechial hemorrhages in the areas of relatively increased attenuation on CT. In the chronic reversal group, the low attenuation areas on CT indicated severe brain atrophy with or without cyst formation, while the higher attenuation areas correlated with partially or totally preserved brain tissue. One patient with chronic reversal showed extensive neuronal loss with mineralized neurons within the thalami, which may explain the increased attenuation on CT. In the acute, diffuse edema group, the CT scan does not appear to provide information as to the extent and distribution of neuronal damage. However, there is good correlation between the extent of edema and low density on CT.



8



9

Fig. 8.—1-day-old baby with acute brain edema caused by severe birth asphyxia. Coronal sonogram shows diffuse increased parenchymal echogenicity, slit ventricles, and obliteration of sulci and fissures consistent with brain edema.

Fig. 9.—1-month-old baby with chronic changes of hypoxic/ischemic insult caused by severe birth asphyxia. Parasagittal sonogram shows echogenic caudate nucleus (CN), thalami (T), and areas of cystic encephalomalacia (arrows) in brain. LV = lateral ventricle.

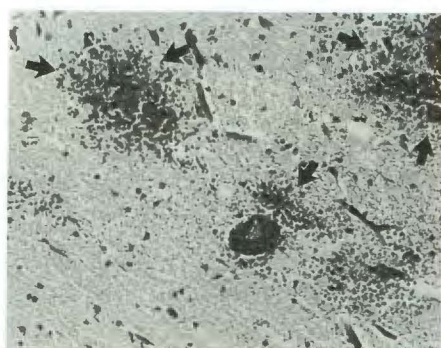

Fig. 10.—Pathology of 4-month-old abused child in intermediate group. Histomicrograph of brainstem shows petechial hemorrhages (arrows), possibly explaining increased density in this area on CT scan. Neuropilar vacuolization (edema) and acute neuronal changes also are seen.

The pathogenesis of the reversal sign is not known. However, there are several factors that may play an important role, including mechanical, hemodynamic, chemical, and metabolic factors. Myers [19], experimenting with asphyxia in newborn monkeys, suggested a mechanical factor for relative preservation of the central areas of brain. In an animal that was sacrificed 6 days after it was asphyxiated, the brain showed extensive tissue necrosis of all areas of the cerebrum, except for the thalami, hypothalami, and medial temporal lobes. The demarcation between the abnormal and intact tissue did not respect known nuclei, fiber tracts, or vascular territories (Fig. 12). According to a discussion of the subject by Myers [19], the central preservation is due to transtentorial herniation during the acute edema state. The pressure exerted by the expanding cerebral mass upon the tissue in the vicinity of the incisura would partially be relieved as herniation proceeds through the incisura. This locally reduced tissue pressure likely increases rather than decreases blood flow. The improved tissue perfusion may then delay or prevent tissue necrosis of the centrally placed region.

As discussed previously, Shewmon et al. [4] suggested postischemic hypervascularity as an explanation for increased attenuation in the basal ganglia and thalami. Bird et al. [9] recently reported three children with a reversal sign. The brain specimen in one of these children showed multiple distended deep medullary veins in the cerebral white matter, which showed increased density on CT scans. It was suggested that the reversal sign could be from distention of deep medullary veins caused by partial obstruction of venous outflow from elevated intracranial pressure.

Chemical and metabolic factors may be related to the pathophysiology of the reversal sign. It is known experimentally that serum glucose concentration and the duration of the anoxic insult is critical in determining both the occurrence of brain injury and its distribution [6, 20, 21]. The elevated serum (brain) glucose concentration during anoxia/ischemia causes preferential damage to the convexity cerebral cortex and basal ganglia with relative preservation of the thalami and brainstem. This is the frequently seen clinical pattern of anoxic/ischemic brain damage and it appears as one of the possible pathologic substrates resulting in the reversal sign on CT. In contrast, in slightly hypoglycemic experimental animals, a frequent pattern of anoxic/ischemic brain damage affects preferentially brainstem and thalami. The presence of increased serum glucose concentration changes the acute and chronic brain pathologic outcome dramatically. The reason for preferential damage to the cerebral cortex and basal ganglia in the hyperglycemic state has not been well understood. However, areas in which there is high metabolic activity have increased vulnerability to an anoxic/ischemic insult [22].

In comparing the reversal and diffuse edema groups, the acute and intermediate reversal groups appear to be highly associated with child abuse. Of the nine children who had head trauma resulting in acute or intermediate reversal signs, seven were considered to be abused children. In contrast, none of five children who had trauma in the diffuse edema group were abused. In a large percentage of abused children in this series, the reversal sign may have been caused by repeated, traumatic, edema-induced hypoperfusion of the brain, in turn, resulting in stress-induced hyperglycemic cerebral patterns of anoxic injury.

Only tentative conclusions from our pathology data appear warranted given the relatively small number of studies and the fact that no complete CNS examinations for topographic evaluation were available in patients with acute reversal sign and with initial diffuse low density followed by reversal sign. In the acute and subacute phases, the relatively high density of centrally located brain structures may correlate with (a) a lesser degree of edema and (b) the presence of petechial hemorrhages (Fig. 10), while (c) the extent of acute neuronal damage fails to correlate with CT density. In the chronic stage, a good correlation exists between cystic tissue de-

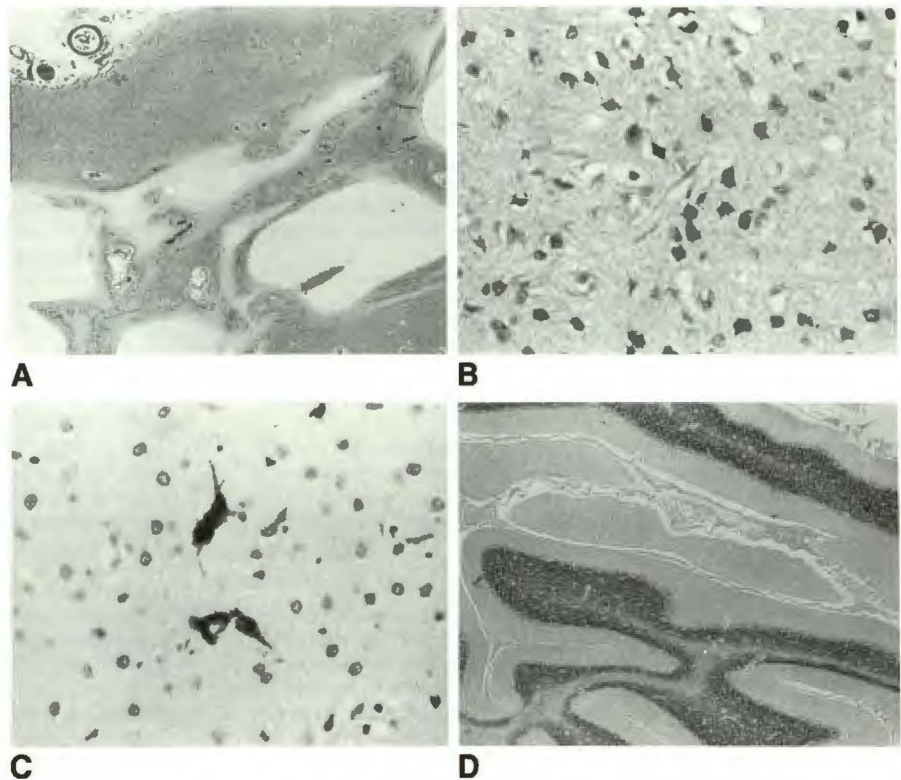
Fig. 11.—Pathology of chronic reversal shows gradient of severity of damage decreasing from cerebral hemispheres to thalami, brainstem, and cerebellum.

A, Cerebral cortex shows diffuse atrophy and contains practically no neurons. Cystic areas are surrounded by gliosis containing blood vessels and astrocytes.

B, Basal ganglia shows gliosis and neuronal loss. No cyst is seen.

C, Thalamus, which showed relatively high attenuation on CT scan, shows no preserved neurons, but has mineralized neurons.

D, Relatively well preserved cerebellum.



struction and low density areas on CT. Areas of relatively increased density on CT scan may also represent either preserved brain tissue or selective neuronal necrosis with mineralized neurons. The latter change occurs in areas of subtotal damage affecting a variable percentage of neurons and leading to calcium salt encrustation of some irreversibly damaged neurons, which nonetheless remain within the tissue (Fig. 11C).

Although children with both the reversal sign and diffuse edema pattern represent severe brain damage, a higher mortality rate was associated with the diffuse edema group. The

mortality was 35% in the reversal group (36% in reversal groups I and II) and 70% in the diffuse edema group. All the children with the reversal sign either died or suffered severe, irreversible brain damage.

The sonographic appearance of increased echogenicity in the thalami and basal ganglia has been described in term infants with a history of perinatal asphyxia [10, 13]. According to Hertzberg et al. [13], this finding was generally seen in the second week after asphyxia. In some of their reported cases, the increased thalamic echogenicity was a transient finding. Regardless of our classification on CT scan, sonography showed a generalized edema during acute illness and diffuse brain atrophy with or without cystic encephalomalacia in the chronic stage. Echogenic basal ganglia and thalami are seen in both acute and chronic stages. Unlike the CT scan, sonography failed to show distinct features comparable to the reversal sign on CT.

In summary, the reversal sign represents severe anoxic/ischemic brain injury and carries a poor prognosis with irreversible brain damage. The acute reversal sign is highly associated with child abuse. Possible explanations for reversal sign include preserved brain tissue, petechial hemorrhage, and mineralized neurons for high-density areas on CT, and severe edema and/or tissue destruction for low-density areas on CT.

ACKNOWLEDGMENTS

We thank Woo-Ki Jaun for her help with this project and Carol Amundsen and Jeri Yarbrough for manuscript preparation.

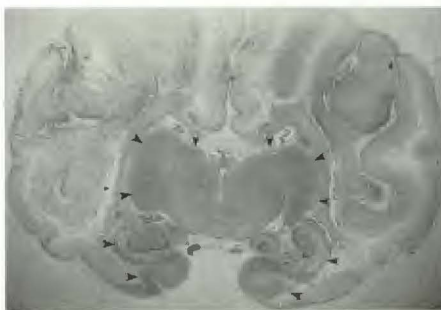


Fig. 12.—Coronal section of brain in newborn monkey killed 6 days after marked partial asphyxia. Extensive tissue necrosis of all areas of cerebrum is seen except for centrally located areas including thalami, hypothalami, and medial temporal lobes with definite demarcation (arrowheads). Demarcation between abnormal and intact tissue did not respect nuclei, fiber tracts, or vascular territories. (From [19]. Reproduced by permission of the publisher.)

REFERENCES

- Volpe JJ. Perinatal hypoxic-ischemic brain injury. *Pediatr Clin North Am* 1976;23:383-397
- Ingvar DH, Brun A, Johansson L, Samuelsson SM. Survival after severe cerebral anoxia with destruction of the cerebral cortex: the apallic syndrome. *Ann NY Acad Sci* 1978;315:184-214
- Dougherty JH Jr, Rawlinson DG, Levy DE, Plum F. Hypoxic-ischemic brain injury and the vegetative state: clinical and neuropathologic correlation. *Neurology* 1981;31:991-997
- Shewmon DA, Fine M, Masdeu JC, Palacios E. Postischemic hypervascularity of infancy: a stage in the evolution of ischemic brain damage with characteristic CT scan. *Ann Neurol* 1981;9:258-365
- Flodmark O, Becker LE, Harwood-Nash DC, Fitzhardinge PM, Fitz CR, Chuang SH. Correlation between computed tomography and autopsy in premature and full-term neonates that have suffered perinatal asphyxia. *Radiology* 1980;137:93-103
- Hirabayashi S, Kitahara T, Hishida T. Computed tomography in perinatal hypoxic and hypoglycemic encephalopathy with emphasis on follow-up studies. *J Comput Assist Tomogr* 1980;4:451-456
- Kjos BO, Brant-Zawadzki M, Young RG. Early CT findings of global central nervous system hypoperfusion. *AJNR* 1983;4:1043-1048
- Fitch SJ, Gerald B, Magill HL, Tonkin IL. Central nervous system hypoxia in children due to near drowning. *Radiology* 1985;156:647-650
- Bird CR, Drayer BP, Gilles FH. Pathophysiology of "reverse" edema in global cerebral ischemia. *AJNR* 1989;10:95-98
- Babcock DS, Ball WS Jr. Postasphyxial encephalopathy in full-term infants: ultrasound diagnosis. *Radiology* 1983;148:417-423
- Slovic TL, Shandaran S. Ultrasound in the evaluation of hypoxic-ischemic injury and intracranial hemorrhage in neonates: the state of the art. *Pediatr Radiol* 1984;14:67-75
- Huang C-C, Ho M-Y, Shen E-Y. Sonographic changes in a parasagittal cerebral lesion in an asphyxiated newborn. *J Clin Ultrasound* 1987;15:68-70
- Hertzberg BS, Pasto ME, Needleman L, Kurtz AB, Rifkin MD. Postasphyxial encephalopathy in term infants: sonographic demonstration of increased echogenicity of the thalamus and basal ganglia. *J Ultrasound Med* 1987;6:197-202
- Miller JD, Gudeman SK, Kishore PS, Becker DP. Computed tomography in brain edema due to trauma. *Adv Neurol* 1980;28:413-422
- Bruce DA, Alavi A, Bilaniuk L, Dolinskas C, Obrist W, Uzzell B. Diffuse cerebral swelling following head injuries in children: the syndrome of "malignant brain edema." *J Neurosurg* 1981;54:170-178
- Greenberg JO. Neuroimaging in brain swelling. *Neurol Clin* 1984;2:677-694
- Yoshino E, Yamki T, Higuchi T, Horikawa Y, Hirakawa K. Acute brain edema in fatal head injury: analysis by dynamic CT scanning. *J Neurosurg* 1985;63:830-839
- Smith SJ, Vogelzang RL, Marzano MI, Cerullo LJ, Gore RM, Neiman HL. Brain edema: ultrasound examination. *Radiology* 1985;155:379-382
- Myers RE. Experimental models of perinatal brain damage: relevance to human pathology. In: Gluck L, ed. *Intrauterine asphyxia and the developing brain*. Chicago: Yearbook Medical, 1977:37-97
- Richardson ML, Kinard RE, Gray MB. CT of generalized gray matter infarction due to hypoglycemia. *AJNR* 1981;2:366-367
- de Courten-Myers GM, Yamaguchi S-I, Wagner KR, Ting P, Myers RE. Brain injury from marked hypoxia in cats: role of hypotension and hyperglycemia. *Stroke* 1985;16:1016-1021
- Myers RE, de Courten-Myers GM. Metabolic principles of patterns of perinatal brain injury. In: Crawford JW, ed. *Risks of labour*. New York: Wiley, 1985:119-146