



**Get Clarity On Generics**

Cost-Effective CT & MRI Contrast Agents

**FRESENIUS  
KABI**

**WATCH VIDEO**

**AJNR**

## **Prevertebral Hematoma in Cervical Spine Injury: Incidence and Etiologic Significance**

L. Penning

*AJNR Am J Neuroradiol* 1980, 1 (6) 557-565

<http://www.ajnr.org/content/1/6/557>

This information is current as  
of August 27, 2025.

# Prevertebral Hematoma in Cervical Spine Injury:

## Incidence and Etiologic Significance

L. Penning<sup>1</sup>

In a consecutive series of 30 hospitalized cervical injury patients, 18 proved to have widening of the prevertebral soft tissue space due to hematoma. The upper limit of normal width in 50 noninjury patients was used as a reference. Hematoma almost exclusively manifested at C1–C4 and proved to be closely related to fractures of anterior elements of the spine. Relatively small hematomas were encountered in odontoid fractures and compression fractures of vertebral bodies; relatively large hematoma in disruptive hyperextension injury. Large hematomas are explained by extensive anterior ligamentous damage with rupture of larger blood vessels. As a rule, most hematomas disappeared within 2 weeks after the injury.

Injury of the cervical spine may be accompanied by marked increase in width of the prevertebral soft tissues, which is ascribed to edema or hematoma. The literature mainly deals with its possible complications such as dyspnea [1–3] and dysphagia [1, 2, 4]. The focus of this paper is exclusively on radiologic aspects, incidence, and possible relation to certain mechanisms of cervical spine injury. To my knowledge no such investigation has been reported.

### Anatomy of the Prevertebral Soft Tissue Space

The radiologic prevertebral space, projected between the vertebral column and the air shadows of pharynx and trachea, contains several anatomic structures (fig. 1). Covering the cervical spine are the anterior longitudinal ligament and prevertebral fascia, which more laterally are separated by the prevertebral muscles longus capitis and longus colli. Between prevertebral fascia and posterior wall of the pharynx (represented by constrictor pharyngis muscle), the slitlike retropharyngeal space is found, consisting of loose areolar tissue allowing the pharynx to move up and down with respect to the vertebral column during swallowing. Below the level of about C5 it continues as retrotracheal space. The space may be visible radiologically as a radiolucent line (prevertebral fat stripe) paralleling the anterior longitudinal ligament [5]. The radiologic soft tissues are much wider at the retrotracheal level than at the retropharyngeal level due to incorporation of the esophagus (fig. 1A). Anatomically, the retropharyngeal space, as shown on transverse sections of the neck (fig. 1B), extends more laterally than the retrotracheal space [6]; its functional capacity to harbor hematoma thus seems to be larger.

Hematomas are assumed to expand within the loose areolar tissue which, due to its texture, is liable to give way to dissecting pressure. Although prevertebral widening in cervical spine injury generally is ascribed equally to either hematoma or edema, I believe edema is less common, since the amount of local tissue seems too small to be able to cause significant edematous swelling. Therefore, the notions prevertebral widening and prevertebral hematoma are used synonymously.

Received February 20, 1980; accepted after revision July 7, 1980.

<sup>1</sup> Department of Diagnostic Radiology, University Hospital, Groningen, The Netherlands.

This article appears in November/December 1980 *AJNR* and March 1981 *AJR*.

*AJNR* 1:557–565, November/December 1980  
0195–6108/80/0016–0557 \$00.00

© American Roentgen Ray Society



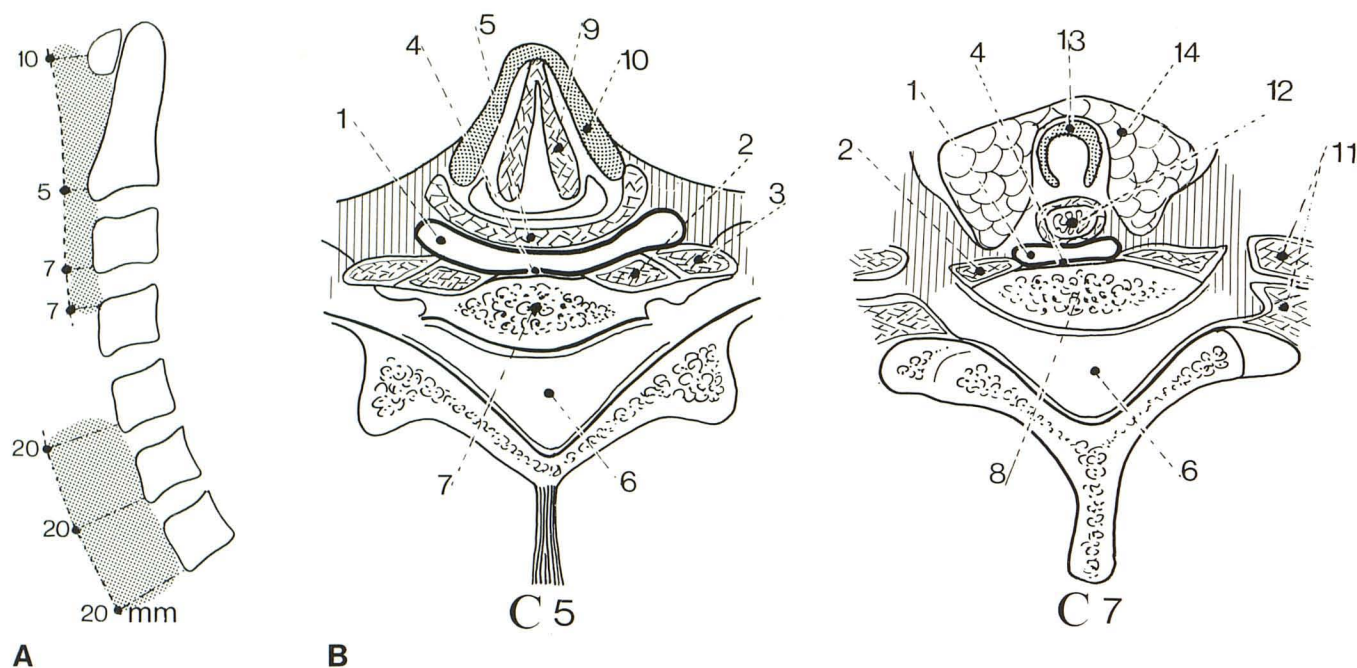


Fig. 1.—Normal prevertebral space. **A**, Upper limits of normal width (see table 1 for range). Measurements made along lines perpendicular to air shadow of pharynx and trachea. Larger measurements considered evidence of prevertebral widening due to hematoma. Normal retropharyngeal space markedly smaller than retrotracheal space. **B**, Anatomic transverse sections of neck (modified from [6]) at levels of C5 and C7. Lateral extension of prever-

tebral space (1) greater in retropharyngeal (C5) than retrotracheal (C7) section. 2 = longus capitis muscle, 3 = longus colli muscle, 4 = prevertebral fascia blending with anterior longitudinal ligament, 5 = constrictor pharyngis muscle, 6 = vertebral canal, 7 = body of C5, 8 = body of C7, 9 = vocal cord, 10 = thyroid cartilage, 11 = scaleni muscle group, 12 = esophagus, 13 = tracheal ring, 14 = thyroid gland.

## Materials and Methods

Measurement of prevertebral width was performed in a random series of 50 radiographs of the cervical spine in adult (average age, 46 years; range, 15–78 years) noninjury patients (normal except for cervical spondylosis) (fig. 1A). Measurements were made along lines describing the shortest distance between: (1) the anterior arch of the atlas and the anterosuperior or anteroinferior edges of the vertebral bodies C2–C7 and (2) the air shadows of pharynx and trachea. If anterior spondylotic spurs were present at these sites, measurements were made from the anterior aspect of the vertebral body, not the spur. The region of the laryngopharynx between the upper border of C4 and lower border of C5 was excluded from the investigation because its air configuration often is too variable to make reliable measurements. No correction was made for radiologic magnification which, with this technique (film distance, 120 cm; shoulder against cassette holder), amounted to a factor of about 1.3.

To exclude a possible influence of posture, measurements were also made on flexion-extension radiographs of 20 adults (average age, 31 years; range, 16–67 years), five of whom were in the injury group, but all had normal prevertebral width in midposition (table 1). Measurement of prevertebral width in injury patients was performed the same way as in normals. However, no measurements were made in front of a teardrop fracture or luxation, since widening here could be wholly or partly due to vertebral displacement. Consequently, table 2 does not indicate whether prevertebral hematoma was present at the level of injury (e.g., at C4 in case of teardrop fracture C4). To determine the time of maximal prevertebral widening after the injury and the rate of its subsequent decrease and disappearance, all available radiographs were used for mea-

TABLE 1: Normal Prevertebral Soft Tissue Width

Level	Average Width (Range) (mm)		
	Flexion	Midposition	Extension
C1	5.6 (2–11)	4.6 (1–10)	3.6 (1–8)
C2	4.1 (2–6)	3.2 (1–5)	3.8 (2–6)
C3	4.2 (3–7)	3.4 (2–7)	4.1 (3–6)
C4	5.8 (4–7)	5.1 (2–7)	6.1 (4–8)
C5	17.1 (11–22)	14.9 (8–20)	15.2 (10–20)
C6	16.3 (12–20)	15.1 (11–20)	13.9 (7–19)
C7	14.7 (9–20)	13.9 (9–20)	11.9 (7–21)

Note.—Sites of measurement shown in figure 1A.

surement, but only measurements on the radiographs showing maximal widening are reported.

## Types of Injuries

Investigation of the prevertebral space was performed in a consecutive series of 30 hospitalized cervical injury patients. In view of a possible correlation between incidence of prevertebral swelling and type and/or mechanism of injury, the series was subdivided into seven groups (table 2).

### Odontoid Fracture

Fracture of the odontoid process is ascribed to sudden forward or backward movement of the head, with the neck

TABLE 2: Types of Injuries with Prevertebral Widening

Types of Injury/Case No.	No. of Days after Injury	Prevertebral Widening		Maximum Width (mm)	Special Features
		Localization			
		Levels	Maximum		
Odontoid fracture:					
1	—	—	—	—	Posterior displacement, 7 mm
2	0	C1–C2	C2	1	Anterior displacement, 2 mm
3	1	C1–C2	C2	3	Posterior displacement, 3 mm
4	3	C2–C4	C2	4	No displacement
5	0	C2	C2	5	Posterior displacement, 5 mm
6	2	C2–C4	C2	8	Anterior displacement, 13 mm
Hangman fracture:					
7	—	—	—	—	Neural arch, C2 only
8	3	C2–C3	C2	2	Neural arch, C2 only
9	1	C1–C4	C3	11	Neural arch, C2; anteroinferior avulsion, body C2; fracture, posterior arch C1
Hyperflexion sprain:					
10	—	—	—	—	Widening of interspinous space, C2–C3
11	—	—	—	—	Widening of interspinous space, C3–C4
Compression of vertebral bodies:					
12	—	—	—	—	Teardrop fracture, C5
13	—	—	—	—	Teardrop fracture, C6
14	3	C3–C4	C3	7	Comminution, base of axis
15	2	C2–C3	C3	4	Wedge fracture, C4
16	0	C3	C3	3	Teardrop fracture, C4
17	0	C3–C4	C4	8	Teardrop fracture, C5
18	2	C2–C4	C4	3	Wedge fractures, C5 and C6
19	2	C2–C4	C4	2	Teardrop fracture, C6
20	2	C5–C6	C6	2	Teardrop fracture, C7
Interlocking of articular facets:					
21	—	—	—	—	Unilateral, C3–C4
22	—	—	—	—	Bilateral, C6–C7
23	—	—	—	—	Bilateral, C6–C7; fracture, spinous process C6
C24	—	—	—	—	Bilateral, C6–C7; anterosuperior avulsion, body C7; bilateral fracture, arch C6, fracture, posterior arch, C1
C25	3	C1–C4	C2	6	Unilateral, C3–C4; compression, body C4
Compression of articular facets:					
26	—	—	—	—	Unilateral C4
27	—	—	—	—	Unilateral C5
Hyperextension sprain:					
28	3	C1–C4	C2	11	Avulsion, spondylotic spurs C2–C5
29	0	C1–C4	C2	12	Avulsion fractures, bodies C2 and C4
30	1	C1–C4	C2	15	Avulsion fractures, bodies C4–C6; fracture, spinous process C5

Note. — = no widening; maximum width means above normal upper limit.

rigidly erect and articulations locked [7–9]. As a rule there is a larger or smaller degree of anterior or posterior displacement of the odontoid process with respect to the body of the axis (fig. 2). Fractures may be of the high type (fracture line remaining limited to the odontoid itself) or the low type (fracture line extending laterally into the articular masses and lateral joints) [10, 11].

#### Hangman Fracture

The typical bilateral fracture of the neural arch of the axis is believed to be caused by hyperextension [1, 12, 13] (figs.

3A and 3C). Additional posterior compression [14] is evidenced by fracture of the posterior arch of the atlas. Avulsion of the anteroinferior edge of the axial body (*extension teardrop fracture* [8]) indicates additional anterior disruption (figs. 3B and 3D).

#### Hyperflexion Sprain

The mechanism of injury for this sprain [15] is hyperflexion with disruption of posterior ligaments, but the stage of interlocking of articular facets (fig. 4B) is not reached.



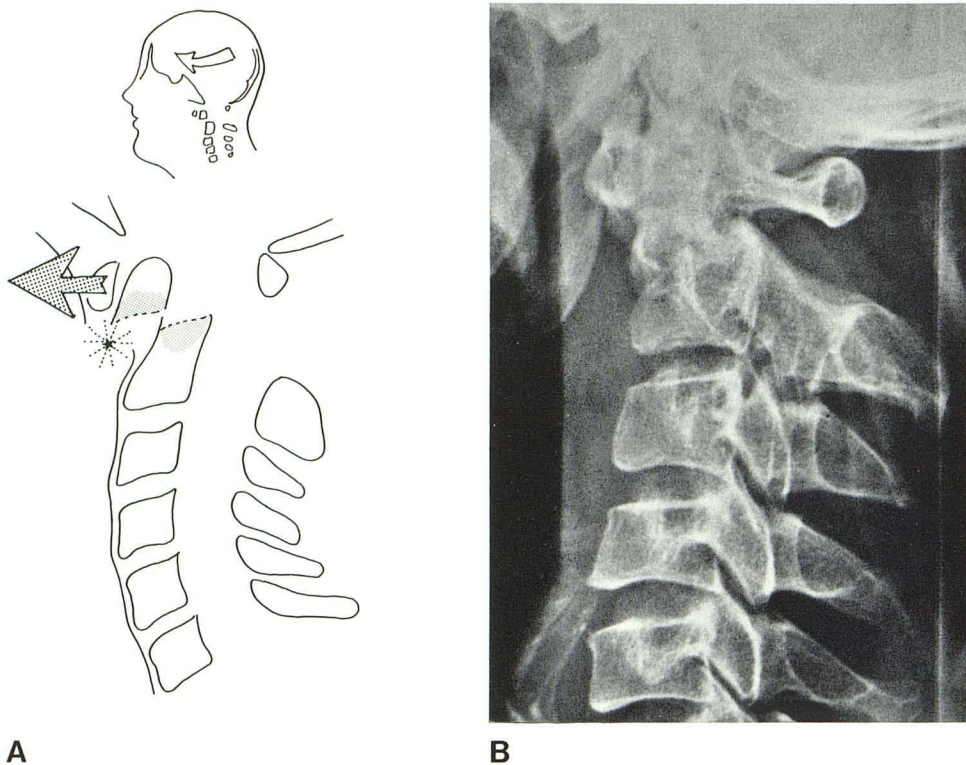


Fig. 2.—Odontoid fracture. A, Mechanism of injury. Odontoid fracture caused by sudden forced anterior (or posterior) movement of head with spine rigidly fixed. Supposed source of prevertebral hematoma (*asterisk*). B, Case 6, 2 days after injury. Low-type odontoid fracture with 13 mm anterior displacement. Prevertebral soft tissue widening at levels C2–C4.

Radiologically the lesion is evidenced by kyphotic angulation of the cervical spine with widening of one or two interspinous spaces [16]. Avulsion fractures of spinous processes may be present. As a rule damage remains limited to the posterior elements of the spine, although incidentally slight wedge compression of vertebral bodies may be encountered.

#### *Compression Fracture of Vertebral Body*

This type of injury is caused by hyperflexion with compression of the anterior elements of the cervical spine [16] (figs. 4A and 4C). The compressed body may have the form of a simple wedge. Sometimes the anterior part is pinched off (*teardrop fracture*). Incidentally, the whole body may be comminuted. Compression fracture is occasionally found in unilateral interlocking (fig. 4D).

#### *Interlocking of Articular Facets (Hyperflexion Luxation)*

The causing mechanism is hyperflexion with local disruption of posterior ligaments and articular capsules. There is a varying severity of vertebral displacement with rupture of intervertebral disc and longitudinal ligament. Local avulsion fracture of a vertebral body or fractures of arches or spinous processes may occur (fig. 4B). In unilateral interlocking, hyperflexion is thought to be combined with rotation; additional anterior compression may be evidenced by fracture of a vertebral body (fig. 4D).

#### *Compression of Articular Facets*

This is caused by hyperextension with compression of posterior elements of the cervical spine [16] (fig. 5A). My material is confined to unilateral compression of articular facets, in which compressive hyperextension is thought to have been combined with rotation.

#### *Hyperextension Sprain*

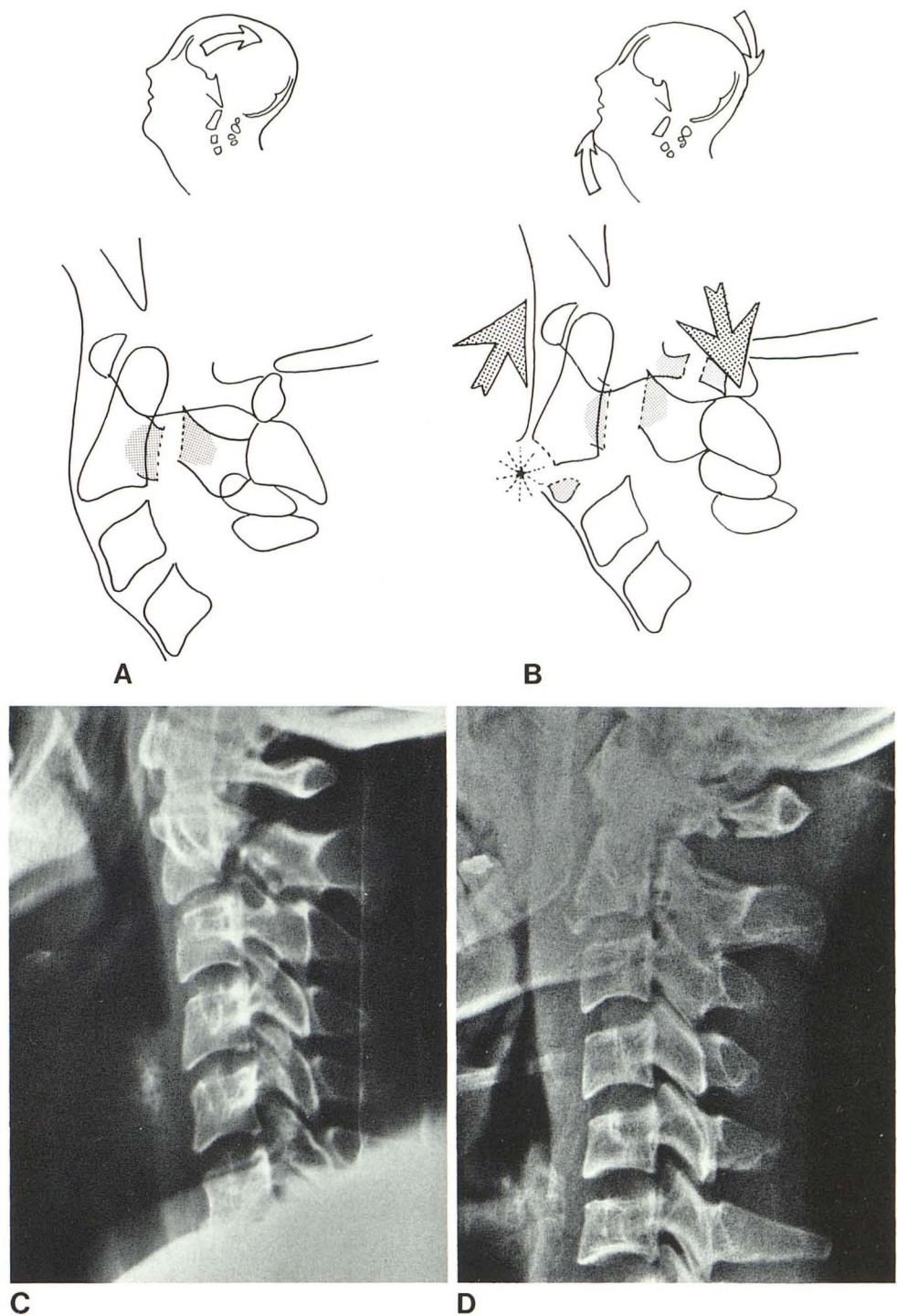
This type of injury [17] is caused by hyperextension with disruption of anterior ligaments and discs (figs. 5B and 5C); after the injury the cervical spine tends to resume its normal position. The mechanism of injury [18] may be evident from small avulsion fractures of vertebral bodies, avulsed spondylotic spurs [15], or ossifying vertebral rims [19]. Anterior widening of an intervertebral disc or lucent cleft [20] may be noted. Often the paucity of radiologic signs in this type of injury contrasts with the severity of the neurologic picture caused by pinching of the cord [21].

#### **Results**

There is a rather wide range of normal prevertebral tissue width (table 1), which is why the upper limits of normal values were chosen as reference for abnormal width. This has the additional advantage that the influence of posture of the cervical spine is eliminated because the upper limits of prevertebral width in maximal flexion or extension do not exceed those in midposition by more than 1 mm.



Fig. 3.—Hangman fracture. **A**, Mechanism of injury. Fracture of neural arch of axis caused by hyperextension. Anterior longitudinal ligament should have remained intact. **B**, Mechanism of injury with additional anterior disruption causing rupture of anterior longitudinal ligament and avulsion fracture of body of C2. Additional posterior compression responsible for fracture of posterior arch of atlas. Supposed source of prevertebral hematoma (asterisk). **C**, Case 7, 3 days after injury. Bilateral fracture of neural arch C2. Normal prevertebral space indicates absent anterior disruption. **D**, Case 9, 1 day after injury. Bilateral fracture of neural arch C2 and fracture of posterior arch of atlas. Large prevertebral hematoma C1–C4 explained by anterior disruption, as evidenced by avulsion of anteroinferior edge of body C2.



The prevertebral space was found to be widened in 18 of the 30 injury patients (table 2). Widening was found to be maximal on the first radiographs (within 0–3 days after injury) in 17 cases. In case 28, widening increased between days 1 and 3. Widening was noted in all groups except hyperflexion sprain and compression of articular facets. Incidence of widening was high in odontoid fractures, compression fractures of vertebral bodies, and hyperextension sprain.

Average widening (above upper limit of normal) was relatively small in odontoid fractures (4.2 mm) and compression fractures of vertebral bodies (4.1 mm), but notably large (12.3 mm) in avulsion fractures of vertebral bodies due to hyperextension sprain or hangman fracture. Irrespective of the site of the vertebral lesion, prevertebral widening was only found in the upper cervical region C1–C4, except for case 20, which was at C5–C6. Maximum widening tended to be present at C2 in lesions of the upper

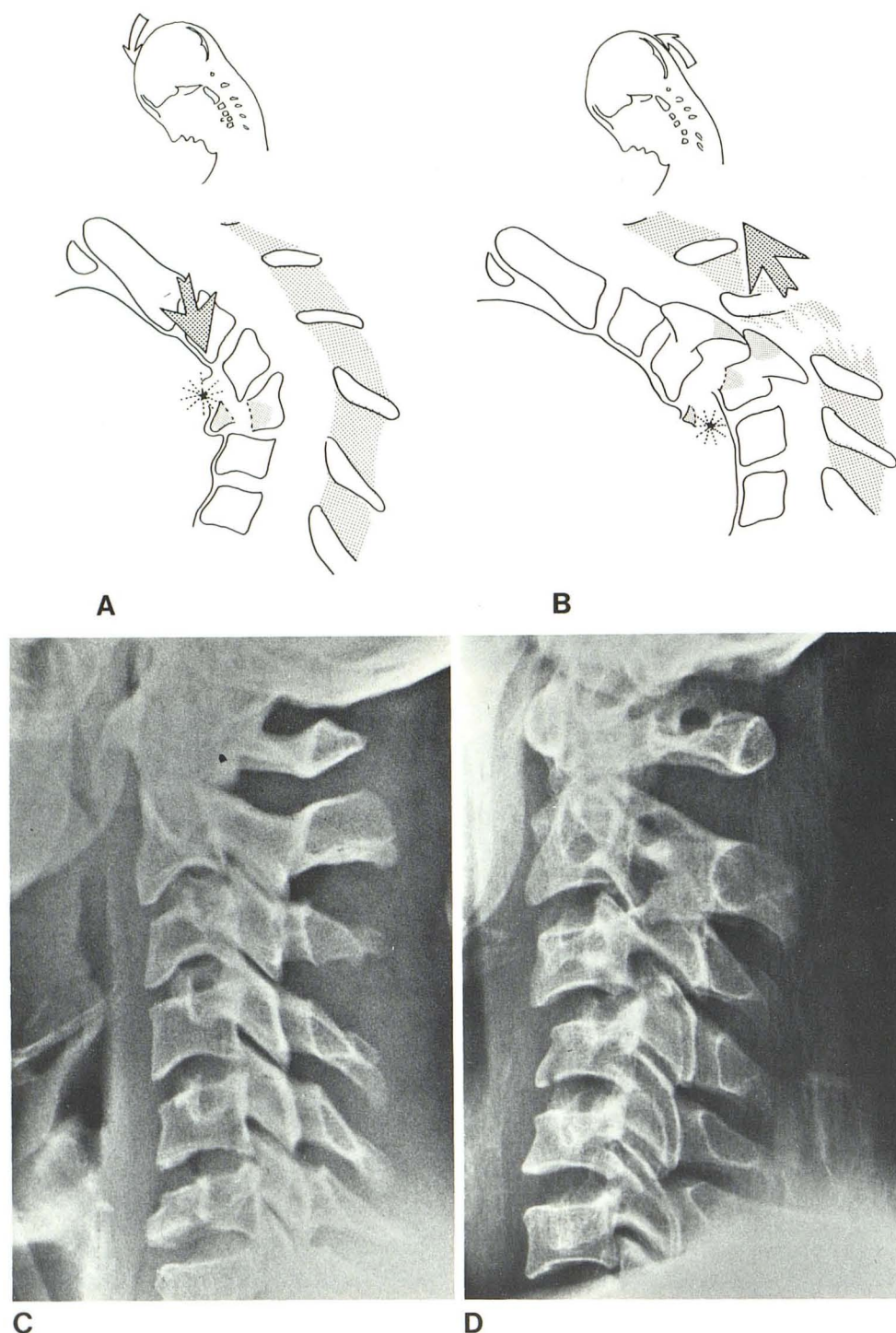


Fig. 4.—Hyperflexion injury of lower cervical spine. **A**, Mechanism of injury in compression fracture of vertebral body. Hyperflexion with compression leaves posterior ligaments intact but causes compression fracture of vertebral body with local damage of anterior ligament. Source of prevertebral hematoma (asterisk). **B**, Mechanism of injury in bilateral interlocking of articular facets. Hyperflexion with posterior disruption results in local rupture of interspinous ligaments and interlocking of articular facets. Marked vertebral luxation may occur with rupture of anterior longitudinal ligament and avulsion fracture of vertebral body. Potential source of prevertebral hematoma (asterisk). In unilateral interlocking, rotation is thought to play a role; additional compression may be evidenced by fracture of a vertebral body. **C**, Case 19, 2 days after injury. Compression of vertebral body C6 with slight prevertebral widening C2-C4. Absence of prevertebral widening at fracture site explained by large range of normal prevertebral width and tendency of hematoma to remain relatively small in C5-C7 region. **D**, Case 25, 3 days after injury. Unilateral interlocking C3-C4. Prevertebral hematoma C1-C4 explained by fracture of vertebral body C4. Supposed mechanism of injury is disruptive hyperflexion with rotation and compression.

cervical spine and at C4 in lesions of the lower cervical spine.

Follow-up studies of prevertebral widening were possible in 15 cases. It tended to decrease rapidly during the first week to become normal or nearly normal (not more than 2 mm above the normal upper limit) within the first 2 weeks in eight cases and within the first 3 weeks in five more cases.

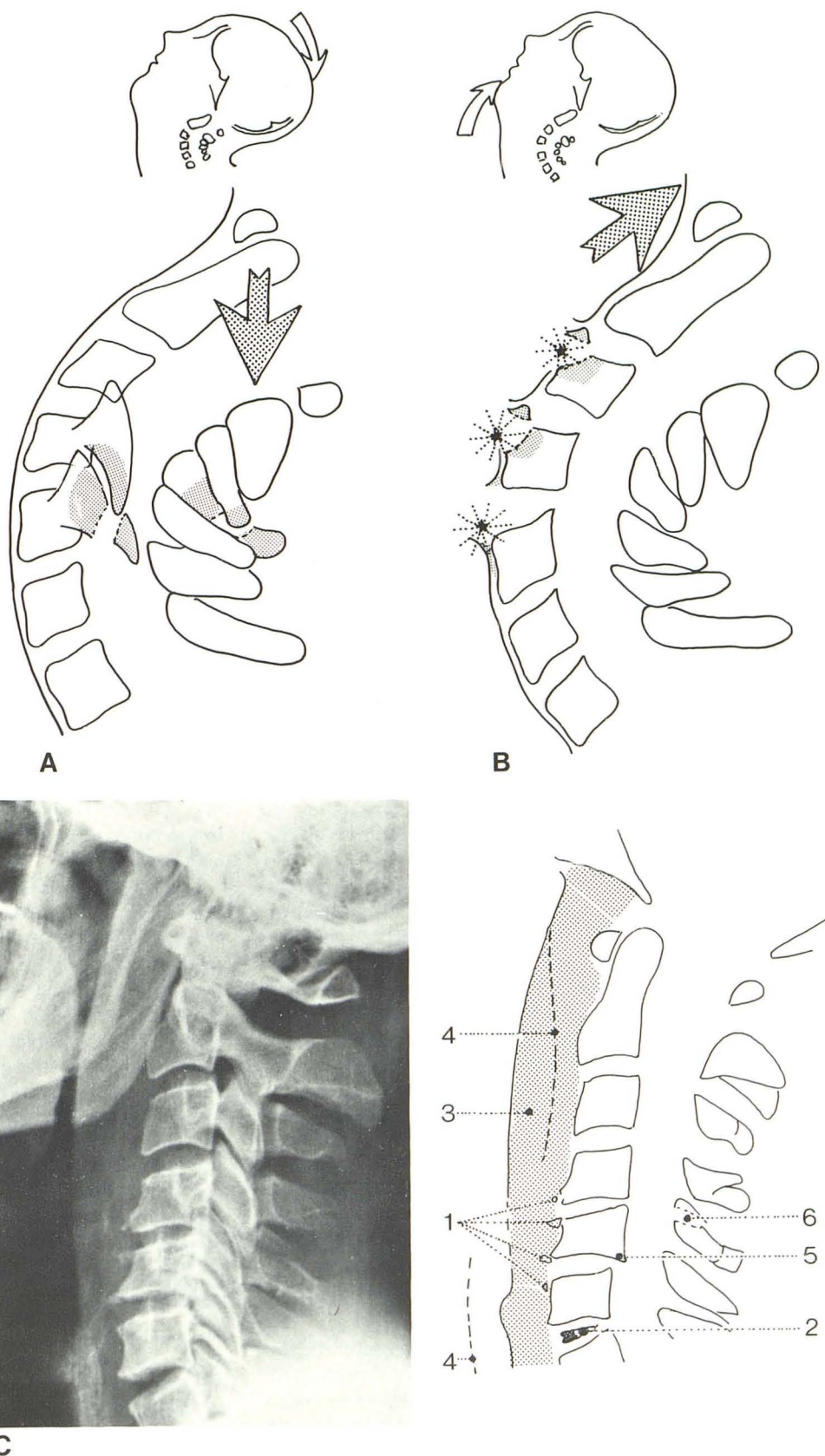
In case 6, the width at the lower level of C2 diminished to nearly normal after 7 weeks and to normal after 9 weeks.

#### Discussion

Normal values of prevertebral soft tissue width have been measured by several authors [21-25], but pertain to one or



Fig. 5.—Hyperextension injury of lower cervical spine. **A**, Hyperextension with posterior compression resulting in compression fractures of articular or spinous processes. Intact anterior longitudinal ligament explains absence of prevertebral hematoma. **B**, Hyperextension with anterior disruption (hyperextension sprain) results in several ruptures of anterior longitudinal ligament and avulsion fractures of vertebral bodies. Supposed sources of prevertebral hematoma (asterisks). **C**, Case 30, lateral view, 1 day after injury that resulted in permanent transverse lesion of cord below C5. Several small avulsion fractures of anterior edges of C4, C5, and C6 (1) and anterior widening of disc space C6–C7 with radiolucent cleft (2). Large prevertebral swelling C1–C4 (3); limit of normal prevertebral width indicated by interrupted line (4). Findings favor hyperextension as causative mechanism; anterior avulsions result from rupture of anterior longitudinal ligament due to overstretching and perhaps also by vigorous contraction of anterior neck musculature; pinching of cord in extension caused by abnormal backward movement of bodies C5 and C6 promoted by spondylotic retrolisthesis C5–C6 (5) and traumatic disruption of disc C6–C7 (2); fracture of spinous process C5 (6) explained by additional compression of posterior elements of cervical spine.





two cervical levels only. For diagnosis of prevertebral widening in injury patients, the need for normal values at all levels was recognized. Moreover, the influence of posture, often altered in cervical spine injury, had to be ascertained. Hay (cited in [22]) expressed his measurements as multiples of the anteroposterior width of the C4 vertebral body to account for varying radiologic magnification. However, this more time-consuming approach does not enhance reliability, since C4 width is not of constant magnitude. Measurements in children were not made since all injury patients were at least 14 years old. According to Markuske [24], normal prevertebral width under this age is larger at the retropharyngeal level and smaller at the retrotracheal level.

By using the upper limit of normal prevertebral width for reference, small hematomas may be missed. This is particularly true for the C5–C7 region, which has a large spread of normal values (table 1), and may help explain why prevertebral hematoma was only exceptionally manifested here, despite the presence of local vertebral injury with evidence of prevertebral hematoma at higher levels. Perhaps a more rigid fixation of the trachea (as compared with the laryngopharynx) preventing anterior displacement may play an added role. Moreover, the functional capacity of the retrotracheal space, as compared with the retropharyngeal space, seems to be smaller (fig. 1B). It is assumed that in some cases hematoma spread upward unnoticed until it was radiologically manifested at C4 and higher levels. Maximum widening at C4 supports the assumption that hematoma originated at the site of injury. In lesions at higher levels, as a rule, maximum prevertebral widening was found at C2 or C3. Cases 28 and 30, with vertebral lesions at several levels, provide further evidence that hematoma tends to manifest itself at C4 and higher levels only, and not at C5–C7 (fig. 5C).

Etiologically, prevertebral hematoma proved to be almost exclusively found in fractures of the odontoid process or vertebral bodies, being absent in only a small proportion of these lesions (table 2). Presumably, prevertebral hematoma is produced because these injuries involve the anterior aspect of the cervical spine. Fractures of the arches and articular or spinous processes did not produce prevertebral hematoma unless they were combined with fractures of the vertebral bodies.

Of interest is the relation between large prevertebral hematoma and disruptive hyperextension as it exists in hyperextension sprain (figs. 5B and 5C) and hangman fracture with anteroinferior avulsion of C2 (figs. 3B and 3D). Average size of prevertebral hematoma in odontoid fractures and vertebral body compression fractures proved to be significantly smaller. The difference must be explained by the extensive laceration of the anterior coverings of the cervical spine in disruptive hyperextension [26].

As a whole, the anterior longitudinal ligament and prevertebral fascia are overstretched and often will rupture at several sites, as evidenced by the multiplicity of avulsion fractures. Hematoma is probably the result of disruption of larger blood vessels covering the anterior aspect of the vertebral column, since the ligaments themselves are poorly

vascularized and the avulsion fractures are of insignificant size. In odontoid fractures and hyperflexion compression fractures of vertebral bodies, anterior ligamentous damage will be less severe since it is not caused by overstretching of the ligaments as a whole and tends to remain limited to the level of the injury (figs. 2 and 4). In these cases, hematoma is considered to be directly related to the fracture; more extensive fractures (as in the low type odontoid fracture) tend to produce larger hematomas.

Stewart et al. [27] suggested that ligamentous osseous lesions may be caused by vigorous contraction of the anterior neck musculature as a defense mechanism in sudden hyperextension. Such avulsion injury caused by muscular action may be added to local rupture of ligaments due to passive overstretching by hyperextension. In exceptional cases injury to pharynx or esophagus [4] may contribute to the production of hematoma.

Prevertebral widening without fracture of anterior elements of the cervical spine was encountered only once (case 8). In this case, hematoma may be explained by anterior ligamentous disruption of C2–C3 without avulsion fracture of the body of C2 (figs. 3A and 3B).

Several authors [2, 24, 28, 29] emphasized that prevertebral hematomas in trauma serve as a general clue to injury of the cervical spine (e.g., in the absence of clear-cut fractures or luxations or in the differential diagnosis of congenital anomalies). In cases 28–30, fractures were insignificant and could easily have been missed. The finding of prevertebral hematoma in such cases draws attention to the possibility of hyperextension injury. Odontoid fracture without displacement also has to be considered. Absence of prevertebral hematoma does not exclude significant injury to the cervical spine, but makes disruptive hyperextension less likely.

The natural history of prevertebral hematoma indicates that it must be considered as a sign of relatively recent injury. Significant hematoma was not found later than 2–3 weeks after the injury. Case 6 is an exception but abnormal widening after 3 weeks was found here only at the lower level of C2, close to the low type odontoid fracture with marked anterior displacement (fig. 2B). In cases of uncertain injury, other causes of prevertebral widening, such as infection or tumor, should be considered. Of special interest is the increase of hematoma in case 28, most probably due to flexion-extension studies erroneously performed as the result of a missed diagnosis of hyperextension sprain. Rebleeding in this case is explained by reopening of ruptured vessels on the anterior surface of the cervical spine during extension.

#### REFERENCES

1. Schneider RC, Livingston KE, Cave AJE, Hamilton G. "Hangman's fracture" of the cervical spine. *J Neurosurg* 1965;22:141–154
2. Elliot JM, Roger LF, Wissinger JP, Lee JF. The hangman's fracture. Fractures of the neural arch of the atlas. *Radiology* 1972;104:303–307
3. Gehweiler JA, Duff DE, Martinez S, Miller MD, Clark WM.



- Fractures of the atlas vertebra. *Skeletal Radiol* **1976**;1:97-102
4. Morrison A. Hyperextension injury of the cervical spine with rupture of the esophagus. *J Bone Joint Surg [Br]* **1960**;42:356-357
  5. Whalen JP, Woodruff CL. The cervical prevertebral fat stripe—a new aid in evaluating the prevertebral soft tissue space. *AJR* **1970**;109:445-451
  6. Pernkopf E. *Atlas der Topographischen und angewandten Anatomie des Menschen. Band 1: Kopf und Hals*, 2d ed. Munich: Urban und Schwarzenberg, **1980**
  7. Norrell HA. Fractures and dislocations of the spine. In: Rothman RH, Simeone FA, eds. *The Spine*, vol 2. Philadelphia: Saunders, **1975**:529-566
  8. Howarth MB, Petrie JG. Injuries of the spine. Baltimore: Williams & Wilkins, **1964**
  9. Jefferson G. Remarks on fractures of the first cervical vertebra. In: *Selected papers*. London: Pitman Medical, **1960**:213
  10. Amyes EW, Anderson FM. Fracture of the odontoid process (report of 63 cases). *Arch Surg* **1956**;72:377-393
  11. Harris JH. Acute injuries of the spine. *Semin Roentgenol* **1978**;13:53-68
  12. White III AA, Moss HL. Hangman's fracture with non-union and late cord compression. *J Bone Joint Surg [Am]* **1978**;60:839-840
  13. Brashear HR, Venters GC, Preston ET. Fractures of the neural arch of the axis. A report of twenty-nine cases. *J Bone Joint Surg [Am]* **1975**;57:879-887
  14. Cornish BL. Traumatic spondylolisthesis of the axis. *J Bone Joint Surg [Br]* **1968**;50:31-43
  15. Braakman R, Penning L. *Injuries of the cervical spine*. Amsterdam: Excerpta Med, **1971**
  16. Whitley JF, Forsyth HF. Classification of cervical spine injuries. *AJR* **1960**;83:633-644
  17. Penning L. *Functional pathology of the cervical spine*. Amsterdam: Excerpta Medica, **1968**
  18. Taylor AR, Blackwood W. Paraplegia in cervical injuries with normal radiographic appearance. *J Bone Joint Surg [Br]* **1948**;30:245-248
  19. Keller RH. Traumatic displacement of the cartilaginous vertebral rim: a sign of intervertebral disc prolapse. *Radiology* **1974**;110:21-24
  20. Raymond RD, Wheeler PS, Perovic M, Block B. The lucent cleft, a new radiographic sign of cervical disc injury or disease. *Clin Radiol* **1972**;23:188-192
  21. Marar BC, Orth MCH. Hyperextension injuries of the cervical spine. *J Bone Joint Surg [Am]* **1974**;56:1655-1662
  22. Lusted LB, Keats T. *Atlas of roentgenographic measurements*, 3rd ed. Chicago: Year Book, **1939**
  23. Wholey MB, Bruwer AJ, Baker HL. Lateral roentgenogram of the neck. *Radiology* **1958**;71:350-356
  24. Markuske H. Radiologische Messungen der Retropharyngealbreite und des Retrotrachealraums im Kindesalter. *Dtsch Gesundheitswes* **1978**;33:1729-1732
  25. Kendall BE, Ashcroft K, Whiteside CG. A physiological variation in the barium-filled gullet. *Br J Radiol* **1962**;35:769-775
  26. Selecki BR, Williams HBL. *Injuries to the cervical spine and cord in man*. Glebe, New South Wales: Australasian Medical, **1970**
  27. Stewart CG, Gehweiler JA, Lair RH, Martinez G. Horizontal fracture of the anterior arch of the atlas. *Radiology* **1972**;122:349-352
  28. Von Torklus D, Gehle W. *Die obere Halswirbelsäule*. Stuttgart: Georg Thieme, **1970**
  29. Paakkala T, Keski-Nisula L, Lehtinen E. Fehlbefundung in der Röntgendiagnostik der Halswirbelsäulenverletzungen. *ROEFO* **1978**;128:550-558