



Providing Choice & Value

Generic CT and MRI Contrast Agents



**FRESENIUS
KABI**

CONTACT REP

AJNR

**Spinal Seizures After Metrizamide Myelography
in a Patient with a Spinal Block**

Michael R. Paling, Eugene A. Quindlen and Giovanni Di Chiro

AJNR Am J Neuroradiol 1980, 1 (5) 473-474

<http://www.ajnr.org/content/1/5/473.citation>

This information is current as
of July 31, 2025.

Spinal Seizures After Metrizamide Myelography in a Patient with a Spinal Block

Michael R. Paling,¹ Eugene A. Quindlen,² and Giovanni Di Chiro²

Since the introduction of the water-soluble contrast agent metrizamide, reports of side effects in man following myelography have been limited to the frequent occurrence of relatively minor symptoms such as headache and vomiting, and the occasional episode of grand mal convulsions [1-7]. Such convulsions may relate to an excessive quantity of the contrast agent spilling over the convexity of the brain and are sometimes facilitated by phenothiazine medication [8]. As a result, metrizamide has been considered safe for total myelography, cisternography, and ventriculography. We report a case of spinal seizures, in the form of prolonged myoclonic spasms of the trunk and lower extremities, occurring after metrizamide myelography in a patient with a myelographic block in the midthoracic region.

Case Report

A 33-year-old woman underwent total myelography for evaluation of the cervical and thoracic cord. At age 19 she had developed an insidious slowly progressive paraparesis; she underwent a thoracic laminectomy which revealed a cystic swelling of the thoracic cord. For the 7 years before this admission she had experienced additional symptoms of mild weakness and numbness in the arms. A second exploration of the cord, this time at the level of the posterior fossa extending to the upper two cervical vertebrae, revealed a posterior fossa cyst which was decompressed. Currently, her signs were of paraplegia, bilateral lower motor neuron arm weakness, and hypoaesthesia in the right arm.

Plain radiographs of the spine showed the previous laminectomies and also widening of the interpedicular distance in the cervical and upper thoracic regions (fig. 1A). The possibility of cervical puncture was rejected because of this evidence of a space-occupying process in the neck, and because of the previous surgery. Spinal puncture was performed at L2-L3, after premedication with 60 mg of phenobarbital as a prophylactic anticonvulsant. Spinal block was suggested by xanthochromic colored cerebrospinal fluid (CSF) and a pathological Queckenstedt test. The CSF protein was 1120 mg/dl and glucose 46 mg/dl. There were 0 white blood cells and 148 red blood cells.

Metrizamide (10 ml) at a concentration of 200 mg iodine/ml was introduced into the subarachnoid space. The myelogram showed obliteration of the lumbar sac below the level of L3 by changes consistent with arachnoiditis and a complete block at T8 (figs. 1B and 1C). It was hoped that a small quantity of metrizamide might pass the block and enable the cervical cord to be better visualized on high resolution CT scanning of the neck which was carried out 1 hr later, but in fact, no detectable contrast material reached the neck.

Clinical Course and Management

Six hours after myelography, the patient developed rhythmic 2/sec myoclonic jerks of both flexor and extensor musculatures below the level of T8. The contractions were mild at first, but after 6 hr became so forceful that the entire bed was shaken with each new contraction. Diazepam (10 mg) and phenobarbital (60 mg) were given intramuscularly but had no apparent effect on the force or frequency of the contractions. Twenty hours after the myelogram, the patient appeared exhausted and her rectal temperature was 39°C. A lumbar puncture was performed and 8 ml of slightly xanthochromic CSF was removed and 100 mg of xylocaine was instilled into the subarachnoid space. The myoclonic jerks ceased within 5 min but returned with their original intensity 3 hr later. Two spinal punctures were then performed at T12-L1 and L3-L4, and the subarachnoid space was irrigated with 500 ml of sterile cold saline. When cold saline irrigation did not reduce the intensity or frequency of the myoclonic jerks, another 100 mg of xylocaine was injected into the subarachnoid space. The contractions soon ceased and did not return.

Plain radiographs of the spine taken 20 hr after myelography showed a small amount of contrast material was still present, and this was confirmed by radiographing the specimen of CSF subsequently removed, and comparing it with radiographs of serial dilutions of metrizamide. By this method the concentration of metrizamide was estimated at about 25 mg iodine/ml in the CSF.

A total thoracic laminectomy and dural opening disclosed an astrocytoma of the spinal cord which extended from T9 to T2. The tumor totally destroyed the architecture of the spinal cord from T7 to T5 and tapered to a narrow string of tumor tissue which extended up the central canal and beyond T2. The entire spinal cord with

Received January 28, 1980; accepted after revision April 1, 1980.

¹ Diagnostic Radiology Department, Bldg. 10, Rm. 6S211, National Institutes of Health, The Clinical Center, Bethesda, MD 20205. Address reprint requests to M. R. Paling.

² National Institute of Neurological and Communicative Disorders and Stroke, Surgical Neurology Branch, National Institutes of Health, The Clinical Center, Bethesda, MD 20205.

This article appears in September/October 1980 *AJNR* and November 1980 *AJR*.

AJNR 1:473-474, September/October 1980 0195-6108/80/0104-0473 \$00.00 © American Roentgen Ray Society

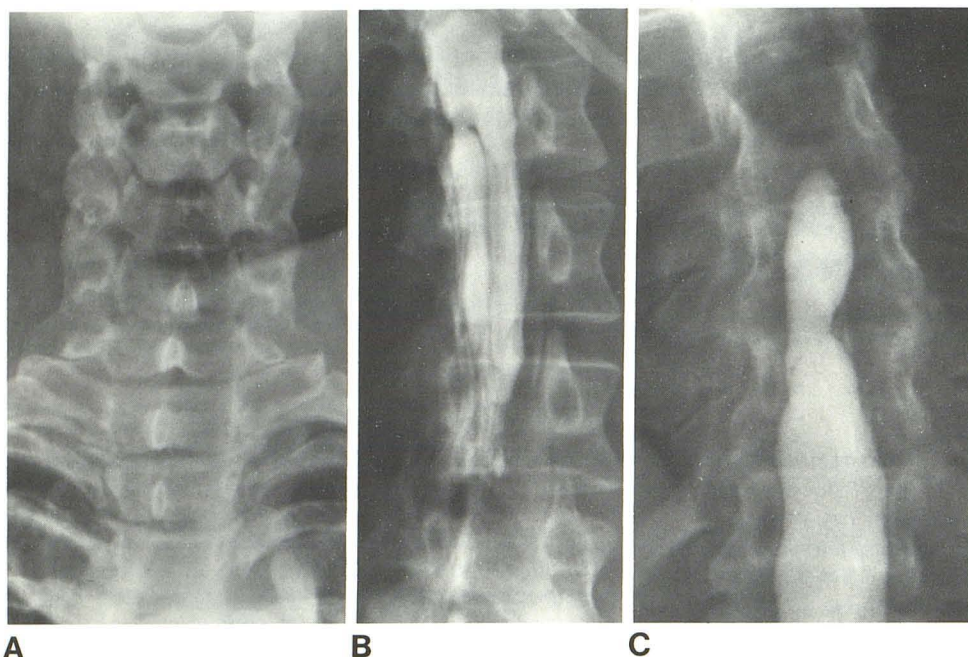


Fig. 1.—A, Frontal projection. Widening of interpedicular distance in cervical and upper dorsal spine. B, Obliteration of lumbar canal by changes of arachnoiditis. C, Total blockage to passage of contrast material at T8. Note previous laminectomy.

tumor was removed from T2 to T10. Postoperatively, the cervical spinal cord was treated with 4,500 rad (45 Gy) from a cobalt source. The patient's weakness in the upper extremities improved slightly.

Discussion

The introduction of the nonionic contrast agent metrizamide has provided a considerable reduction in neurotoxicity over the previously available water-soluble media, allowing total myelography to be performed. It is superior to Pantopaque for this purpose because of its miscibility with CSF, allowing better delineation of the cord and nerve roots and not requiring removal afterward. Furthermore, it acts as a positive contrast agent for CT scanning of the spine, outlining the cord, whereas oily media produce considerable artifacts. In myelography, the reported serious adverse reactions to metrizamide have been rare [9, 10].

This is the first report of spinal seizures occurring after metrizamide myelography, although Gelmers [10] reported two patients who experienced spasmodic jerking of the legs after metrizamide myelograms, which responded to intravenous Diazepam. When patients have been carefully examined, hyperreflexia has been frequently noted in patients after myelography with iophendylate or metrizamide [2, 11].

The dose of metrizamide used in this case (10 ml of 200 mg I/ml) was not unusually high for a proposed examination of the thoracic cord, and possibly the cervical cord also. However, it is postulated that the presence of a spinal block, together with obliteration of the lumbar sac, caused an unusually high concentration of metrizamide to remain in contact with cord, and that absorption of contrast material may have been inhibited by the longstanding arachnoiditis. Clearly, this is an unusual anatomic situation. Nevertheless,

it suggests that if at metrizamide myelography a block is demonstrated which might cause abnormal localization of the contrast agent over part of the cord, then it would be wise to repuncture the patient and remove the metrizamide.

REFERENCES

1. Ahlgren P. Amipaque myelography. *Neuroradiol* 1975;9:197-202
2. Irtam L, Sellden U. Adverse effects of lumbar myelography with amipaque and dimer-x. *Acta Radiol [Diagn]* (Stockh) 1976;17:145-159
3. Oftedal SI, Kaye K. Epileptogenic effects of water-soluble contrast media. *Acta Radiol [Suppl]* (Stockh) 1973;335:45-56
4. Skälpe IO, Torbergson T, Amundsen P, Presthus J. Lumbar myelography with metrizamide. *Acta Radiol [Suppl]* (Stockh) 1973;335:367-379
5. Baker RA, Hillman BJ, McClennan JE, Strand RD, Kaufman SH. Sequelae of metrizamide myelography in 200 examinations. *AJR* 1978;130:499-502
6. Sackett JF, Strother CM, Quaglieri CE, Javid MJ, Levin AB, Duff TA. Metrizamide—CSF contrast medium. *Radiology* 1977;123:779-782
7. Picard L, Vespignani H, Vieux-Rochat P, et al. Serious neurological complications of metrizamide myelography. *J Neuroradiol* 1979;6:3-14
8. Hindmarsh T, Grepe A, Wilden L. Metrizamide-phenothiazine interaction: report of a case of seizures following myelography. *Acta Radiol [Diagn]* (Stockh) 1975;16:129-134
9. Irtam L. Lumbar myelography with amipaque. *Spine* 1978;3:70-82
10. Gelmers HJ. Adverse side effects of metrizamide in myelography. *Neuroradiology* 1979;18:119-123
11. Buruma OJS, Hekster REM. Transient areflexia following thoracolumbar myelography with metrizamide. *Acta Radiol [Suppl]* (Stockh) 1977;355:371-372