



## Get Clarity On Generics

Cost-Effective CT & MRI Contrast Agents



FRESENIUS  
KABI

WATCH VIDEO

# AJNR

## The Isolated Fourth Ventricle in Children: CT and Clinical Review of 16 Cases

Giuseppe Scotti, Mark A. Musgrave, Charles R. Fitz and Derek C. Harwood-Nash

*AJNR Am J Neuroradiol* 1980, 1 (5) 419-424

<http://www.ajnr.org/content/1/5/419>

This information is current as  
of August 12, 2025.

# The Isolated Fourth Ventricle in Children: CT and Clinical Review of 16 Cases

Giuseppe Scotti<sup>1</sup>  
 Mark A. Musgrave  
 Charles R. Fitz  
 Derek C. Harwood-Nash

Isolated fourth ventricles were diagnosed by computed tomography (CT) in 16 children in a 3 year period. They all had had shunting of the lateral ventricles for hydrocephalus, and all needed subsequent shunt revisions. Seven patients without signs of raised intracranial pressure clinically had new posterior fossa signs at different intervals after lateral ventricular shunting. The clinical findings in the other nine patients were much less specific and in some cases the isolated fourth ventricle was an incidental finding. CT is essential for the diagnosis. The isolated fourth ventricle needs to be differentiated from posterior fossa cysts and cystic tumors. Shunting of the fourth ventricle improved the clinical condition in six of 14 children.

Encystment of a ventricle or part of it by occlusion of its cerebrospinal fluid (CSF) outlets due to ependymal reaction after intraventricular hemorrhage or infection is a well known and fully described entity [1]. Encystment of the fourth ventricle is, however, a relatively recently recognized condition [2-5]. Since the as yet limited literature on the subject contains some confusing statements concerning its clinical, radiologic, and therapeutic aspects, we have undertaken a study of 16 children investigated by CT at the Hospital for Sick Children in an attempt to clarify certain aspects of this condition.

## Pathogenesis

When both the aqueduct of Sylvius and the foramina of Luschka and Magendie are occluded, the fourth ventricle becomes isolated from the remaining ventricular system and from the CSF circulation of the subarachnoid space. Continued CSF production by the trapped choroid plexus results in a progressive cystic dilatation of the fourth ventricle, which is sometimes associated with clinical signs of an expanding lesion in the posterior fossa.

This entity, which has been called in turn double compartment hydrocephalus [2], isolated fourth ventricle [4, 5], encysted fourth ventricle [2, 7], and trapped fourth ventricle [3] is apparently never a primary condition. It has been shown to occur after shunting of the lateral ventricles for communicating hydrocephalus [2], aqueduct stenosis [5], and obstruction of the outlets of the fourth ventricle [4]. Subsequent mechanical or inflammatory changes in the aqueduct or at the fourth ventricular outlets are presumed to render the fourth ventricle completely isolated from the rest of the ventricular system and subarachnoid spaces.

It has long been recognized [6] that shunting of the lateral ventricles for communicating hydrocephalus can produce obstruction of the aqueduct of Sylvius due either to kinking or chronic inflammatory changes secondary to

Received November 2, 1979; accepted after revision March 26, 1980.

Presented at the annual meeting of the American Society of Neuroradiology, Los Angeles, March 1980.

<sup>1</sup>All authors: Department of Radiology, Hospital for Sick Children, 555 University Ave., Toronto, Ontario, Canada M5G 1X8. Address reprint requests to C. R. Fitz.

This article appears in September/October 1980 *AJNR* and December 1980 *AJR*.

*AJNR* 1:419-424, September/October 1980  
 0195-6108/80/0104-0419 \$00.00  
 © American Roentgen Ray Society



infection and ventriculitis. Raimondi et al. [7] confirmed this shunt complication and presented four cases among eight with Dandy-Walker syndrome in whom shunting of the lateral ventricles resulted in occlusion of a previously patent aqueduct, necessitating a separate shunt in the "encysted" Dandy-Walker cyst.

Three different sequences of events can thus be postulated to explain the isolation of the fourth ventricle in different types of hydrocephalus;

1. In patients with communicating hydrocephalus (extraventricular obstructive hydrocephalus), lateral ventricular shunting results first in mechanical aqueduct occlusion and subsequent infection or hemorrhage results in occlusion of the fourth ventricular outlets.

2. In patients with aqueduct stenosis, inflammation or hemorrhage around the outlets of the fourth ventricle after shunting is responsible for occlusion of the outlets with subsequent ventricular isolation.

3. In patients with preexisting intraventricular obstructive hydrocephalus due to occlusion of the outlets of the fourth ventricle, lateral ventricular shunting causes aqueduct occlusion by either mechanical or inflammatory means and thus isolates the fourth ventricle.

## Review of the Literature

The first reported case [2] was a patient with cysticercosis meningitis and communicating hydrocephalus in whom signs of a posterior fossa mass developed a few months after shunting of the lateral ventricles. Air studies and posterior fossa exploration demonstrated an encysted fourth ventricle due to occlusion of its outlets as well as of the aqueduct.

Since the first description of the isolated fourth ventricle in 1975, three more papers have appeared on the subject describing 15 new patients with this condition. Hawkins et al. [4], describing three children from this hospital, stressed the role of CT in making the diagnosis which in their opinion would be difficult, if not impossible, to make by conventional neuroradiologic techniques. All their patients had cerebellar dysfunction but not raised intracranial pressure; they had all been previously shunted for hydrocephalus due to fourth ventricle obstruction and had had multiple shunt revisions. CT had been performed to evaluate the functional status of the shunt. All improved clinically after shunting of the isolated fourth ventricle.

Zimmerman et al. [3] reported six patients with a large fourth ventricle, four of whom were children. Their case material is, however, somewhat confusing. They described two representative cases in detail. The first was an adult with hydrocephalus due to occlusion of the outlets of the fourth ventricle. While the fourth ventricle was disproportionately large, it was not by definition "isolated" and thus it diminished along with the supratentorial ventricular system after shunting of the lateral ventricles. At least a further two of their patients had not been previously shunted and the aqueduct was not occluded, which allowed for a diminution of the fourth ventricle after lateral ventricular shunting. Only two of their pediatric cases in fact seem to have had a truly

isolated fourth ventricle; all had had documented CSF infection. They also state that the CT differential diagnosis from other posterior fossa cystic lesions, such as Dandy-Walker cyst, cystic midline astrocytoma, hemangioblastoma, and arachnoid cyst is easy. The treatment of choice is fourth ventricular shunting.

In a recent report, Foltz and DeFeo [5] described six new patients and defined the characteristics of this syndrome as being (1) hydrocephalus due to aqueduct stenosis; (2) effective lateral ventricular CSF shunting of several years duration; and (3) recent ataxia, incoordination, variable diplopia, and lethargy despite good shunt function. Five of their six patients improved rapidly after suboccipital craniectomy and connection of the hydrocephalic fourth ventricle to the functioning lateral ventricular CSF shunt.

## Materials and Methods

At the Hospital for Sick Children, a computer coding system [8] is used to file all the CT examinations. It includes items regarding the brain density, size of any part of the ventricular system, mass effect, etc., as well as diagnosis according to the American College of Radiology. We searched for all patients who had been shunted for hydrocephalus and who had normal-sized lateral and third ventricles and a disproportionately large fourth ventricle. The clinical records, neuroradiologic investigations, and CT scans were analyzed in 16 children each with the above constellation of features. The initial disease and type of hydrocephalus, previous CSF shunts and shunt revisions, age at first shunt insertion, the time interval between first shunting and diagnosis of isolated fourth ventricle, the type of surgical treatment, and the clinical outcome were all recorded (table 1).

### CT Technique

All the patients were studied with an Ohio Nuclear Delta 50 scanner using a 13 mm collimator; the posterior fossa was routinely examined by regular CT sections obtained at 20°–25° to the radiographic baseline. Metrizamide was injected into the lateral ventricles in two patients and was followed by CT examination of the posterior fossa; in no case was metrizamide demonstrated within the fourth ventricle, confirming its isolation from the rest of the ventricular system.

## Results

### Age at Presentation

Of the sixteen patients, 13 presented with hydrocephalus at birth or within the first few weeks of life; two of the other three presented with enlarging heads at 9 months and 2 years, respectively; the third developed hydrocephalus secondary to a cerebellar tumor at the age of 7 years.

### Cause of Hydrocephalus

In five patients, the hydrocephalus was due to aqueduct stenosis. Four of them had had a meningomyelocele repair; the fifth had had an intraventricular hemorrhage at birth.

In seven patients, extraventricular obstructive hydrocephalus was diagnosed at ventriculography or air encephalogram.



TABLE 1: Findings in Patients with Isolated Fourth Ventricle

Type of Hydrocephalus/Case No. (Gender)	Diagnosis	Age at First Shunt	Interval Between Shunting and Diagnosis of Isolated 4th Ventricle (yrs, mos)	New Posterior Fossa Signs?	Change After 4th Ventricle Shunt
<b>Intraventricular obstructive, aqueduct stenosis:</b>					
1 (M) . . . . .	Meningomyelocele; Chiari	New.	12, 3	No; progressive arm weakness	Improved function in arms.
2 (M) . . . . .	Intraventricular hemorrhage	New.	3, 9	No; incidental finding	No change.
3 (F) . . . . .	Meningomyelocele	New.	1	Yes; signs of medullary compression	Died; infected shunt; urinary tract infection.
4 (M) . . . . .	Meningomyelocele	New.	5, 3	No; paraplegic weakness in arms; swallowing difficulty	Too soon to tell; shunted Oct. 1979.
5 (M) . . . . .	Meningomyelocele	New.	1, 8	No; paraplegic progressive arm weakness; swallowing difficulty	No change.
<b>Intraventricular obstructive:</b>					
6 (M) . . . . .	?Cerebellar hypertrophy	9 mos	8, 9	Yes	Improved, but residual ataxia.
7 (M) . . . . .	Left frontal abscess	2 mos	12, 9	No; asymptomatic	...
8 (M) . . . . .	Chiari hydromyelia; hydrobulbia	2 yrs	2, 6	Yes	Temporary improvement; relapse; required new shunt and surgical treatment of syrinx.
9 (F) . . . . .	Cerebellar ganglioglioma	7 yrs, 10 mos	6	No; elevated intracranial pressure	Worse; revision of blocked lateral ventricular shunt.
<b>Extraventricular obstructive:</b>					
10 (F) . . . . .	Premature; subarachnoid hemorrhage	New.	6	No; retarded; never walked well	Mild improvement; ataxia; broad base gait.
11 (M) . . . . .	Premature; intraventricular hemorrhage	New.	0, 11	No; long-term ataxia	Improved, but residual ataxia.
12 (M) . . . . .	Premature; intraventricular hemorrhage	New.	6, 4	No; spastic hemiplegia; severely retarded	Mild improvement.
13 (M) . . . . .	Premature	New.	4, 4	Yes	Improved, but residual ataxia.
14 (M) . . . . .	Hydrocephalus	New.	5, 6	Yes	Ataxia relieved after posterior fossa decompression.
15 (M) . . . . .	Intraventricular hemorrhage	New.	3, 9	Yes	Ataxia cured.
16 (M) . . . . .	Birth trauma; probable subarachnoid hemorrhage	New.	3, 6	Yes	Good; no residual ataxia (shunt not in 4th).

Note.—New. = newborn. All but cases 3 and 7 had their 4th ventricle shunted; cases 8 and 14 had it shunted twice.

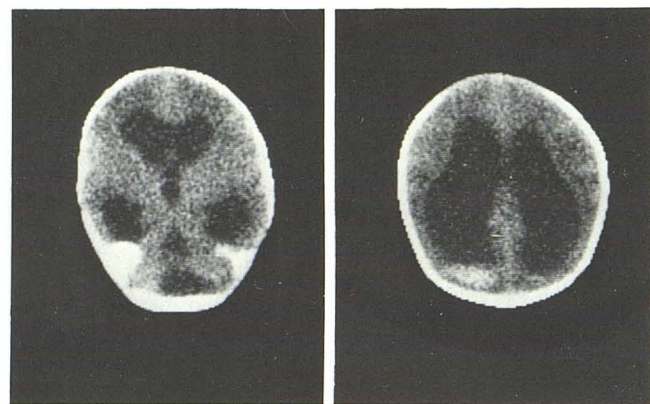
raphy. Four of them were born prematurely with subarachnoid or intraventricular hemorrhage (fig. 1). Of the remaining three, one was a full-term baby with an intraventricular hemorrhage and one had suffered birth trauma and a probable subarachnoid hemorrhage; the cause of the hydrocephalus in the third was not recorded.

In four patients the hydrocephalus demonstrated by CT was thought to be intraventricular obstructive hydrocephalus; ventriculography was not performed. Of these one had a Chiari malformation with hydromyelia and hydrobulbia; a second was operated on for a posterior fossa ganglioglioma;

a third developed hydrocephalus secondary to an intracerebral abscess possibly with an associated ventriculitis, and the last was explored for a possible posterior fossa tumor that turned out to be "cerebellar hypertrophy." The hydrocephalus could have been due to adhesions secondary to surgery.

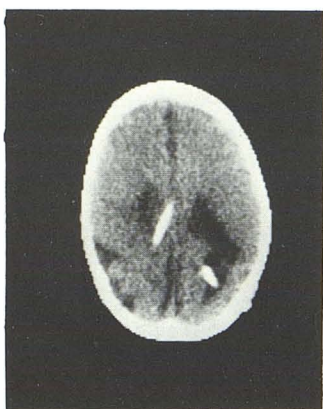
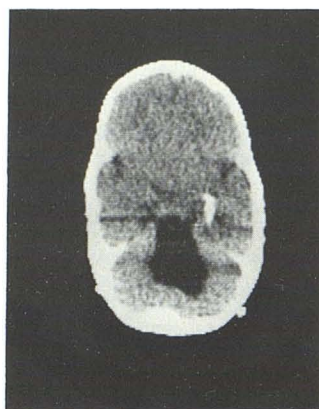
#### Initial Lateral Ventricular Shunt

Twelve patients were shunted as neonates, three were shunted within the first 2 years of life, and the remaining



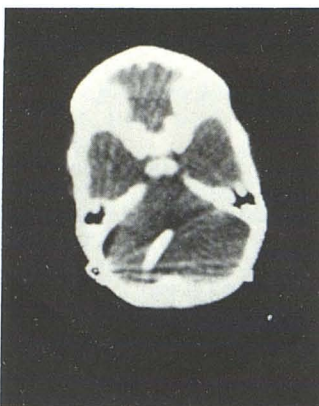A

B



C

D



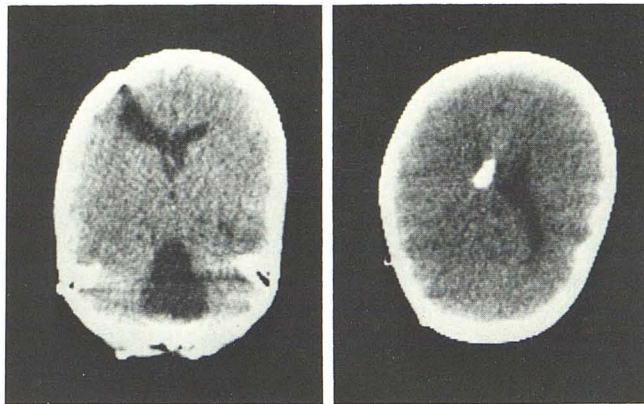
E

Fig. 1.—Case 11. **A** and **B**, At age 11 days. Marked enlargement of all ventricles and blood/CSF levels in both occipital horns. **C** and **D**, At age 11 months. Hydrocephalus has been treated and two shunts are seen in lateral ventricles. Enlarged, isolated fourth ventricle is obvious. **E**, After shunting, fourth ventricle has returned to normal size.

patient was shunted at age 7 years. All patients had multiple shunt revisions and there was a high incidence of shunt infection. The time interval between the first shunting procedure and the diagnosis of the isolated fourth ventricle ranged from 11 months to 12 years 9 months (mean interval, 5 years 3 months).

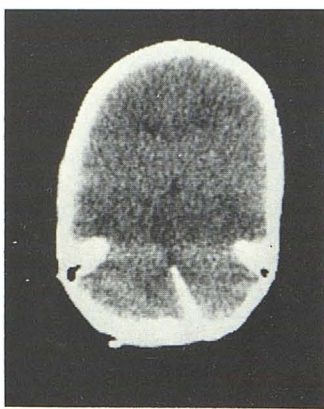
#### Diagnosis

The diagnosis of the isolated fourth ventricle was made on the basis of CT findings in all patients. A large rounded



A

B



C

Fig. 2.—Case 14. Typical CT appearances of isolated fourth ventricle. **A**, Large midline, cystic lesion typical of isolated fourth ventricle. **B**, Small lateral ventricles and shunt tip in body of right lateral ventricle. **C**, After shunting, fourth ventricle is now of normal size.

or pear-shaped midline cystic structure was present in the posterior fossa. The lateral and third ventricles were small or only moderately enlarged. A typical case is shown in figure 2. Figure 3 demonstrates the complete lack of communication between the third and the fourth ventricles after a positive contrast ventriculogram.

In only seven of our 16 patients immediate pre-CT posterior fossa signs characterized by ataxia, diplopia, and increasing lethargy were evident and, in one of them, only in retrospect. In six of the remaining patients, severe neurologic deficits such as mental retardation, chronic incoordination, hemi-, para-, or quadriplegia may have prevented the detection of additional posterior fossa signs. Five of these patients, however, presented with worsening of their preexisting neurologic deficits. In three patients, one of whom was completely asymptomatic, the isolated fourth ventricle was an incidental finding (fig. 4).

#### Fourth Ventricular Shunt

The asymptomatic patient and a second patient, who died, did not receive a fourth ventricular shunt. In 14 patients shunts were directly inserted into the fourth ventricles. In six, this produced a good result with the posterior fossa signs clearing either completely or in part. In three other patients there was only slight improvement, in that previous



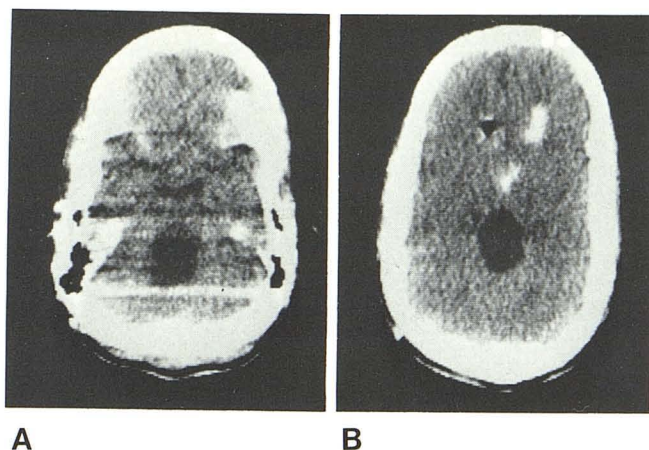
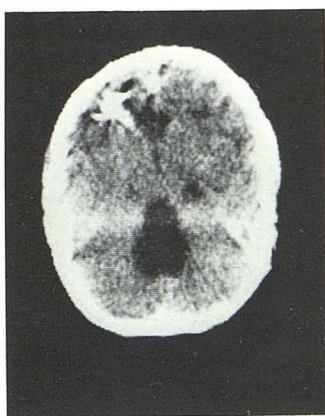


Fig. 3.—Case 1. After metrizamide ventriculogram. Metrizamide introduced via ventricular shunt seen in lateral and third ventricles. None has entered enlarged fourth ventricle.

Fig. 4.—Case 7. Large isolated fourth ventricle in asymptomatic patient. Density in left frontal region is sterile barium suspension in old abscess cavity.



symptoms, such as spasticity, slightly decreased. In three patients shunting was ineffective. One of these last three patients showed dramatic improvement in his ataxia only when his posterior fossa was surgically decompressed some 6 months after placement of the fourth ventricular shunt. One patient actually deteriorated after insertion of a fourth ventricular shunt. However, this was remedied by revision of his blocked lateral ventricular shunt, which was obviously the cause of his symptoms. He had presented with elevated intracranial pressure and an incidental isolated fourth ventricle. One patient was shunted immediately prior to preparation of our data and it is too soon to assess his postoperative response.

The fourth ventricular shunts, initially satisfactory, had to be revised in two patients. In four others the first attempted shunting resulted in malposition of the shunt.

## Discussion

Careful analysis of the clinical records and neuroradiologic examinations of these 16 patients establishes the following points:

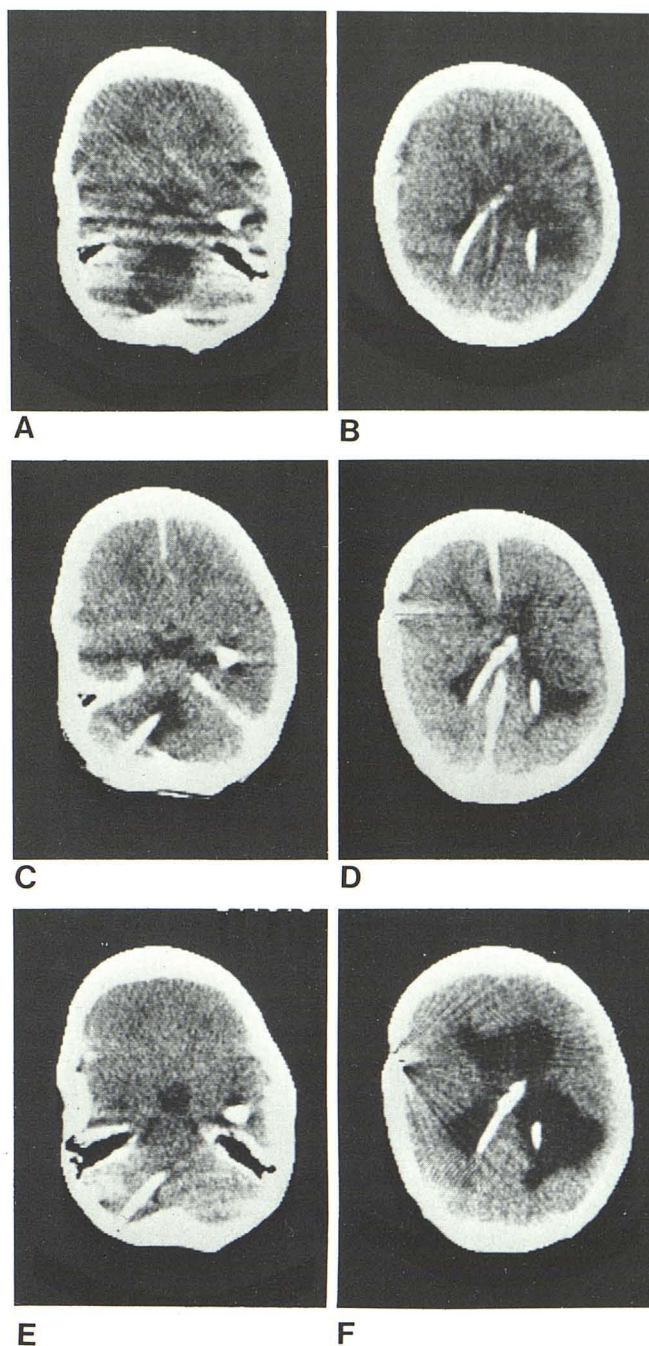


Fig. 5.—Case 13. A and B, Typical appearance of isolated fourth ventricle with small, shunted lateral ventricles. C and D, One month later, after fourth ventricular shunting. Considerable diminution of fourth ventricle. E and F, Seven months later. Lateral ventricular shunt is blocked. Lateral ventricles are dilated, while fourth ventricle remains small.

1. The isolated fourth ventricle is a *specific anatomicopathological entity* characterized by remarkable dilatation of the fourth ventricle. This enlargement is produced by the CSF that, secreted by the choroid plexus, cannot flow freely through the occluded foramina of the fourth ventricle nor through the aqueduct.



2. The clinical presentation may be in the form of the full-blown *posterior fossa syndrome* characterized by a recent appearance of ataxia, diplopia, and increasing drowsiness. However, this clinical picture is rarely clear cut; signs of posterior fossa involvement may be present for years without being progressive. The isolated fourth ventricle may even be asymptomatic, discovered at CT as an incidental finding. In some cases preexisting neurologic signs such as spasticity, hemi-, or quadriparesis may be accentuated without the appearance of posterior fossa signs.

3. The patients usually have *no signs of raised intracranial pressure*. In our experience the isolated fourth ventricle occurs only in patients previously shunted for hydrocephalus of different kinds, either extraventricular obstructive hydrocephalus or intraventricular obstructive hydrocephalus. All of our patients had had multiple shunt revisions.

4. *Shunting* of the fourth ventricle is effective in rapidly reversing the posterior fossa signs when they are present and progressive. In other cases there may be some relief of preexisting neurologic signs or no change at all, despite a demonstrable diminution of the shunted fourth ventricle. The fourth ventricular shunt is subject to the same problems as any shunt elsewhere in the ventricular system. It may malfunction, causing reenlargement of the fourth ventricle. The lateral ventricular shunt may malfunction while the shunt in the fourth ventricle is working well. This situation will result, as happened in one of our patients (fig. 5) in dilatation of the supratentorial ventricular system, while the previously dilated fourth ventricle, now shunted, remains of normal size.

5. The *CT diagnosis* of isolated fourth ventricle is accurate and can be made without recourse to metrizamide ventriculography. When the diagnosis is made, the lateral ventricles are usually of normal size or only moderately dilated. Differential diagnostic problems are uncommon, but can arise in patients examined after surgery for posterior fossa lesions. In these cases, a recurrent cyst may be difficult to distinguish from an isolated fourth ventricle.

Other cystic lesions such as cystic astrocytoma, arach-

noid or parasitic cysts usually present no difficulty. They do not have the typical history of complicated shunted hydrocephalus and their clinical presentation is quite unlike that of an isolated fourth ventricle.

6. Since this is, in some cases at least, a *potentially curable entity*, we believe that CT should be performed on all patients with shunted hydrocephalus who develop new posterior fossa signs or worsening of preexisting neurologic deficits.

7. The term *isolated fourth ventricle* should be reserved for the type of patients we have described. When the fourth ventricle is larger than usual in association with hydrocephalus but returns to normal after shunting of the lateral ventricles [3], the term *disproportionately large, communicating fourth ventricle* should be used.

#### REFERENCES

1. Harwood-Nash DC, Fitz CR. *Neuroradiology in infants and children*, vol 1. St. Louis: Mosby, 1976:632-642
2. DeFeo D, Foltz EL, Hamilton AE. Double compartment hydrocephalus in a patient with cysticercosis meningitis. *Surg Neurol* 1975;4:247-251
3. Zimmerman RA, Bilaniuk LT, Gallo E. Computed tomography of the trapped fourth ventricle. *AJR* 1978;130:503-506
4. Hawkins JC III, Hoffman HJ, Humphreys RP. Isolated fourth ventricle as a complication of ventricular shunting; report of three cases. *J Neurosurg* 1978;49:910-913
5. Foltz EL, DeFeo DR. Isolated 4th ventricle (or double compartment) hydrocephalus: a new clinical entity. Abstracts of the meeting of the International Society for Pediatric Neurosurgery, Chicago, September 1979
6. Foltz EL, Shurtleff DB. Conversion of communicating hydrocephalus to stenosis or occlusion of the aqueduct during ventricular shunt. *J Neurosurg* 1966;24:520-525
7. Raimondi AJ, Samuelson G, Yarzgaray L, Norton T. Atresia of the foramina of Luschka and Magendie: the Dandy-Walker cyst. *J Neurosurg* 1969;31:202-216
8. Fitz CR, Gilday DL. Computer storage and retrieval of neuroradiological exams. Presented at the annual meeting of the American Society of Neuroradiology, Toronto, May 1979