



Get Clarity On Generics

Cost-Effective CT & MRI Contrast Agents

**FRESENIUS
KABI**

[WATCH VIDEO](#)

AJNR

Intramedullary Disease of the Spine: Diagnosis Using Gadolinium-DTPA-Enhanced MR Imaging

Gordon Sze, George Krol, Robert D. Zimmerman and Michael D. F. Deck

AJNR Am J Neuroradiol 1988, 9 (5) 847-858

<http://www.ajnr.org/content/9/5/847>

This information is current as
of August 21, 2025.

Intramedullary Disease of the Spine: Diagnosis Using Gadolinium-DTPA-Enhanced MR Imaging

Gordon Sze¹
George Krol
Robert D. Zimmerman
Michael D. F. Deck

Twenty-six patients with suspected lesions of the spinal cord were studied before and after administration of gadolinium-DTPA to assess whether contrast enhancement was useful in the MR evaluation of intramedullary disease. Nine patients had primary tumors, six had benign syringes, three had multiple sclerosis with cord involvement, three had thrombosed vascular malformations, three had probable intramedullary metastasis, and two were normal. Although all lesions were detected on noncontrast MR scans, gadolinium-DTPA was of great help in their delineation and characterization. Specifically, contrast material may be able (1) to localize tumor nidus and separate it from edema, in cases of hemangioblastomas and metastases; (2) to suggest regions of more active tumors, in cases of glioma, for surgical biopsy or removal; (3) to differentiate benign or reactive processes from neoplastic lesions, such as reactive cyst from tumor cyst or hematoma due to thrombosed malformation from tumor hemorrhage; and (4) possibly to differentiate active from inactive lesions, for example, in multiple sclerosis.

Because of these advantages, gadolinium-DTPA probably will often be used routinely when intramedullary lesions are detected on noncontrast MR scans.

MR imaging has rapidly become the technique of choice in the assessment of possible intramedullary lesions of the spinal cord [1-5]. The traditional techniques of myelography and postmyelography CT are not only invasive and time-consuming but also are often of limited resolution and capability in the delineation and characterization of the lesion. Although cord enlargement can be defined adequately, disease associated with normal cord contour is detected less easily. In addition, the actual nature of the intramedullary process, for example, the presence of blood or tumor cyst, frequently is difficult to assess [6]. In contrast, MR, especially with the implementation of cardiac gating and gradient moment nulling, provides excellent depiction of processes within the spinal cord itself.

Recently, we reported our results concerning the use of gadolinium-DTPA as a contrast agent in the MR evaluation of intradural extramedullary lesions of the spine [7] and of extradural tumors of the spine [8]. We found apparently dichotomous results. Contrast-enhanced MR images proved far superior to the noncontrast scans in the evaluation of possible intradural extramedullary disease. However, with extradural tumors, gadolinium-DTPA provided additional information only in specific clinical situations; in fact, its use served to obscure lesions in many cases. In general, the utility of contrast-enhanced MR images was inversely proportional to the success of noncontrast MR images in depicting disease.

In this investigation, we examined the use of gadolinium-DTPA in the evaluation of intramedullary lesions of the spinal cord. Because one of the crucial advantages of MR lies in its noninvasiveness, specific attention was paid to a comparison of contrast-enhanced images with nonenhanced images, especially high-quality long TR cardiac-gated images.

This article appears in the September/October 1988 issue of *AJNR* and the December 1988 issue of *AJR*.

Received December 2, 1987; accepted after revision March 29, 1988.

¹ All authors: Department of Medical Imaging, Memorial Sloan-Kettering Cancer Center and Cornell University Medical College, 1275 York Ave., New York, NY 10021. Address reprint requests to G. Sze.

AJNR 9:847-858, September/October 1988
0195-6108/88/0905-0847

© American Society of Neuroradiology

Subjects and Methods

Twenty-six consecutive patients with suspected intramedullary disease of the cord were selected to participate in this study to examine the use of gadolinium-DTPA in suspected tumors of the spine. The protocol was carried out under the guidelines of the Food and Drug Administration, the Institutional Review Board and Investigational Drug Committee of the Memorial Sloan-Kettering Cancer Center, and the commercial developer of the product.* Fully informed consent was obtained from every patient. Pregnant and nursing women and individuals less than 18 years old were excluded. Conus and cauda equina tumors, such as myxopapillary ependymomas, were not included as intramedullary lesions.

Of the twenty-six patients, nine had primary tumors of the cord. Of these, five had had prior operations 1–14 years before. Another three tumors were proved surgically after inclusion in this study. The ninth was presumed. Six patients had benign syringes. Four were idiopathic; one was a benign postoperative “communicating” syrinx, which evolved as a result of communicating hydrocephalus after successful surgery for an acoustic neuroma. This syrinx resolved when the lateral ventricles were shunted. One syrinx most likely resulted from a large cervical disk that impinged on the cord at the midpoint of the syrinx. Three other patients had thrombosed vascular malformations of the cord.[†] Two were explored surgically twice each; the third diagnosis was presumed on the basis of the MR appearance and the fluctuating symptoms and signs. Two patients had multiple sclerosis, with the diagnosis based on the long clinical history marked by remissions and exacerbations. Both had specific symptoms and signs referable to the cervical cord. One patient had presumed multiple sclerosis, with the subacute onset of cord symptoms and an otherwise negative evaluation. Three patients developed probable carcinoma metastatic to the cord, demonstrated by characteristic myelographic, postmyelography CT, and MR findings in all three cases and also by positive CSF cytology in one case. Two patients had breast carcinoma and one patient had lung carcinoma. All three had extensive metastatic disease with brain metastases in two cases.

The patients were 19–65 years old. There were 15 women and 11 men. Twelve of the twenty-six patients had recent myelography and postmyelography CT. Seven other patients had previous myelography with postmyelography CT; in six of these the studies were performed more than 1 year before inclusion in this study. The five postoperative patients were included in this group. Two other patients were evaluated with angiography and MR. Finally, five patients were evaluated by MR alone. Myelography was performed from either a lumbar or a cervical approach, depending on the location of the lesion. CT was performed on a high-resolution scanner. Contiguous axial 5-mm scans were obtained through the regions of tumor within 3 hr of instillation of intrathecal contrast material. In addition, in eight of the 19 patients studied with myelography, delayed scans were obtained 6–24 hr later to assess for the possibility of syrinx.

For all MR studies, a superconductive magnet[‡] operating at 1.5 T was used. Either a rectangular 18- by 30-cm surface coil or a circular 12.5-cm surface coil was used, except in one cervicomedullary lesion, in which a 25-cm-diameter head coil was used. For the short TR sagittal sequences, 3-mm sections with an interslice gap of 0.6 mm were obtained through the cord. For the long TR sagittal sequences, 3- or 5-mm sections were obtained, either as multislice acquisitions with interslice gaps of 0.6 or 1 mm or as single-section acquisitions. Five- or 10-mm axial scans with an interslice gap of 1–5 mm were

obtained through regions of interest. The field of view was 24 or 28 cm for sagittal scans and 16 or 20 cm for axial scans. The matrix was 256 by 256. Cardiac gating was used in all long TR sagittal examinations, except in the single patient imaged with the head coil. In six of the 26 cases, cardiac gating was also used in the short TR sagittal sequence.

Each patient first had a preliminary MR examination without contrast material. This consisted of a short TR sagittal scan, followed by a long TR sagittal scan, followed by a short TR axial scan. For short TR sequences, 600/20 (TR/TE) images were obtained in 21 cases. When cardiac gating was used, the actual TR of the short and long TR sagittal sequence varied with respect to the heart rate. Generally, the examinations were gated to every heart beat in the short TR sequences to obtain a TR of approximately 600–750 msec. In the long TR sequences, examinations were gated to every other or to every third heart beat to obtain a TR of approximately 1500–2200 msec. TEs in the long TR examinations were 20, 40, 60, and 80 msec in the first two patients and 35 and 70 msec in the last 24 patients. Gradient-moment nulling techniques were used in the vast majority of patients to decrease CSF flow artifacts. A respiratory-ordered, phase-encoding technique was added to the short TR sequences in most cases to decrease respiratory-induced phase-shift effects. Four excitations were used in all short TR sequences. Two excitations were used in all long TR sequences. The transmit attenuation was maintained within 0.5 dB on all scans.

After the preliminary sequences were completed, gadolinium-DTPA in a concentration of 0.1 mmol/kg was injected IV over the course of 1 min. Scanning was initiated immediately on completion of the injection. In five patients, the same sequences as in the precontrast scans were performed. In 21 patients, the long TR scan was eliminated after the administration of gadolinium-DTPA. At least one additional short TR sagittal scan was included at the end in all cases. For purposes of comparison between pre- and postcontrast scans, the patients were advised not to move or change position throughout the entire protocol. The scanning time varied from about 58 to 87 min. The actual examination lasted from 1½–3 hours. In cases of anxiety or pain, patients were given diazepam, either IV or by mouth, or IV morphine sulfate.

After the completion of scanning, the MR studies were evaluated by three neuroradiologists. Precontrast MR, postcontrast MR, and the myelogram and postmyelogram CT scan, if available, were individually evaluated in that order. Two of the three neuroradiologists were blinded to nearly all of the cases and were unaware of the cases or types of disease they might see. The postcontrast scans were compared with the precontrast scans and were scored on a four-point scale with respect to (1) detection of abnormalities, (2) delineation of tumor extent, and (3) characterization of lesions. A minus (–) was accorded to the scan if the postcontrast scan obscured information. A zero (0) was given if the gadolinium-enhanced scan provided no additional information. A plus (+) was assigned to the scan if the contrast material was useful in helping to evaluate the lesions, while a double-plus (++) was given if the contrast material was deemed essential.

Additional analysis was performed by calculating intensity measurements. An operator-controlled interactive cursor was used to define a region of interest. This region of interest always consisted of at least 10 pixels. Because intensity measurements vary depending on the distance of the lesion from the surface coil, only well-circumscribed abnormalities that could be easily defined with a reproducible region of interest both pre- and postcontrast were chosen. Each lesion was measured three separate times before and after gadolinium-DTPA was administered. Background was measured twice. The mean of these measurements was used to calculate the percentage enhancement according to the formula, [lesion (enh) – background

* Berlex Laboratories, Inc., Cedar Knolls, NJ.

[†] Vascular malformation is used here to include cavernous hemangioma, arteriovenous malformation, capillary telangiectasia, and venous angioma.

[‡] Signa, General Electric Medical Systems, Milwaukee, WI.

(enh)] - [lesion (unen) - background (unen)]/lesion (unen) - background (unen), where enh = enhanced and unen = unenhanced. In all cases, the sequence showing the strongest enhancement by visual inspection was chosen for analysis.

Results

The results are tabulated in Table 1.

Nonenhanced MR

On the short TR sequences, cords of normal caliber and contour were seen in nine cases, but five exhibited syringes. The cord parenchyma appeared normal. Abnormalities of cord contour were seen in 17 of the 26 cases. Of these 17 cases, five appeared as homogeneous regions of cord enlargement, slightly hypointense to normal cord; two postoperative cases were found to have homogeneous regions of cord thinning. In nine of the 17 cases, cystic collections of fluid were seen. In three of these cases, a very hyperintense collection, consistent with evolving hematoma, was present. One was surrounded by a small border of low intensity. In the remaining cases exhibiting cystic collections, the fluid appeared either isointense relative to normal CSF or hyperintense relative to CSF and slightly hypointense relative to cord parenchyma (Figs. 1 and 2). In one case, a definite, well-circumscribed tumor nodule was seen at the base of the cysts (Fig. 1). In two cases, poorly defined solid masses appeared to be present inferiorly (Fig. 2). Finally, in one of the 17 cases, a low-intensity central region was seen in the cord, but definitive diagnosis of a syrinx, as opposed to edematous cord, could not be made.

On the long TR sequences, normal cord contour appeared normal in two of nine cases; seven showed small regions of hyperintensity within the cord. In the cases of benign syrinx, small patches of high signal surrounded the borders of the cyst. Of the 17 cases with abnormal cord contours, the five lesions that appeared homogeneously enlarged on the short TR images became uniformly hyperintense. All regions of cord enlargement increased in signal, becoming almost isointense relative to surrounding CSF, while normal cord became markedly hypointense. In the two postoperative cases with cord thinning, no definite change in signal was evident. In the nine patients with cystic fluid collections, the cystic collections were of high signal intensity, becoming even more hyperintense than any surrounding diseased cord tissue. Fairly extensive regions of parenchymal hyperintensity were present surrounding the cysts. The exact borders of this hyperintense region were difficult to define in eight cases. In one case, the parenchymal abnormality was bordered by a striking low-intensity rim. The patients with the intramedullary lobulated hematoma displayed characteristics of evolving hemorrhage, with hyperintense central nidi. In one chronic case, a markedly hypointense peripheral rim was seen, while in two subacute cases, studied less than 10 days after the onset of the patients' symptomatology, there was no surrounding decrease in signal. Some surrounding hyperintensity was present in adjacent cord. Finally, the patient with the hypoin-

tense central region on the short TR images showed diffuse homogeneous hyperintensity in the corresponding region on the long TR sequences.

Contrast-Enhanced MR

Eight of the 26 patients showed prominent regions of enhancement. All eight of these patients had tumors (Figs. 1-5). Enhancement was marked on the immediate postcontrast scan in seven of the eight cases. However, in the eighth case, enhancement increased with time, reaching a peak in 1 hr (Fig. 1). The delay in enhancement correlated at surgery with necrotic tumor intermixed with granulation tissue.

Four of the 26 patients showed small foci of mild enhancement, seen only when postcontrast scans were examined side by side with precontrast scans. One of these patients had multiple sclerosis, and the long TR cardiac-gated sagittal scan disclosed a definite plaque in the lower cervical cord. After the administration of gadolinium-DTPA, probable minimal enhancement was seen. The remaining patients had had surgery for primary cord tumors. All three of these patients were stable. Mild irregular enhancement was present within the cord.

Fourteen of the 26 patients showed no enhancement: the three with thrombosed vascular malformations and six with benign syringes, two with multiple sclerosis, one with presumed astrocytoma, and two who were normal.

Because of the sensitivity and accuracy of noncontrast MR, especially with high-quality short TR sagittal images and cardiac-gated long TR sagittal images, the application of gadolinium-DTPA did not aid in the detection of additional lesions. In fact, in multiple sclerosis, the long TR cardiac-gated images were considerably superior to the short TR postcontrast images in demonstrating even clinically active plaques. However, the delineation and characterization of lesions in those patients who showed enhancement was improved with the use of contrast material. While the cardiac-gated long TR images showed high intensity throughout the entire region of the cord enlargement, enhancement was often limited to a much smaller extent. In one patient with cystic hemangioblastoma, the nidus enhanced brilliantly, allowing accurate surgical removal (Fig. 4). Precise delineation of the nidus was impossible without enhancement. In the patients with presumed intramedullary metastasis, enhancement was localized within the much larger region of cord enlargement, presumably representing the metastasis surrounded by extensive areas of edema in the cord (Fig. 5). In the seven gliomas that exhibited an increase in signal intensity, enhancement varied from a small focus to extensive regions. However, the enhancement always occupied a smaller region than did the cord enlargement. At surgical exploration, enhancement correlated with sites of tumor. Gadolinium-DTPA helped to pinpoint areas for biopsy. In one of the postoperative patients, considerable enhancement in a mildly enlarged cord was seen inferior to the region of the actual laminectomy.

Enhancement was verified by the results of the intensity measurement calculations. The percentage of enhancement

TABLE 1: Comparison of Patients with Intramedullary Lesions Before and After Administration of Gadolinium-DTPA

Case No.	Age	Gender	Diagnosis and Proof	Noncontrast MR Findings	Contrast-Enhanced MR Findings				Comment
					Detection	Delineation	Characterization	% Enhancement	
Neoplastic lesions:									
1	48	M	Hemangioblastoma	Cystic lesion in cervicomedullary region	0	++	+	130	Nidus of tumor delineated for complete surgical removal; cystic nature confirmed
2	60	F	Intramedullary breast carcinoma metastasis ^a	Lower cervical and upper thoracic cord enlargement	0	++	0	124	Fairly extensive cord enlargement, most likely due to edema, with relatively small area of enhancement, probably representing tumor
3	45	F	Intramedullary breast carcinoma metastasis ^a	Lower cervical and upper thoracic cord enlargement; distal thoracic cord enlargement	0	++	0	85	Fairly extensive cord enlargement, most likely due to edema, with relatively small area of enhancement, probably representing tumor
					0	++	0	122	Additional, clinically unsuspected metastasis discovered
4	55	F	Intramedullary lung carcinoma metastasis ^a	Cervical cord enlargement	0	++	0	97	Fairly extensive cord enlargement, most likely due to edema, with relatively small area of enhancement, probably representing tumor
5	26	M	Astrocytoma (grade I)	Localized thoracic cord enlargement	0	+	0	19	Irregular enhancement within larger region of cord enlargement; as with primary brain tumors, enhancement may represent only a portion of the tumor
6	53	M	Ependymoma	Extensive cervical and thoracic cord enlargement with large superior cyst, small inferior cysts	0	+	+	41	Enhancement localized to base of superior cyst; cord surrounding cervical cysts does not enhance, suggesting cysts are benign and reactive
7	55	F	Astrocytoma (grade I)	Central lobular lesion in extensive cervical and thoracic cord enlargement with superior and inferior cysts	0	+	+	83	Delayed enhancement of central lesion, which was necrotic; cord surrounding superior and inferior cysts does not enhance, suggesting cysts are benign and reactive
8	45	F	Astrocytoma (grade II)	Extensive mild cord enlargement from mid-thoracic cord to conus; large superior cyst	0	+	+	103	Heterogeneous enhancement extends far below level of previous laminectomy; preoperative evaluation difficult due to marked scoliosis and adhesions from prior surgery
9	57	M	Astrocytoma ^a	Localized thoracic cord enlargement	0	0	+	0	No enhancement, even on delayed scans after 1 hr; may correlate with less active tumor
10	47	F	Astrocytoma (grade II)	Extensive cervical and thoracic cord enlargement with inferior cysts	0	++	0	103	Recurrent tumor enmeshed in postoperative change visualized with contrast materials; enhancement correlated with extent of tumor on reexploration
11	35	F	Astrocytoma (grade I)	Postoperative thinning and distortion of cervical cord	0	+	0	82	Minimal enhancement; ?recurrent tumor; benign cyst seen

TABLE 1—Continued

Case No.	Age	Gender	Diagnosis and Proof	Noncontrast MR Findings	Contrast-Enhanced MR Findings				Comment
					Detection	Delineation	Characterization	% Enhancement	
12	53	M	Ependymoma	Postoperative changes in cervical cord; marked thinning of cord	0	+	0	35	Trace enhancement in patient clinically stable 14 years after surgery
Nonneoplastic lesions:									
13	36	M	Thrombosed vascular malformation	Localized subacute to chronic cervical cord hematoma	0	0	+	0	Lack of enhancement favors nonneoplastic cause; surgically confirmed twice
14	19	M	Thrombosed vascular malformation	Cervical cord swelling, with extensive intramedullary hematoma	0	0	+	0	Lack of enhancement favors nonneoplastic cause; surgically confirmed twice
15	43	F	Thrombosed vascular malformation ^a	Cervical and thoracic cord swelling with extensive intramedullary hematoma	0	0	+	0	Heterogeneous nidus does not enhance; favors nonneoplastic origin
16	42	F	Multiple sclerosis	Mild cervical cord swelling	0	0	+	0	No enhancement, consistent with patient's recent improvement and lack of acute symptoms
17	60	F	Multiple sclerosis	Normal cord contour, but gated long TR scans show focus of high signal in cervical cord	0	0	+ / 0	Trace	Trace enhancement suggests lesion may be active; correlates with patient's recent progressive clinical deterioration
18	40	M	Multiple sclerosis ^a	Normal cord contour, but gated long TR scans show focus of high signal in cervical cord	0	0	0	0	No enhancement, despite clinically active disease
19	65	F	Benign syrinx	Cervical and thoracic "communicating syrinx"	0	0	+	0	Lack of enhancement favors nonneoplastic origin
20	50	M	Benign syrinx	Cervical syrinx, idiopathic	0	0	+	0	Lack of enhancement favors nonneoplastic origin
21	48	M	Benign syrinx	Cervical and thoracic syrinx, idiopathic	0	0	+	0	Lack of enhancement favors nonneoplastic origin
22	32	F	Benign syrinx	Cervical syrinx; large C5-C6 disk herniation impinging on cord	0	0	+	0	Lack of enhancement favors nonneoplastic origin
23	18	F	Benign syrinx	Cervical syrinx, idiopathic	0	0	+	0	Lack of enhancement favors nonneoplastic origin
24	37	F	Benign syrinx	Cervical and thoracic syrinx, idiopathic	0	0	+	0	Lack of enhancement favors nonneoplastic origin
25	33	M	Lymphoma	Normal short and long TR scans of cervical cord	0	0	0	0	Strong clinical suspicion of intramedullary lesion; no pre- or postcontrast findings
26	54	F	Lung cancer	Normal short and long TR scans of cervical cord	0	0	0	0	Strong clinical suspicion of intramedullary lesion; no pre- or postcontrast findings

Note.— — = gadolinium enhancement obscured information; 0 = gadolinium enhancement provided no additional information; + = gadolinium enhancement was useful in lesion evaluation; ++ = gadolinium enhancement was essential in lesion evaluation.

^a Presumptive diagnosis.

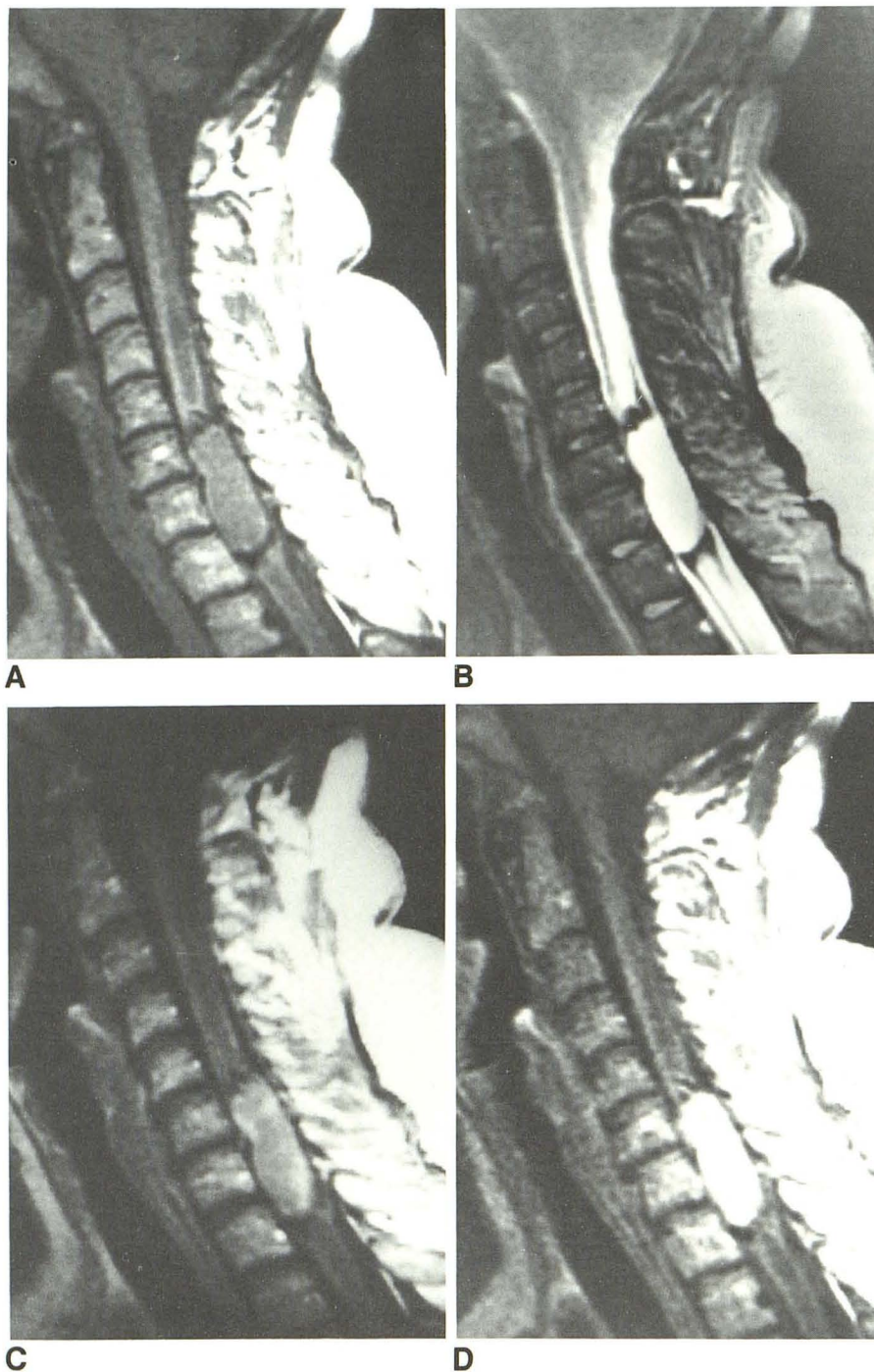


Fig. 1.—Case 7: 55-year-old woman with right leg weakness. Surgical pathology: astrocytoma.

A and B, Short TR (741/20) (A) and long TR (2222/70) (B) cardiac-gated sagittal sections disclose central nidus with superior and inferior cysts. Markedly hypointense rim was shown pathologically to be hemosiderin deposition.

C, Gadolinium-DTPA short TR (741/20) cardiac-gated sagittal scan 30 min after administration discloses peripheral enhancement of central lesion.

D, 1 hr delayed gadolinium-DTPA short TR (741/20) cardiac-gated sagittal section shows enhancement confined to central focus. Associated syringes are not surrounded by enhancing cord parenchyma, suggesting they are benign reactive cysts, a finding confirmed at surgery, rather than tumor cysts. Necrotic nature of this tumor was shown pathologically and probably was responsible for delayed enhancement.

varied from 19% to 130% in the 11 cases in which intensities could be measured. These results correlated with visual inspection. In one patient with multiple sclerosis, the focus of enhancement was too faint and irregular to circumscribe with the operator-defined cursors, and intensity measurements could not be obtained.

Even lack of contrast enhancement was very helpful in the characterization of lesions (Fig. 6). In the three patients with thrombosed vascular malformations, the lack of contrast en-

hancement suggested a nonneoplastic or, at most, a low-grade neoplastic cause. Similarly, the patients with the benign syringes did not show enhancement of any region, despite surrounding hyperintensity on the long TR cardiac-gated images. In this way, the use of contrast material was able to decrease the suspicion of associated neoplasm. One patient with a presumed astrocytoma showed no enhancement, suggesting a less active tumor, with less blood-brain barrier breakdown. Finally, one patient with multiple sclerosis, whose

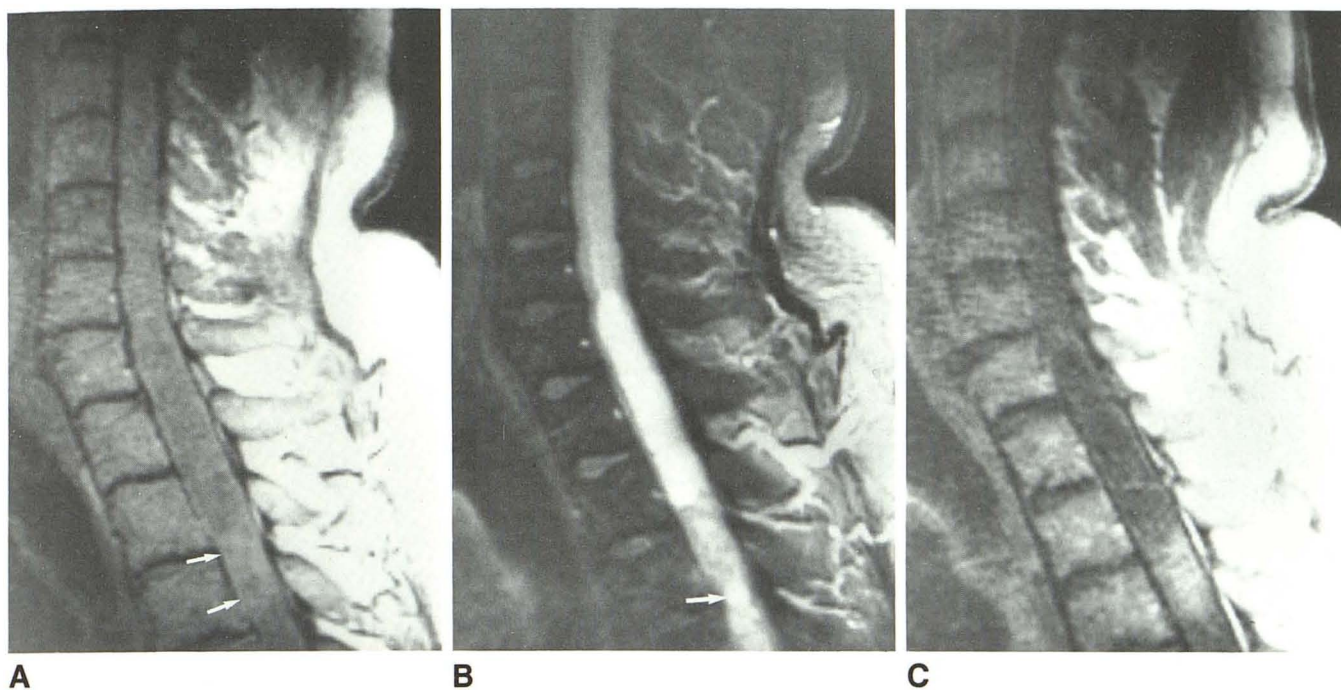


Fig. 2.—Case 6: 53-year-old man with tight, bandlike pain across upper chest. Surgical pathology: ependymoma.

A, Short TR (667/20) cardiac-gated sagittal scan discloses extensive region of cord enlargement in cervical and upper thoracic areas. Most of the cord appears mildly hypointense, although focus of slightly higher intensity is present (arrows).

B, Long TR (2034/70) cardiac-gated sagittal scan suggests cyst with high-intensity fluid; above and below is cord parenchyma, which is of lesser but still abnormal hyperintensity. Probable smaller cysts are seen below (arrow).

C, Contrast-enhanced short TR (666/20) cardiac-gated sagittal scan confirms isolated enhancing tumor nodule inferiorly with cyst above and probably below. The fact that tumor was localized and focal was confirmed at surgery. No enhancement is seen around lateral and superior aspects of cervical cyst. Cyst appears benign and reactive, rather than tumorous, despite its proteinaceous content and shortened T1 and T2 relaxation times compared with normal surrounding CSF.

symptoms and signs referable to the cord were quiescent, did not demonstrate accumulation of gadolinium-DTPA in the lesions. However, another patient with presumed multiple sclerosis and active disease also did not show any enhancement.

Discussion

The best use for gadolinium-DTPA in the evaluation of intramedullary disease of the spinal cord will probably lie between the extremes of intradural extramedullary lesions and extradural tumors [7, 8]. Unlike intradural extramedullary lesions, intramedullary disease usually is well seen with high-quality noncontrast MR. Therefore, in our series, we found that contrast enhancement did not help significantly in detection. However, unlike MR of extradural tumors of the spine, the administration of gadolinium-DTPA does not routinely obscure lesions. In addition, noncontrast MR scans sometimes fail to delineate precisely the extent of the cord lesion and to characterize its components. For example, low-intensity regions in the central portions of the cord in a patient with intramedullary tumor may resemble a cyst; yet no cyst is found at surgery [1, 9]. Similarly, regions of tumor that appear to be solid may be found to be composed of proteinaceous cysts [9]. Because of these problems, often unresolved with-

out contrast material, it is likely that gadolinium-DTPA will be of greater use in suspected cord lesions than in extradural spinal tumors [10–12].

In this study, we demonstrated that gadolinium-DTPA is useful in the delineation and characterization of intramedullary lesions. Enhancement of a focus in a region of cord enlargement is valuable information. In cases of hemangioblastoma, it may pinpoint the nidus of the lesion (Fig. 4). Most likely, the same principle holds true with cord metastases (Fig. 5). In both instances, demonstration of the exact location of the tumor can affect therapy. With hemangioblastomas, more accurate operative intervention should be possible, enabling the use of a smaller surgical exposure and reducing the necessity of extensive exploration. With metastases, radiation ports can be narrowed to cover the actual focus of tumor.

In gliomas, contrast material should also prove beneficial. Noncontrast long TR scans show entire regions of cord enlargement to be of increased signal. The most neoplastic regions of the tumor often cannot be delineated. Biopsy is performed at several locations and may still reveal only gliosis or normal tissue. With gadolinium enhancement, information can be obtained that can be of great help in surgery. First, areas of presumably more neoplastic tissue will enhance, allowing accurate biopsy or removal. Second, regions of cord enlargement that may represent primarily edema or mild tumor infiltration can be avoided. Third, tumor cysts should be

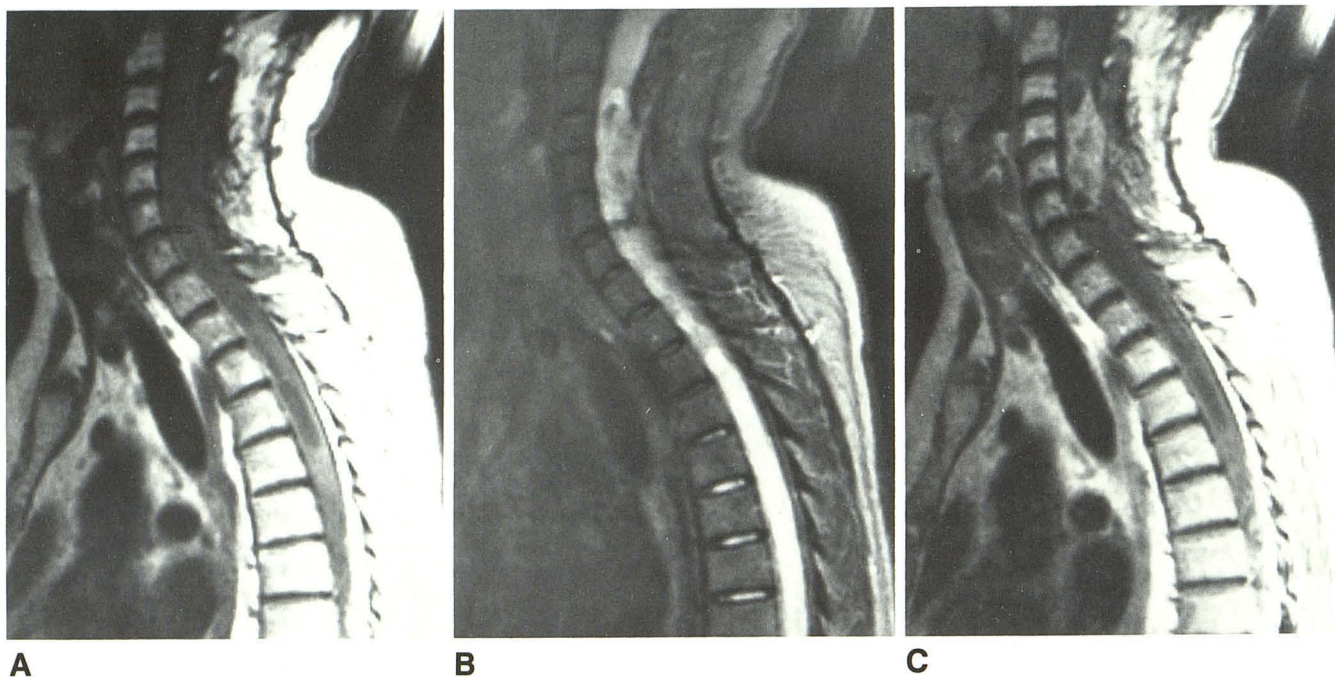


Fig. 3.—Case 10: 47-year-old woman 5 years after resection of cervical astrocytoma, presenting with recurrent symptoms.
 A and B, Short (600/20) and long (2118/70) TR sagittal sections disclose extensive cervical postoperative changes, with diffuse widening and some angulation of cord. Caudal cysts are noted.
 C, Gadolinium-enhanced short TR (600/20) sagittal section shows enhancing recurrent tumor mass confined to midcervical spine, distorted by postsurgical tethering and adhesions. Much of inferior cord enlargement appears to be from combination of edema, cyst formation, and postoperative change.

assessed more definitively. In occasional cases, gadolinium enhancement may show delineation of tumor in regions somewhat different from what might be expected without contrast material. For example, in one case, enhancement of tumor in a mildly enlarged cord was seen extending considerably below the level of the previous laminectomy. Evaluation before surgery had been difficult due to the patient's marked scoliosis and multiple adhesions from prior operations.

Characterization of lesions also is improved with contrast enhancement. Enhancement of gliomas most likely is seen in more active tumors, such as occur in the head, by showing regions of greater blood-brain barrier breakdown. Therefore, the presence or absence of uptake of gadolinium-DTPA may provide information important in prognosis and therapy. Clinicians may choose to follow more benign-appearing gliomas that do not enhance significantly, rather than advocate surgical exploration. Whether regions of more active blood-brain barrier breakdown will correlate with areas of higher grade, as in the head, still remains to be determined. All of our cord astrocytomas were grades I and II. Therefore, our experience suggests that gliomas of the cord will demonstrate a greater tendency to accumulate contrast material than gliomas of the brain do, regardless of grade. In addition, delayed accumulation of contrast media in cord tumors probably correlates with necrotic tissue (Fig. 1). This phenomenon has been documented in cerebral tumors, both with conventional iodinated contrast material and with gadolinium-DTPA [13, 14], and was demonstrated in one of our cases.

Contrast material also can help to characterize syringes. Both neoplastic and benign syringes can be associated with regions of high signal in the adjacent cord on long TR images [15]. These regions represent tumor and edema in patients with neoplasms, while they have been shown to consist of gliosis when found in benign cases. Although the shape of the syrinx often is sufficient to suggest a nontumor origin, in some cases, both morphology and signal-intensity changes alone are not sufficient to determine whether a syrinx is neoplastic or benign. In this clinical setting, contrast material can be used to enhance neoplastic foci. Since very small neoplasms can be associated with huge cysts [16], enhancement should be helpful in localizing tumor.

Contrast material also provides additional information even when known neoplasm is present. Rostral and caudal cysts associated with a neoplasm often are benign [1]. In a review of 155 autopsy-proved cord tumors associated with cavities, Poser [17] reported that the cyst originated within the tumor in approximately 13% of cases while it was adjacent to, but not part of, the tumor in approximately 74% of cases. In the latter situations, the cyst either started abruptly where the tumor ended or was separated from the tumor by small regions of gliosis. These rostral and caudal cysts typically lack malignant cells [18] and have gliotic linings, in contrast to tumor cysts [16]. However, like tumor cysts, the fluid within them may be highly xanthochromic and proteinaceous [16] and can exhibit decreased T1 and T2 relaxation times compared with normal CSF (Figs. 1 and 2). In these cases, lack

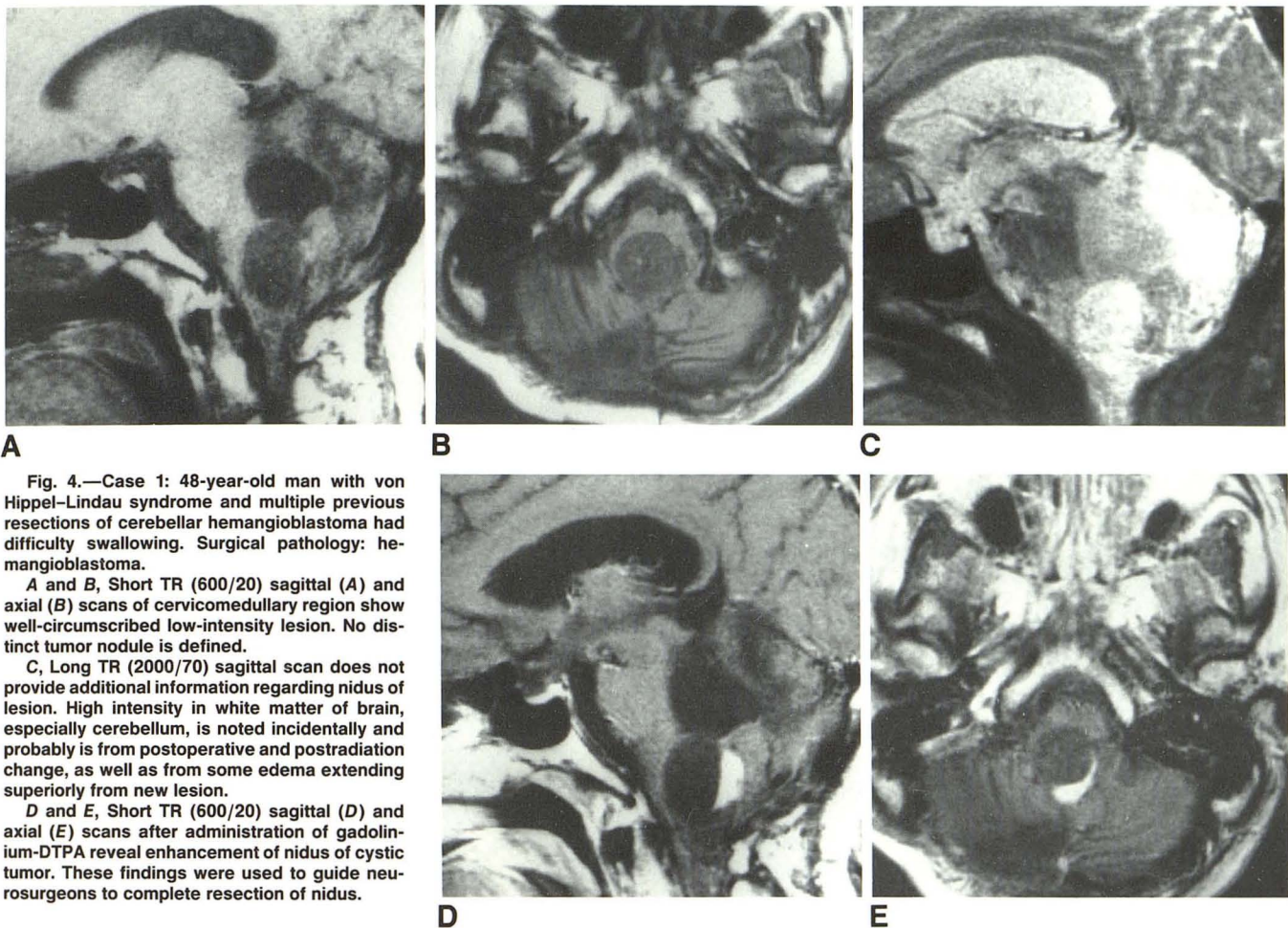


Fig. 4.—Case 1: 48-year-old man with von Hippel-Lindau syndrome and multiple previous resections of cerebellar hemangioblastoma had difficulty swallowing. Surgical pathology: hemangioblastoma.

A and B, Short TR (600/20) sagittal (**A**) and axial (**B**) scans of cervicomedullary region show well-circumscribed low-intensity lesion. No distinct tumor nodule is defined.

C, Long TR (2000/70) sagittal scan does not provide additional information regarding nidus of lesion. High intensity in white matter of brain, especially cerebellum, is noted incidentally and probably is from postoperative and postradiation change, as well as from some edema extending superiorly from new lesion.

D and E, Short TR (600/20) sagittal (**D**) and axial (**E**) scans after administration of gadolinium-DTPA reveal enhancement of nidus of cystic tumor. These findings were used to guide neurosurgeons to complete resection of nidus.

of enhancement surrounding cysts extending inferiorly or superiorly from the tumor is suggestive of syringes that have formed as a reactive response to the neoplasm, rather than as part of it. This information can be particularly reassuring if the rostral or caudal cysts are proteinaceous and somewhat irregular, rather than smooth, in outline (Fig. 2). Accurate characterization of the cord surrounding these cysts may allow a much more limited operation to be performed since only the primary tumor nidus needs to be exposed and removed. The reactive cysts can be drained rather than excised [16].

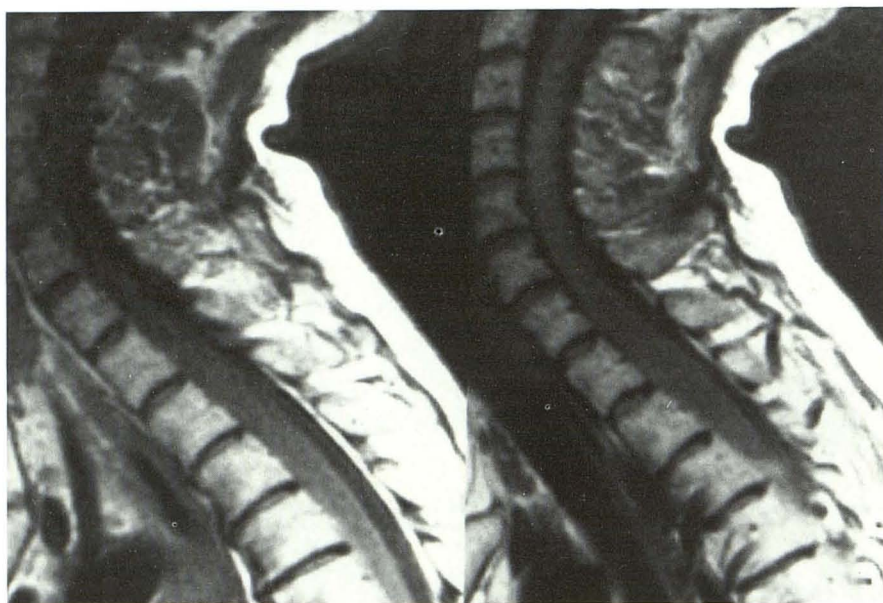A similar advantage may be found in contrast enhancement of nonneoplastic lesions of the cord. Our thrombosed vascular malformations were surrounded by high intensity on long TR images, presumably due to surrounding edema and/or gliosis. However, lack of additional enhancement surrounding a hemorrhage may well suggest a benign cause. While total lack of enhancement may not absolutely exclude a hemorrhagic non-enhancing glioma, the majority of gliomas of the cord do seem to enhance. In addition, of course, other tumors frequently associated with hemorrhage, such as hemangioblastomas and certain types of metastases, also would be expected to enhance.

Uptake of gadolinium-DTPA also may suggest activity of

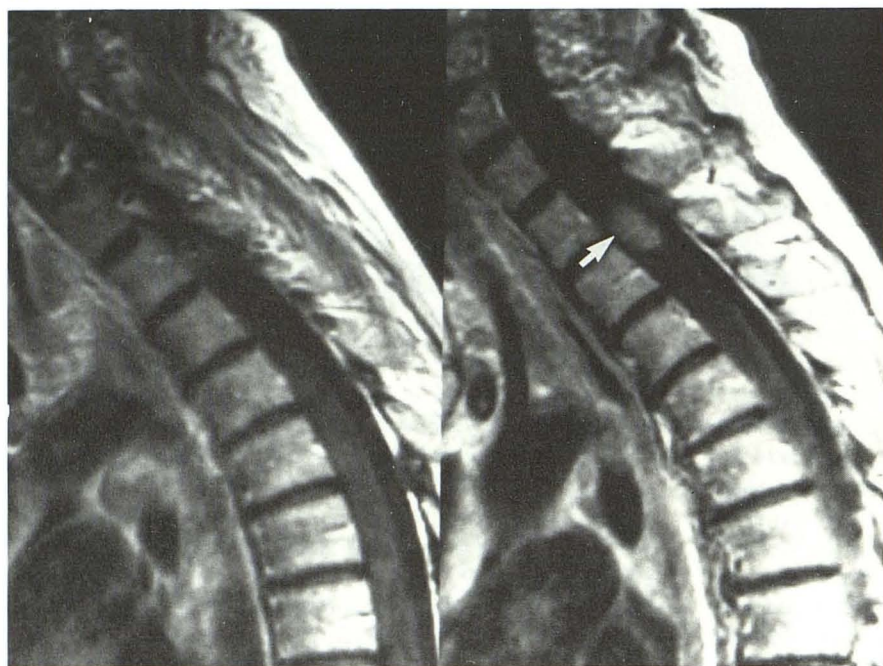
lesions. Contrast enhancement of multiple sclerosis plaques can be associated with more acute and clinically active lesions in the head [19]. Although we could not demonstrate marked enhancement in our three cases (two active) of multiple sclerosis involving the cord, further work will document whether this association will apply to the spine also. Mild enhancement has also been noted in cord infarcts and in slowly flowing vessels of spinal arteriovenous malformations [11].

Contrast enhancement undoubtedly will prove useful in follow-up after surgery and radiation therapy of patients with cord neoplasms. Again, both postsurgical and postradiation changes can produce high signal on long TR images, due to regions of edema and trauma or demyelination. However, enhancement should prove an important method with which to differentiate residual and/or recurrent tumor from post-therapy changes, as illustrated in Figure 3.

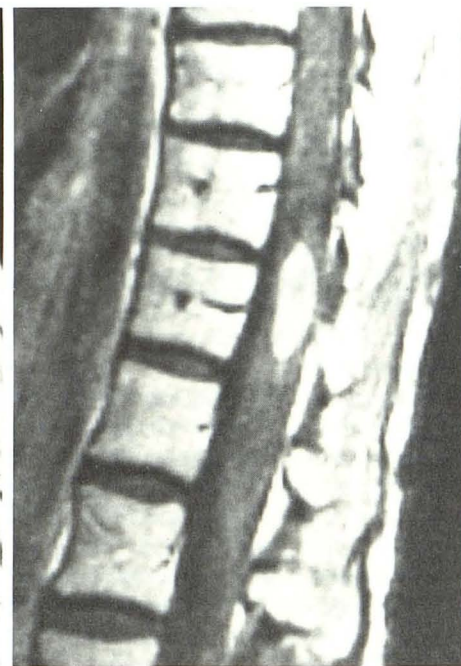
Two of our patients with extremely strong clinical suspicions for intramedullary lesions had gadolinium-enhanced scans, despite high-quality short and long TR precontrast scans that were normal. The postcontrast scans also proved to be negative. Although these numbers are small, they support our basic hypothesis that lesions will be detected without contrast material, even though the gadolinium will



A



B



C

Fig. 5.—Case 4: 45-year-old woman with breast carcinoma and lower extremity weakness and paresthesias. Clinical diagnosis: intramedullary metastasis.

A, Short TR (600/20) sagittal scan shows cord widened over considerable portion of cervical and upper thoracic spine.

B, After administration of gadolinium-DTPA, short TR (600/20) sagittal scan discloses localized region of enhancement, probably representing focal metastasis (arrow). Remainder of cord enlargement most likely is due to edema.

C, Additional short TR (600/20) sequences after administration of gadolinium-DTPA reveal second, clinically unsuspected intramedullary metastasis in distal thoracic cord.

help in their characterization and delineation. Perhaps an exception may occur with patients who have multiple metastases or hemangioblastomas in proximity to each other. In these cases, edema may obscure smaller lesions that might enhance and become visible after the administration of contrast material. However, if noncontrast scans are negative, then gadolinium-enhanced scans probably will not offer further information.

Finally, with reports appearing in our literature regarding gadolinium enhancement in the spine [7, 8, 10–12], it is now possible to suggest the direction of future contrast enhance-

ment in spinal MR imaging. Haphazard and random use of gadolinium-DTPA probably is contraindicated. Most likely, patients with neck or back pain or with neurologic symptoms referable to the spine will have nonenhanced MR. These studies will be most appropriate for the evaluation of possible metastatic lesions or disk disease. In addition, initial noncontrast scans will avoid the commonly encountered phenomenon of vertebral body lesions that enhance to the same intensity as normal marrow after the administration of gadolinium-DTPA [8]. If only epidural lesions are visible, contrast material probably will be reserved for specific clinical situa-

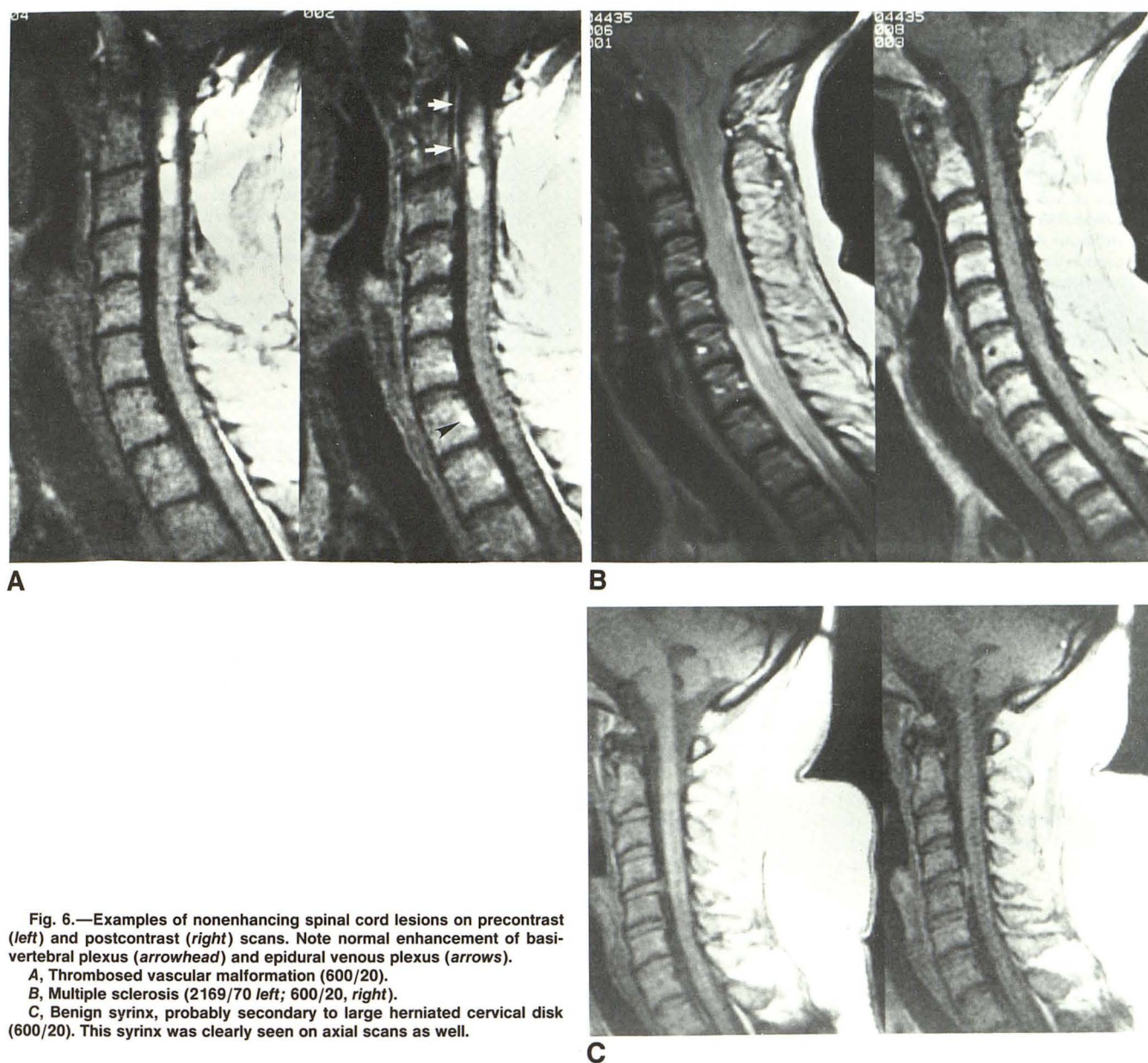


Fig. 6.—Examples of nonenhancing spinal cord lesions on precontrast (left) and postcontrast (right) scans. Note normal enhancement of basivertebral plexus (arrowhead) and epidural venous plexus (arrows).

A, Thrombosed vascular malformation (600/20).

B, Multiple sclerosis (2169/70 left; 600/20, right).

C, Benign syrinx, probably secondary to large herniated cervical disk (600/20). This syrinx was clearly seen on axial scans as well.

tions, for example, the patient with failed back surgery [20]. However, if intramedullary or intradural extramedullary disease is noted, contrast enhancement probably will become routine. Finally, if persistent or increasing symptoms result or if possible surgery is contemplated, contrast enhancement may be considered to rule out possible subtle intradural extramedullary disease, for example, the patient with back pain who has a very small neurofibroma that may not be adequately assessed without contrast material [7]. Similarly, in patients with a high degree of suspicion for leptomeningeal tumor spread, contrast material will be indicated [7]. These suggestions undoubtedly are simplified; specific clinical situations may be assessed best either with or without the administration of gadolinium-DTPA. As our knowledge of contrast enhancement in MR of the spine increases, it should

be possible to construct a set of algorithms for the appropriate use of gadolinium-DTPA.

REFERENCES

1. Goy AMC, Pinto RS, Raghavendra BN, Epstein FJ, Kricheff II. Intramedullary spinal cord tumors: MR imaging, with emphasis on associated cysts. *Radiology* 1986;161:381-386
2. Maravilla KR, Weinreb JC, Suss RA, et al. Magnetic resonance demonstration of multiple sclerosis plaques in the cervical cord. *AJNR* 1984;5:685-689, *AJR* 1985;144:381-385
3. Lee BCP, Zimmerman RD, Manning JJ, et al. MR imaging of syringomyelia and hydromyelia. *AJNR* 1985;6:221-228
4. Pojunas K, Williams AL, Daniels DL, Haughton VM. Syringomyelia and hydromyelia: magnetic resonance evaluation. *Radiology* 1984;153:679-693
5. Di Chiro G, Doppman JL, Dwyer AJ, et al. Tumors and arteriovenous

- malformations of the spinal cord: assessment using MR. *Radiology* **1985**;156:689-697
6. Quencer RM, Morse BMM, Green BA, Eismont FJ, Brost P. Intraoperative spinal sonography: adjunct to metrizamide CT in the assessment and surgical decompression of posttraumatic spinal cord cysts. *AJR* **1984**;142:593-601
7. Sze G, Krol G, Abramson A, et al. Gadolinium-DTPA in the evaluation of intradural extramedullary spinal disease. *AJNR* **1988**;9:165-163, *AJR* **1988**;150:911-921
8. Sze G, Krol G, Zimmerman RD, Deck MDF. Malignant extradural spinal tumors: MR imaging with Gd-DTPA. *Radiology* **1988**;167:217-223
9. Rubin JM, Aisen AM, DiPietro MA. Ambiguities in MR imaging of tumoral cysts in the spinal cord. *J Comput Assist Tomogr* **1986**;10:395-398
10. Yoshikawa K, Aoki S, Momose T, et al. Gd-DTPA as a contrast agent in MR imaging of spinal intramedullary tumors. Presented at the annual meeting of Society of Magnetic Resonance in Medicine, Montreal, Canada, August **1986**
11. Dillon WP, Bolla K, Mark AS, Tsuruda JS, Norman D, Newton TH. Gd-DTPA MR imaging enhancement of spinal cord tumors. Presented at the annual meeting of Radiological Society of North America, Chicago, December **1987**
12. Bydder GM, Brown J, Niendorf HP, et al. Enhancement of cervical intraspinal tumors in MR imaging with intravenous gadolinium-DTPA. *J Comput Assist Tomogr* **1985**;9:847-851
13. Norman D, Stevens EA, Wing SD, Levin V, Newton TH. Quantitative aspects of contrast enhancement in cranial CT. *Radiology* **1978**;129:684-688
14. Schorner W, Laniado M, Niendorf HP, Schubert CHR, Felix R. Time-dependent changes in image contrast in brain tumors after gadolinium-DTPA. *AJNR* **1986**;7:1013-1020
15. Sherman JL, Barkovich AJ, Citrin CM. The MR appearance of syringomyelia: new observations. *AJNR* **1986**;7:985-995
16. Epstein F, Epstein N. Surgical treatment of spinal cord astrocytomas of childhood: a series of 19 patients. *J Neurosurg* **1982**;57:685-689
17. Poser CM. The relationship between syringomyelia and neoplasm. In: *American lecture series, #262: American lectures in neurology*. Springfield, IL: Thomas, **1956**:28-32
18. Quencer RM. Needle aspiration of intramedullary and intradural extramedullary masses of the spinal canal. *Radiology* **1980**;134:115-126
19. Grossman RI, Gonzalez-Scarano F, Atlas SW, Galetta S, Silberberg DH. Multiple sclerosis: gadolinium enhancement in MR imaging. *Radiology* **1986**;161:721-725
20. Hueftle MG, Modic M, Ross JS, et al. Postoperative epidural fibrosis versus recurrent disk herniation in the lumbar spine: assessment with Gd-DTPA enhanced MR imaging. Presented at the annual meeting of the Radiological Society of North America, Chicago, December **1987**