



Discover Generics

Cost-Effective CT & MRI Contrast Agents



FRESENIUS
KABI

[VIEW CATALOG](#)

AJNR

Synovial cyst of the cervical spine: case report and review of the literature.

S C Patel and W P Sanders

AJNR Am J Neuroradiol 1988, 9 (3) 602-603

<http://www.ajnr.org/content/9/3/602.citation>

This information is current as
of September 1, 2025.

Synovial Cyst of the Cervical Spine: Case Report and Review of the Literature

Suresh C. Patel,¹ William P. Sanders

True synovial cysts of the spine are rare though they are included in the differential diagnosis of an extradural lesion in a patient with radicular pain or pain localized in the involved level of the spine. We present the second reported case of a synovial cyst of the cervical spine, and review the literature.

Case Report

A 42-year-old woman was in good health until 2 years before admission, when she began to have right-sided neck pain radiating to the right shoulder. This progressed in severity for 18 months, at which time she began having episodes of spontaneous torticollis accompanied by muscle spasms in her neck and right shoulder. In addition, she experienced infrequent episodes of tingling in her right arm, especially when her head was turned to the left, against the spastic muscles. There were no complaints of motor problems in the extremities, and no history of trauma.

On physical examination, the patient's head was turned to the right, with contraction of the sternocleidomastoid muscle and elevation of the right shoulder. The cranial nerves were intact, and there were no sensory or motor abnormalities. Laboratory studies were normal, including sedimentation rate, rheumatoid factor, and antinuclear antibody. Clinical diagnosis was neurogenic torticollis.

Radiographs of the cervical spine revealed grade-I spondylolisthesis of C4 on C5, with mild disk space narrowing. There was a hypertrophic spur seen on the posterior aspect of the superior endplate of C5, and slight irregularity of the superior aspect of the C5 facet (Fig. 1). Pleuridirectional tomography disclosed erosion of the inferior and superior facet margins on the right at C4–C5 (Figs. 2 and 3). The margins were slightly irregular, with bone erosion, and were accompanied by mild eburnation of the joint surface. The joint space itself appeared widened, probably due to effusion. CT with first-generation scanners, both with and without contrast, again demonstrated the facet erosion with no soft-tissue mass seen in the periarticular area. Myelography was not performed.

At surgery, a soft-tissue mass was seen protruding between the laminae on the right at C4–C5. Partial laminectomy of the inferior aspect of the C4 lamina revealed a cystic mass in the region of the facet joint itself, causing widening of the joint space. The mass was easily dissected free of the C5 nerve root, which had been compressed by the cyst. Clear fluid was obtained from the cyst.

Histologic examination revealed fibrous tissue walls with a lining of reactive synovial cells (Fig. 4).

Discussion

True synovial cysts of the spine are rare. Our review of the literature revealed only 31 pathologically proved cases of synovial cyst in the spine. Pendleton et al. [1] cite 19 reported cases, all in the lumbar spine. The present report is only the second description of a synovial cyst in the cervical spine [2]. While their cause is unknown, these cysts are believed to develop as a result of degenerative joint disease or, less often, trauma [3] to the involved joint. It is worthwhile to note that 28 of the 29 reported lumbar cysts [1, 4–22] were at either the L4–L5 or L5–S1 levels, which are well known to represent those segments with the greatest amount of mobility and the most common sites for degenerative disease. In the cervical spine, C4–C5 through C6–C7 are the sites with a predilection for degenerative disease, and our case, as well as that of Kao et al. [2], is compatible with this hypothesis. Synovial cysts are also known to occur in rheumatoid arthritis, with one case of a rheumatoid with a cyst in the lumbar spine [12]. The present case had no clinical or biochemical evidence of rheumatoid arthritis.

Radiographically, the most common findings are nonspecific. Degenerative changes with eburnation and hypertrophic spurring of the facet, occasional disk space narrowing, and mild spondylolisthesis were the abnormalities usually seen on plain radiographs. Myelography usually revealed an extradural mass not immediately adjacent to the disk space. Of some diagnostic importance is erosion and widening of the involved facet itself due to effusion and hypertrophic synovium. This finding is nicely demonstrated with plain tomography (Figs. 2 and 3) as well as with CT [10–14]. Occasionally, calcium may be seen in the wall of the cyst, best shown by CT [10, 13].

Radiographically, the differential diagnosis is usually between a herniated disk or an extradural cyst. The presence of erosive changes in the involved facet, the posterior location of the cyst, and only occasional coexistence of disk disease help to differentiate the synovial cyst from a herniated disk. Extradural tumors and arachnoid cysts usually result in thinning of the pedicles and laminae. Other cysts of the spine, such as cystic neoplasm, parasitic cysts, and perineural cysts of Tarlov [23], are extremely rare and are not associated with advanced degenerative disease of the facet joints.

Received July 18, 1986; accepted after revision October 30, 1986.

¹ Both authors: Division of Neuroradiology, Henry Ford Hospital, 2799 W. Grand Blvd., Detroit, MI 48202. Address reprint requests to S. C. Patel, K-3.

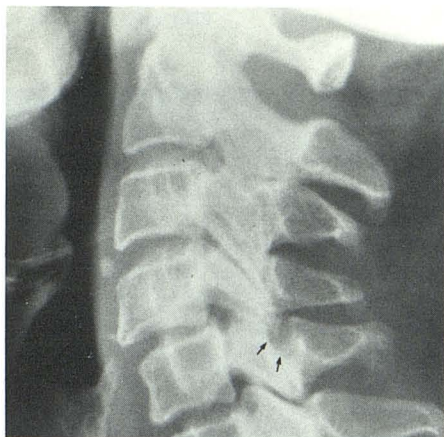


Fig. 1.—Lateral view of cervical spine demonstrates grade-I spondylolisthesis of C4 on C5 with small hypertrophic spur on superior endplate of C5. Note irregularity of superior aspect of C5 facet (arrows).

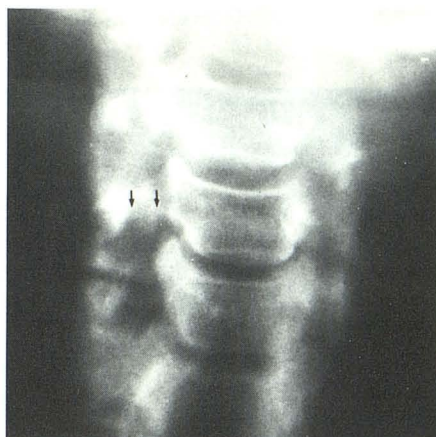


Fig. 2.—Anteroposterior tomogram displays erosion of inferior aspect of lateral mass of C4 on the right (arrows).

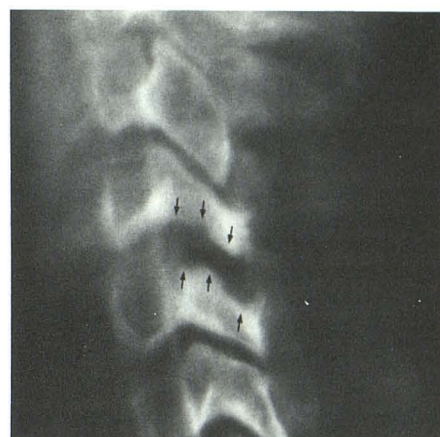


Fig. 3.—Lateral tomogram reveals marked erosion of superior facet of C5 (arrows). Note widening of facet joint compared with other levels.

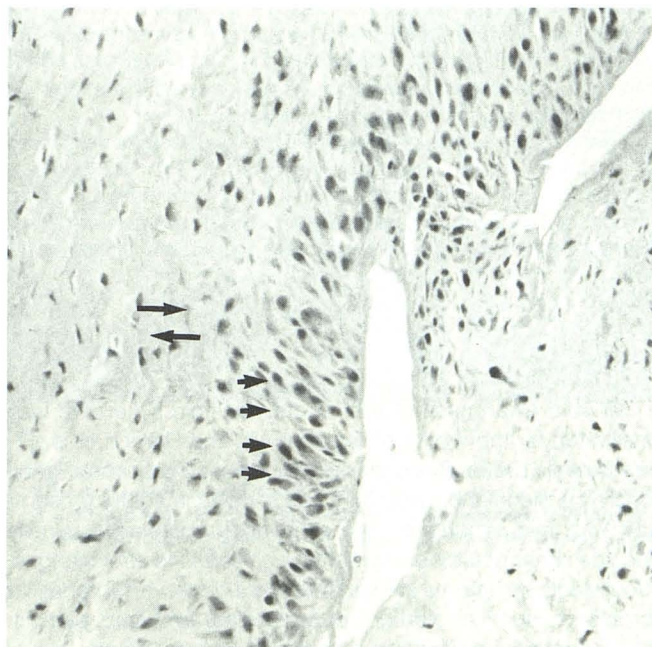


Fig. 4.—Low-power photomicrograph displays fibrous wall (long arrows) with synovial cell lining (short arrows).

In summary, the second reported case of a true synovial cyst of the cervical spine has been presented, along with a review of the literature and a discussion of the radiologic findings and a possible cause.

REFERENCES

1. Pendleton B, Barton C, Pollay M. Spinal extradural benign synovial or ganglion cyst: case report and review of the literature. *Neurosurgery* 1983;13:322-325
2. Kao CC, Winkler SS, Turner JH. Synovial cyst of spinal facet. Case report. *J Neurosurg* 1974;41:372-376
3. Sybert GW, Leech RW, Harris AB. Post-traumatic lumbar epidural true synovial cyst: case report. *J Neurosurg* 1973;39:246-248
4. Kao CC, Uihlein A, Bickel WH, Soule EH. Lumbar intraspinal extradural ganglion cyst. *J Neurosurg* 1968;29:168-172
5. Maresca L, Meland NB, Maresca C, Field EM. Ganglion cyst of the spinal canal. *J Neurosurg* 1982;57:140-142
6. Gritzka TL, Taylor TKF. A ganglion arising from a lumbar articular facet associated with low back pain and sciatica. *J Bone Joint Surg* 1970;52B(3):528-531
7. Brish A, Payan HM. Lumbar intraspinal extradural ganglion cyst. *J Neurol Neurosurg Psych* 1972;35:771-775
8. Haase J. Extradural cyst of ligamentum flavum L4—a case. *Acta Orthop Scand* 1972;43:32-38
9. Bhushan C, Hodges FJ III, Wityk JJ. Synovial cyst (ganglion) of the lumbar spine simulating extradural mass. *Neuroradiology* 1979;18:263-268
10. Hemminghytt S, Daniels DL, Williams AL, Haughton VM. Intraspinal synovial cysts: natural history and diagnosis by CT. *Radiology* 1982;145:375-376
11. Schulz EE, West WL, Hinshaw DB, Johnson DR. Gas in a lumbar extradural juxtaarticular cyst: sign of synovial origin. *AJR* 1984;143:875-876
12. Mercader J, Gomez JM, Cardenal C. Intraspinal synovial cyst: diagnosis by CT. *Neuroradiology* 1985;27:346-348
13. Casselman ES. Radiologic recognition of symptomatic spinal synovial cysts. *AJNR* 1985;6:971-973
14. Kieffer SA, Kricheff II. Case presented to the neuroradiology film interpretation session, 1985 meeting of the RSNA, November 1985. *Radiographics* 1986;6:306-310
15. Abdullah AF, Chambers RW, Daut DP. Lumbar nerve root compression by synovial cysts of the ligamentum flavum: report of four cases. *J Neurosurg* 1984;60:617-620
16. Lindquist PR, McDonnell DE. Rheumatoid cyst causing extradural compression. A case report. *J Bone Joint Surg* 1970;52(6):1235-1240
17. Eggert HR, Agnoli AL, Mennel HD. Lumbar intraspinal ganglion cyst. *Acta Neurochir (Wien)* 1981;59:263-266
18. Faivre J, Jan M, Ramee MP. Sciatique raiculaire par kyste mucoide intrarachidien chez un enfant. *Neurochirurgie* 1983;13:322-325
19. Schollner D. Ganglion an einem Wirbelgelenk. *Z Orthop* 1967;102:619-621
20. Zoch K. Über ein Vertebrales Gelenkschlanglion mit den Symptomen der Intraspinalen Raumforderung. *Neurol Neurochir Pol* 1969;105:323-327
21. Zarza FM, Diag AA. Ganglion quístico epidural lumbar como causa de lumbosciatalgia. *Rev Esp Oto Neuro-oftalm* 1971;29:197-202
22. Chen KTK. Synovial cyst of the spinal facet joint (ltr). *Arch Pathol Lab Med* 1983;7:100-101
23. Tarlov IM. Spinal perineural and meningeal cysts. *J Neurol Neurosurg Psychiatry* 1970;33:833-843