



CT-guided needle aspiration biopsy of an intraspinal synovial cyst (ganglion): case report and review of the literature.

J J Abrahams, G W Wood, F A Eames and R W Hicks

AJNR Am J Neuroradiol 1988, 9 (2) 398-400
<http://www.ajnr.org/content/9/2/398.citation>

This information is current as of August 1, 2025.

CT-Guided Needle Aspiration Biopsy of an Intraspinial Synovial Cyst (Ganglion): Case Report and Review of the Literature

James J. Abrahams,^{1,2} Gary W. Wood, Fredrick A. Eames, and Richard W. Hicks

Ganglions (synovial cysts) are cystic or semicystic lesions found most commonly in the wrist, dorsum of the foot, or knee. They may or may not be continuous with the joint space and may or may not have a synovial lining [1]. Some authors make a distinction between ganglions and synovial cysts, the latter being synovial-lined. Recently, several studies have reported the identification of synovial cysts in the spinal canal in relation to the facet joints. A review of the literature reveals a total of 17 cases previously reported (Table 1). Ten of these were surgically proved [2, 4–7], eight were evaluated by CT [6–8], and only two were evaluated by CT and subsequently proved at surgery [6, 7]. We report the first CT-guided needle aspiration biopsy of an intraspinal synovial cyst. This was subsequently proved at surgery.

Case Report

A 68-year-old woman presented with an 8-month history of right hip pain, which later radiated down the lateral aspect of the thigh and calf with numbness of the dorsum of the foot. There was no weakness, loss of bowel or bladder control, or exacerbation with coughing or sneezing. The pain improved with bed rest, but was not alleviated. Walking caused an increase in symptoms. Physical examination on admission revealed a right straight-leg raise to 60° with a positive Lasègue test. There was decreased sensation to the dorsum of the right foot after ambulation. The left side was normal.

Plain lumbosacral spine films were unremarkable except for mild hypertrophic changes. No destructive lesions were seen. A noncontrast-enhanced CT scan demonstrated a 1-cm round lesion in the posterior right lateral aspect of the spinal canal adjacent to the right L4–L5 facet joint (Fig. 1). The lesion had a slightly lower attenuation than the disk material and was surrounded by a ring of higher attenuation believed to represent mild calcification. The thecal sac was compressed and pushed in the anterior and left lateral directions. The facet joints demonstrated hypertrophic changes. Metrizamide lumbar myelography confirmed the round, smooth, extradural characteristics of this lesion and further delineated its posterior and right lateral position (Fig. 2). The L4–L5 disk was believed to be normal except for mild bulging (Fig. 2A). A CT-guided needle aspiration

biopsy was subsequently performed for diagnostic confirmation and therapeutic decompression. With the patient in the prone position, a 22-gauge needle was inserted just to the right of the L4 spinous process and directed between the lamina of L4 and L5. CT confirmed proper needle location within the lesion and three drops of a tenacious, stringy, translucent, straw-colored fluid were aspirated and sent to cytology (Fig. 3A). This fluid was reported to have no malignant cells and a few mesothelial cells. The cyst was then opacified with 0.3 ml of metrizamide 190 mg/ml concentration (Fig. 3B), and an 18-gauge spinal needle was inserted into the cyst in an unsuccessful attempt to aspirate more fluid. Owing to the degree of the patient's symptoms, a laminectomy and cystectomy were performed the next day. At surgery, an oval cystic lesion was seen to be incorporated into the ligamentum flavum and to extend from a hypertrophic L4–L5 facet joint. Pathologic evaluation demonstrated a thick, fibrous wall with calcium deposits and a few chronic inflammatory cells. The cyst contained an amorphous substance; no synovial lining was present (Fig. 4). Three weeks after surgery, the patient had made a complete recovery.

Discussion

The origin of intraspinal synovial cysts is disputed, with opinions ranging from herniation of synovium to cystic or mucinous degeneration of connective tissue [1, 9]. We believe that the intraspinal cysts described in the literature are all the same entity. The exception may be the case of a rheumatoid cyst described by Linquist et al. [10]. Whether or not these cysts are lined with synovium seems irrelevant, as chronic inflammatory reactions could erode or destroy the initial synovial lining. Also, cysts that once communicated with the joint could theoretically lose their communication. Therefore, whether these cysts are called synovial cysts or ganglion cysts is a matter of semantics. Either way, a review of the literature reveals a rather characteristic radiographic presentation.

The CT findings originally described by Hemminghytt et al. [6], and also reported by Casselman [7] and Mercader et al.

Received February 5, 1986; accepted February 26, 1986.

¹ All authors: Department of Radiology, Albany Medical Center Hospital, New Scotland Ave., Albany, NY 12208.

² Present address: Department of Neuroradiology, Yale-New Haven Medical Center, New Haven, CT 06510. Address reprint requests to J. J. Abrahams.

TABLE 1: Survey of Previously Reported Cases of Intraspinal Synovial Cysts

Author	Number of Cases Reported	Number Surgically Proved	Number Evaluated by Myelography	Number Evaluated by CT	Number Demonstrating Calcification	Number Demonstrating Spontaneous Resolution	Number with Normal Disk
Kao et al., 1968	3	3	2	0	2	NA	2
Zoch, 1969	1	1	1	NA	NA	NA	1
Sypert et al., 1973	1	1	1	0	NA	NA	NA
Bhushan et al., 1979	4	4	4	0	NA	NA	4
Hemminghytt et al., 1982	4	1	NA	4	4	3	NA
Mercader et al., 1985	3	0	NA	3	3	1	1
Casselmann, 1985	1	1	NA	1	1	NA	1

Note.—NA = no data available.

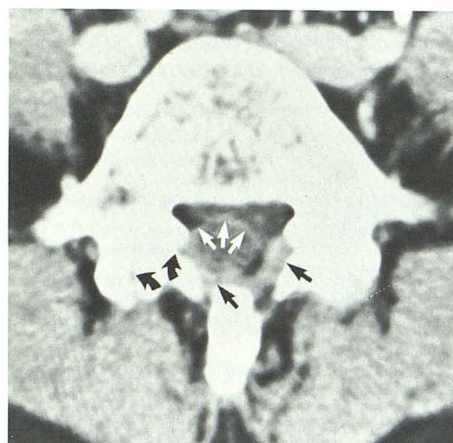


Fig. 1.—CT scan through L5 shows round, right, posterolateral lesion compressing dural sac. Note surrounding ring of high attenuation (*white arrows*), which was later shown to be caused by microscopic calcium deposits. The lesion arises from L4–L5 facet joint (*curved black arrows*) and appears to incorporate ligamentum flavum (*straight black arrows*) on right.

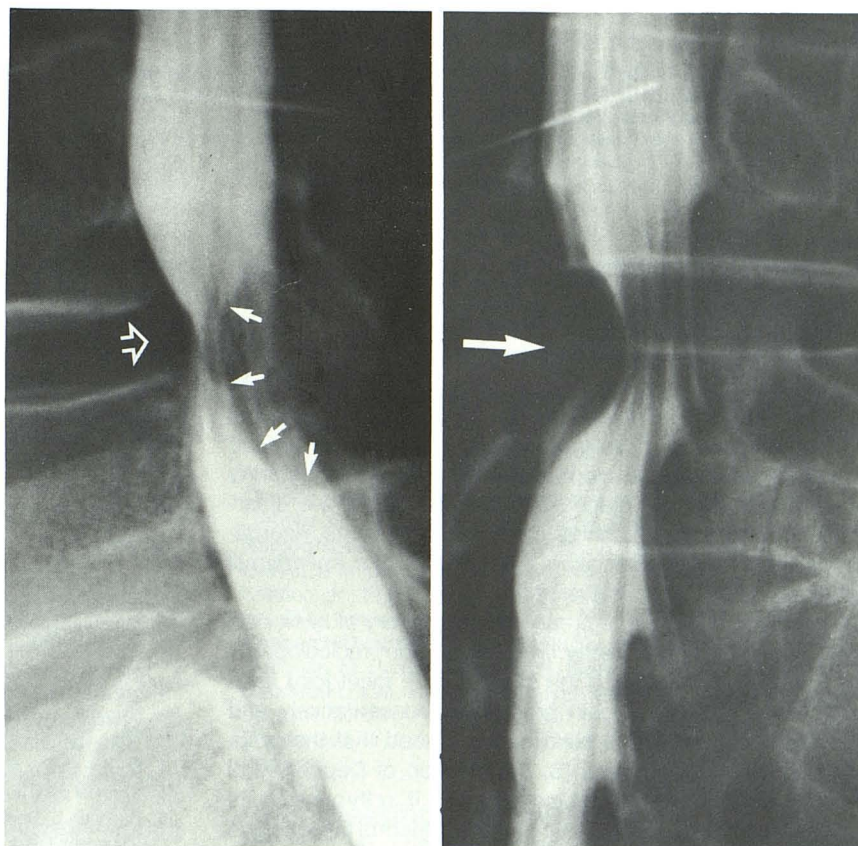


Fig. 2.—Metrizamide lumbar myelogram.

A, Lateral view shows posterior extradural defect (*closed arrows*) from the cyst and mild anterior extradural defect (*open arrow*) from bulging disk at L4–L5 level. No anterolateral defect is evident to suggest a herniated disk.

B, Oblique view again shows smooth, round, posterior extradural defect at L4–L5 level.

[8], are those of a round, roughly 1-cm extradural lesion located posterolaterally in relation to the L4–L5 facet. It is usually of lower attenuation than disk material and often has a surrounding rim of higher attenuation representing calcification within its wall. CT often reveals a normal disk and clearly demonstrates the facet joint arthrosis reported by most authors. On myelography, a smooth, rounded, posterolateral

extradural defect will be seen [2, 5]. If large enough, it may cause a complete block [4]. All cases have been located at the L4–L5 facet joint except one, which was at the L3–L4 facet [8]. In this case there was an L4–S1 arthrodesis 12 years earlier. The fact that these cysts occur at the L4–L5 facet appears to be related to the increased mobility at this level. It is of interest that the only L3–L4 lesion reported was

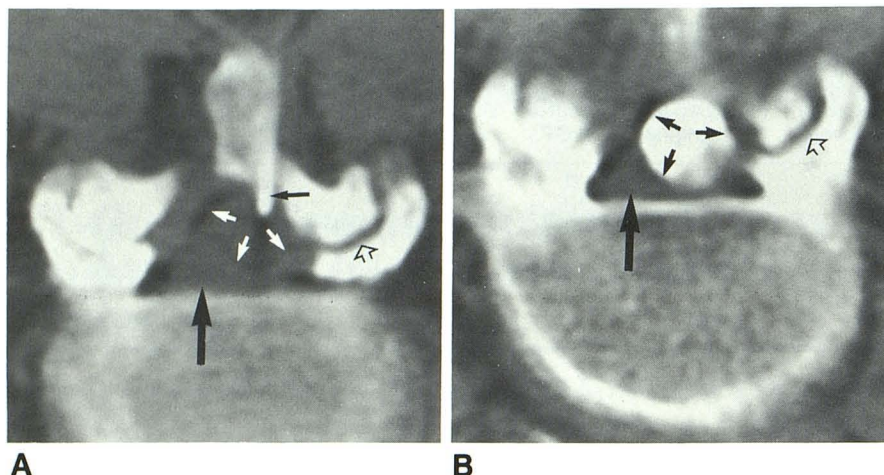


Fig. 3.—CT-guided needle aspiration biopsy and opacification of cyst with patient in prone position. **A**, CT confirms location of 22-gauge needle (small black arrow) within lesion (white arrows). Dural sac (large black arrow). Facet joint (open arrow). **B**, Opacification of cyst (small arrows) with metrizamide. Dural sac (large arrow). Facet joint (open arrow).

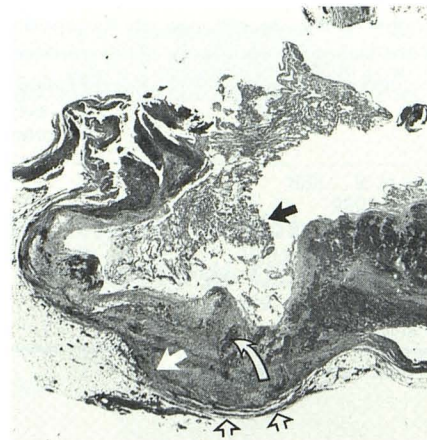


Fig. 4.—Photomicrograph of intraspinal cyst containing amorphous substance (solid black arrow). Thick fibrous wall (open arrows) contains ligamentum flavum (curved arrow) and tiny calcium deposits (white arrow). A few inflammatory cells are not resolved at this power.

in a patient with an arthrodesis. The radiographic presentation is probably diagnostic; however, common lesions in the differential diagnosis to be excluded are malignancies and herniated nucleus pulposus. Malignancies may demonstrate an associated soft-tissue mass or osseous destruction; circumferential calcification would be unlikely. A herniated nucleus pulposus would not usually present with a posterior defect, and demonstration of a normal disk on CT or myelography virtually excludes this diagnosis. Other lesions in the differential diagnosis are arachnoid cysts, dermoid cysts, neurofibroma with cystic degeneration, rheumatoid cysts, ependymal cysts, and perineural cysts of nerve roots.

Clinically, most patients present with a history of back pain with or without radiculopathy. In those without radiculopathy the pain is likely related to the degenerative facet joint itself [11]. These patients should be treated conservatively and followed by CT, as it has been demonstrated that the cysts may resolve spontaneously [6, 8]. Injection of Depo-Medrol into the facet joint may be considered. If arthrography is performed at the same time the Depo-Medrol injection is given, cyst opacification may confirm the diagnosis [7]. Some cysts, however, may not communicate with the joint. In those patients with radiculopathy, a more aggressive approach is warranted. In our case a needle aspiration biopsy was performed with the intention of decompressing the lesion and avoiding surgery. We were unsuccessful in decompressing the lesion, but opacification of the cyst confirmed the diagnosis. The lesion at surgery was semicystic with some solid components to which we attribute the difficulty in aspiration. When opacifying the cyst, caution should be taken not to introduce a large quantity of metrizamide, as the osmotic

effect could theoretically enlarge the lesion and cause exacerbation of symptoms. It is our belief that a needle aspiration is a reasonably safe diagnostic, and potentially therapeutic, procedure. If decompression is successful, the radiculopathy may diminish long enough to allow spontaneous resolution, and thus avoid the risk of surgery. Further evaluation of this technique is necessary to clarify its practical utility.

REFERENCES

1. Silberberg R. Diseases of joints. In: Kissane JM, ed. *Anderson's pathology*, 8th ed. St. Louis: Mosby, 1985:1842
2. Kao CC, Uihlein A, Bickle WH, Soule EH. Lumbar intraspinal extradural ganglion cyst. *J Neurosurg* 1968;29:168-172
3. Zoch K. Über ein vertebrales gelenksganglion mit den symptomen der interspinalen raumforderung. *Schweiz Arch Neurol Neurochir Psychiatr* 1969;105:323-327
4. Sybert GW, Leech RW, Harris AB. Posttraumatic lumbar epidural true synovial cyst. *J Neurosurg* 1973;39:246-248
5. Bhushan C, Hodges FJ III, Wityk JJ. Synovial cyst (ganglion) of the lumbar spine simulating extradural mass. *Neuroradiology* 1979;18:263-268
6. Hemminghytt S, Daniels DL, Williams AL, Haughton VM. Intraspinal synovial cysts: natural history and diagnosis by CT. *Radiology* 1982;145:375-376
7. Casselman ES. Radiologic recognition of symptomatic spinal synovial cysts. *AJNR* 1985;6:971-973
8. Mercader J, Munoz G, Cardenal C. Intraspinal synovial cyst: diagnosis by CT. *Neuroradiology* 1985;27:346-348
9. Soren A. Pathogenesis and treatment of ganglion. *Clin Orthop* 1966;48:173-179
10. Linquist PR, McDonnell DE. Rheumatoid cyst causing extradural compression. A case report. *J Bone Joint Surg* 1970;6:1235-1240
11. Guillermo FC, Haughton VM, Syvertsen A, Williams AL. Computed tomography of the lumbar facet joints. *Radiology* 1980;134:145-148