



Get Clarity On Generics

Cost-Effective CT & MRI Contrast Agents

 FRESENIUS
KABI

WATCH VIDEO

AJNR

CT appearance of traumatic dislocated lens.

R S Seigel, J Sell and D E Magnus

AJNR Am J Neuroradiol 1988, 9 (2) 390

<http://www.ajnr.org/content/9/2/390.citation>

This information is current as
of August 18, 2025.

CT Appearance of Traumatic Dislocated Lens

Robert S. Seigel,^{1,2} James Sell,¹ and David E. Magnus³

A case is presented that illustrates the appearance on CT of a traumatically dislocated lens.

Case Report

The patient was referred to the Eye Clinic for a detailed ocular examination to evaluate a high-density structure found within the right globe. Pertinent history included poor vision in the right eye after being struck by a chain 7 years earlier. The left eye was normal. Visual acuity tests revealed the right eye to be aphakic. The pupil was mid-dilated and unresponsive to light, and a slit-lamp examination revealed absence of a normally positioned lens. Intraocular pressure was normal. Fundoscopy revealed a posteriorly dislocated, cataractous lens floating in the vitreous in the posterior pole close to the retinal surface. A diagnosis was made of traumatic dislocation of the lens with aphakia, and traumatic pupil.

Discussion

A dislocated lens may occur spontaneously or secondary to trauma. In younger patients a number of ocular or systemic conditions may predispose to spontaneous lens dislocation, including simple ectopia lentis, Marfan syndrome, and hyperlysinemia. In older patients the most common cause of spontaneous lens dislocation is a mature or hypermature cataractous lens. However, trauma accounts for more than 50% of all cases [1].

Usually, a posteriorly dislocated lens is well tolerated, with the eye maintaining correctable vision without the development of glaucoma [2–5]. However, a number of complications may develop, such as retinal detachment, secondary glaucoma, poor vision, uveitis, and chorioretinal degeneration. These complications may be the result of small breaks in the lens capsule, which permit leakage of irritating liquified material from within the central substance of the lens into the surrounding vitreous [1]. In such cases surgical removal of the lens is warranted along with appropriate medical therapy to resolve glaucoma and uveitis.

The posteriorly dislocated lens was seen on CT as a lentiform-shaped mass with a broad base abutting the retinal

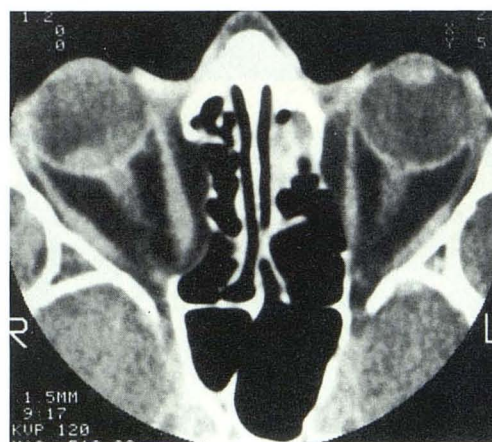


Fig. 1.—CT scan through level of mid-globes using a high-resolution 1.5-mm-thick axial section. Dislocated lens on right is seen as a high-density structure lying dependently against the retina. Lens on left is in normal position.

surface (Fig. 1). It was hyperdense relative to the surrounding vitreous.

It is important to make the initial observation that a normally positioned lens is not present to avoid the pitfall of misdiagnosing the dislocated lens as a primary mass of the posterior globe (melanoma, metastasis, granuloma, etc.). Comparison with the normally positioned contralateral lens will be helpful in this regard.

REFERENCES

1. Bass LJ, Potter JW. A case of spontaneous dislocated lenses. *Am J Optom Physiol Opt* 1985; 62(5):352–356
2. Suker GF. Dislocated lens in vitreous of 30 years standing in one eye. *Ophthal Rec* 1902;11:462
3. Hegner CA. Klinische Untersuchungen über die Prognose der intrabulbaren linsenluxationen. *Arch Augenheik* 1931;104:325
4. Cross FR. In discussion of Wray C. treatment of dislocation of lens. *Trans Ophthalmol Soc UK* 1914;34:167
5. McDonald PR, Purnell JE. Dislocated lens. *JAMA* 1951;145:220–226

Received February 13, 1986; accepted after revision July 2, 1986.

¹ Department of Radiology, University of New Mexico School of Medicine, Albuquerque, NM 87131. Address reprint requests to J. Sell.

² Present address: St. Anthony's Hospital, Main, 4231 W. 16th Ave., Denver, CO 80204.

³ Department of Optometry, VA Medical Center, Albuquerque, NM 87108.