



Providing Choice & Value

Generic CT and MRI Contrast Agents



**FRESENIUS
KABI**

CONTACT REP

AJNR

**The role of diskography after negative
postmyelography CT scans: retrospective review.**

I F Abdelwahab and E S Gould

AJNR Am J Neuroradiol 1988, 9 (1) 187-190

<http://www.ajnr.org/content/9/1/187>

This information is current as
of July 23, 2025.

The Role of Diskography After Negative Postmyelography CT Scans: Retrospective Review

I. Fikry Abdelwahab^{1,2}
Elaine S. Gould³

Review of our records for a 2-year period (1985–1986) yielded 15 patients in whom unequivocally normal myelograms and postmetrizamide CT scans had been obtained before diskography. In none of these patients was the diskogram or postdiskography CT scan positive for either central, posterolateral, or extreme lateral disk herniation. It was our experience that, with the new-generation, improved-resolution CT scanners with multiplanar reconstruction capabilities, diskography added no additional information, did not influence the surgeon's decision to operate, and was not a painless or innocuous procedure.

When an entirely negative, technically flawless postcontrast CT scan is obtained in a patient with back pain, diskography should not be performed, as it offers no further information.

Back pain, a major universal problem, has its impact on both disability and liability. Despite current diagnostic approaches, often no cause is found. This can be both perplexing and annoying to the surgeon, radiologist, and patient. The purpose of this study was to evaluate the role of diskography and postdiskography CT scans in 15 patients with back pain. All the patients had unequivocally normal lumbar myelograms and normal postmetrizamide CT scans. Diskography was requested by the orthopedic surgeons to further evaluate disk herniation. None of these patients had scoliosis, for which diskography could conceivably be performed before planning spinal fusion.

Materials and Methods

A review was undertaken of approximately 1600 metrizamide myelograms and postcontrast CT scans obtained in the past 2 years. In most instances, myelograms were followed by CT scans obtained with a third-generation Philips unit. Particular attention was given to the surgeon's clinical assessment of the particular disk level or levels involved. The usual scan thickness was 3 mm; however, 1.5- and 4.5-mm slices were obtained at the radiologist's discretion. The disk was scanned from end-plate to end-plate. Slices were routinely obtained above and below the pedicles for foraminal encroachment and to evaluate for extruded or lateral disk herniation. Usually, scans were obtained at L2–L3 to L5–S1; sagittal reconstruction was done, if possible.

Of the 1600 cases, diskograms were obtained in 50. In 17 of these 50 cases both the myelogram and postmyelogram CT scan were interpreted as negative; yet subsequent diskography was still performed. Two radiologists reviewed each case without knowledge of prior reports. Two of the 17 cases were not included in the final analysis because they were questionable technically: One patient was very obese, and contrast material was injected partially in the disk and partially extradural at the L4–L5 level. The follow-up CT scan was extremely limited owing to the artifacts created by the patient's size. The second patient had marked lumbar lordosis at the L5–S1 level, which made needle placement difficult. Some of the contrast material was not in the nucleus pulposus.

Of these 15 cases, 12 were women and three were men. They were 21–70 years old. All had low back pain of 2 weeks' to approximately 3 years' duration. Four patients had

Received January 13, 1987; accepted after revision June 3, 1987.

¹ Department of Radiology, Hospital for Joint Diseases, Orthopaedic Institute, New York, NY 10003, and New York University, New York, NY 10016.

² Present address: Department of Radiology, Mt. Sinai Medical Center, One Gustave L. Levy Place, New York, NY 10029. Address reprint requests to I. F. Abdelwahab.

³ Department of Radiology, North Shore University Hospital, Manhasset, NY 10030.

AJNR 9:187–190, January/February 1988
0195–6108/88/0901–0187

© American Society of Neuroradiology

associated radicular symptoms. Only one patient had prior back surgery. The most common disk levels injected, in decreasing order, were L4-L5, L5-S1, and L3-L4. Two or more disks were injected in 10 patients. All 15 patients had postdiskography CT scans. Approximately 1-1.8 ml of metrizamide (280 mg I/ml) was injected via the oblique or direct transdural approach, depending on the radiologist's preference. The patient's response during injection was recorded.

Results

In all 15 cases with normal myelograms and postcontrast CT scans, the diskogram and subsequent CT scans were

interpreted as negative, both initially and retrospectively. Two representative cases are illustrated. The first case was a 27-year-old woman who had had low back pain and right-sided radicular symptoms for approximately 3 months. Despite a normal myelogram (Fig. 1A) and postcontrast CT scan (Fig. 1B), a diskogram was requested at the L5-S1 level (Fig. 1C). This was interpreted as negative and was followed by a normal postdiskogram CT scan (Fig. 1D). Our second case was a 31-year-old woman with chronic low back pain. The initial myelogram (Fig. 2A) and postcontrast CT scan (Fig. 2B)

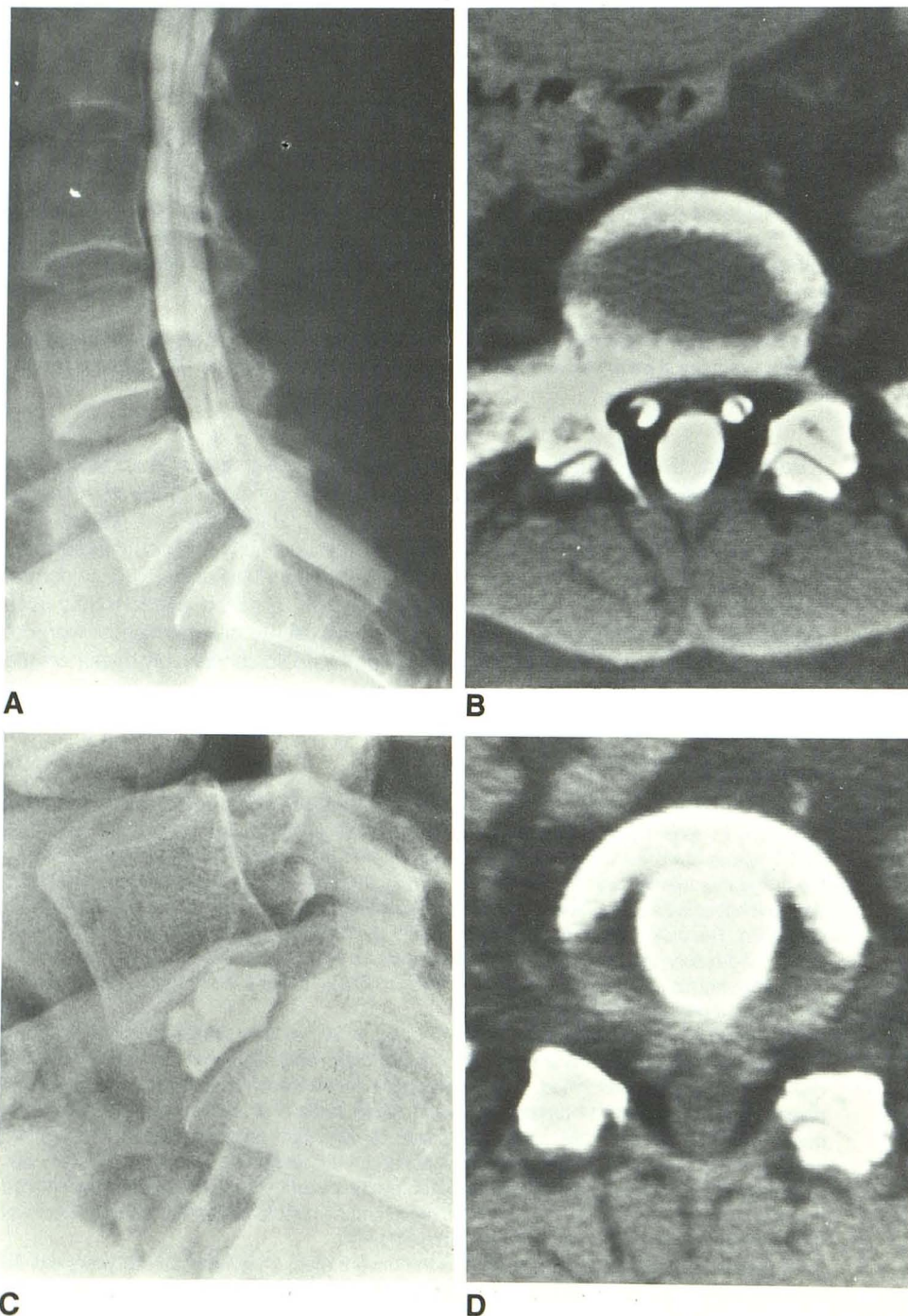


Fig. 1.—27-year-old woman with low back pain and right-sided radicular symptoms of about 3 months' duration.

A, Normal metrizamide myelogram (selected lateral view). Distal thecal sac appears somewhat truncated, which is a normal variant.

B, Postmetrizamide CT scan at L5-S1 is negative.

C, Lateral view of L5-S1 diskogram.

D, Normal postdiskography CT scan at L5-S1 level.

were negative. The patient subsequently had diskography at the L4-L5 level (Fig. 2C). The follow-up CT scan (Fig. 2D) was negative.

All patients experienced some form of discomfort during the procedure. However, only two stated that their pain was somewhat reproduced, in both instances at the L5-S1 level. In reviewing their charts, one patient had said that, although some of the pain was reproduced, it was of considerably less intense and of somewhat different quality. The second patient complained of a similar pain on needle manipulation and

placement but not during the injection process. In any event, these patients did not undergo surgery on the basis of these responses.

Fortunately, no patient experienced such side effects as allergic reactions, neurologic sequelae, bleeding, infection, CSF leak, or persisting procedure-related pain.

On the basis of the negative diskogram most patients were either referred for physical therapy or, if symptoms were chronic and unrelenting, encouraged to enroll in the accredited pain center at our institution for comprehensive, multidimen-

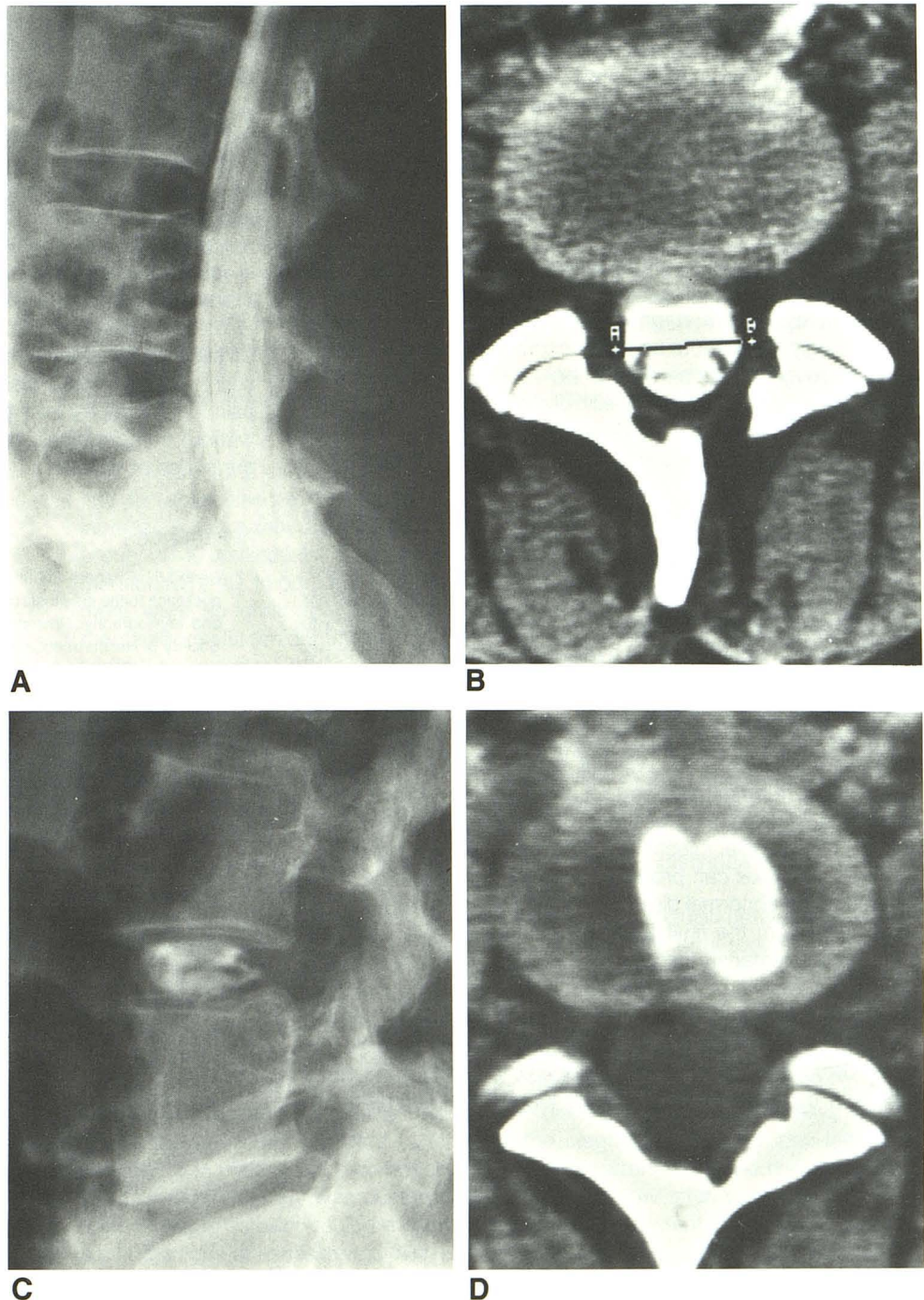


Fig. 2.—31-year-old woman with chronic low back pain.

A, Lateral view of metrizamide myelogram was interpreted as normal.

B, Normal postmetrizamide myelogram CT scan at L4-L5 level.

C, Normal diskogram at L4-L5 level.

D, Normal postdiskography CT-scan at L4-L5 level.

sional treatment. This basically consists of an initial screening evaluation by a team of workers, which includes a physiatrist, psychiatrist, psychologist, anesthesiologist, social worker, and physical and occupational therapists. If accepted, the patient is admitted into the hospital for a 3-week intensive period in which a team approach is undertaken not only to treat and control the pain, but also to help the individual learn how to live as well as possible with pain. After this, a 6-month outpatient program is encouraged.

Long-term follow-up was not possible in our 15 patients. According to the pain center, approximately one-third of patients experience some sustained improvement. Although most of our patients were cooperative, several have been lost to even short-term follow-up. Because of the negative studies, none of the 15 patients had surgery at our institution. Unfortunately, two patients who were lost to follow-up possibly had operative procedures at unknown hospitals. The circumstances surrounding these cases could not be verified, and we do not know the reasons for surgery.

Discussion

The causes of back pain are varied; perhaps most perplexing is the idiopathic variety in which no specific cause can be identified by current diagnostic approaches. It has become increasingly apparent to us that, despite new contrast agents and improved-resolution CT scanners, both orthopedists and neurosurgeons are occasionally performing diskography in the hopes of finding a source or cause for their patients' symptoms. This is true at least in our institution. The accuracy of CT (true positive) is 96% compared with 92–93% for myelography in two different studies [1, 2]. This accuracy is higher if CT is performed after myelography.

Unequivocal, suspicious, or technically suboptimal myelograms or CT scans are still the most common indications for diskography. We do not argue with this approach. When only oily contrast agents were available, additional diagnostic methods were limited, and diskography was able to provide an additional tool for diagnosis.

Much has been written about diskography since the early work of Lindblom [3, 4]. Without doubt, proper technique is essential to the final and correct interpretation. When evaluating a diskogram, the possibility of artifacts must be considered. For example, injection of contrast material outside the nucleus pulposus can produce an image that could be interpreted as an abnormal disk [5]. This led us to exclude two of our cases from the final analysis because of faulty injection of contrast material. Incorrect needle placement can create erroneous results or disk damage. Either can lead to unnecessary surgical intervention. For more reproducible results, the use of standardized pressure injections of the disk has been discussed [6]. However, iatrogenic irritation of the nerve fibers in the annulus and posterior longitudinal ligament can

reproduce pain that can be easily mistaken for disk herniation [7]. The two patients in our series in whom the original pain was minimally reproduced did not undergo surgery. The diskograms showed normal appearances of the nucleus pulposus and no leakage of contrast material under pressure, indicating the integrity of the annulus fibrosus.

We undertook our study because we were unable to find any references concerning the yield of diskography after normal postmyelogram CT scans. In the last few years, the role and reliability of diskography has received attention. With an extensive experience of 2000 diskographic studies, Shapiro [8] stated that lumbar diskography no longer has a role as a preoperative diagnostic procedure. This view was shared by Scullin [7]. Holt [9] evaluated lumbar diskography when 24-gauge needles were used for disk injection. He concluded that it was not a reliable diagnostic aid, with false-positive results of 37% in healthy young men. Bosacco [10] wrote: "Certainly the indiscriminate injection of dye into discs, which are clearly normal by other well accepted criteria such as metrizamide myelography and CT scanning should be avoided." On the other hand, Errico [11] believed that the major use of diskography is not to determine whether surgery is indicated, but rather to dictate which levels should be included in planned surgical fusion.

In conclusion, on the basis of our findings, we believe that an essentially negative myelogram with postmyelography CT scan should obviate diskography in the evaluation of back pain. Diskography is a painful, invasive procedure and not without complications. It added no additional information in our series of cases.

REFERENCES

1. Gado MH, Chandra-Sehur B, Patel J, Hodges FJ, Kapila A. An integrated approach to the diagnosis of lumbar disc disease by computed tomography and myelography. Presented at the annual meeting of the Radiological Society of North America, Chicago, November 1981
2. Haughton VM, Eldevik OP, Magnaes B, Amundsen P. A prospective comparison of computed tomography and myelography in the diagnosis of herniated lumbar disks. *Radiology* 1982;142:103–110
3. Lindblom K. Protrusions of disks and nerve compression in the lumbar region. *Acta Radiol (Stockh)* 1944;25:195–212
4. Lindblom K. Diagnostic puncture of intervertebral disks in sciatica. *Acta Orthop Scand* 1948;17:231–239
5. Quinell RC, Stockdale NE. An investigation of artifacts in lumbar diskography. *Br J Radiol* 1980;53(633):831–839.
6. Quinell RC, Stockdale NE. Pressure standardized lumbar diskography. *Br J Radiol* 1980;53:1031–1036
7. Scullin DR. Lumbar diskography (letter). *Radiology* 1987;162:284
8. Shapiro R. Current status of lumbar diskography (letter). *Radiology* 1986;159:15
9. Holt EP Jr. The question of lumbar diskography. *J Bone Joint Surg [Am]* 1968;50A:720–726
10. Basacco SJ. Lumbar diskography: redefining its role with intradiscal therapy. *Orthopaedics* 1986;9:399–401
11. Errico TJ. The role of diskography in the 1980s (letter). *Radiology* 1987;162:285–286