



## Get Clarity On Generics

Cost-Effective CT & MRI Contrast Agents

 FRESENIUS  
KABI

WATCH VIDEO

# AJNR

**The optic syrinx: cavernous degeneration of the optic nerve demonstrated by iopamidol optic neurography.**

J R Jenkins

*AJNR Am J Neuroradiol* 1987, 8 (2) 349-352

<http://www.ajnr.org/content/8/2/349>

This information is current as  
of August 28, 2025.

# The Optic Syrinx: Cavernous Degeneration of the Optic Nerve Demonstrated by Iopamidol Optic Neurography

John R. Jenkins<sup>1</sup>

Cavernous degeneration of the optic nerve has been described predominantly in association with long-standing glaucoma, although less frequently it has been reported in other, disparate disease processes. The only descriptions to date have been in pathologic specimens *in vitro*. This is the first report to describe syrinx formation of the optic nerves *in vivo* in two patients with nonglaucomatous conditions affecting the optic nerves.

Histologic descriptions of cavernous degeneration of the optic nerve date from Schnabel's first account of a patient with glaucoma in 1885 [1]. Since then, associations between glaucoma and this degenerative process are commonplace [2–4]. More recently, many other disease processes have been linked with cavernous degeneration of the optic nerve, as revealed by postmortem histology [5–8]. This article describes *in vivo* syrinx formation in the first cranial nerve.

## Materials and Methods

Two patients were studied in the manner described elsewhere [9] for optic neurography with the exception that a volume of 3–4 ml of 300 mg/ml I iopamidol was instilled into the lumbar subarachnoid space.

The dose was increased since the patients in this study were adults rather than children, as in the earlier report. The patients were scanned within 1 hr of contrast instillation. Axial and coronal high-resolution thin sections were obtained on a GE-9800 CT scanner. Neither patient encountered any adverse reaction either during or after the procedure.

## Results

### Case 1

The first patient was a 23-year-old woman who had infantile complete premature craniosynostosis, consequent long-standing increased intracranial pressure, and chronic papilledema. After an early, extensive craniectomy at the age of 6 years—in an attempt to open the sutures and relieve the elevated intracranial pressure (Fig. 1A)—the patient's vision continued to deteriorate, accelerating over that of the previous year. An axial CT through the orbits showed enlarged optic nerve sheaths, while an optic cisternogram showed extreme atrophy of the optic nerves and chiasm (Fig. 1B). The optic neurogram pointed out paradoxical prominence of the optic nerves within the dilated optic sheaths and relatively central neural accumulation of iopamidol contrast bilaterally in the retrobulbar region (Figs. 1C–1F).

### Case 2

The second patient was a 14-year-old girl with deteriorating vision, left worse

Received March 31, 1986; accepted after revision July 28, 1986.

<sup>1</sup> Department of Radiology, King Faisal Specialist Hospital and Research Centre, P.O. Box 3354, Riyadh 11211, Saudi Arabia. Address reprint requests to H. R. Jenkins.

**AJNR 8:349–352, March/April 1987**

0195–6108/87/0802–0349

© American Society of Neuroradiology



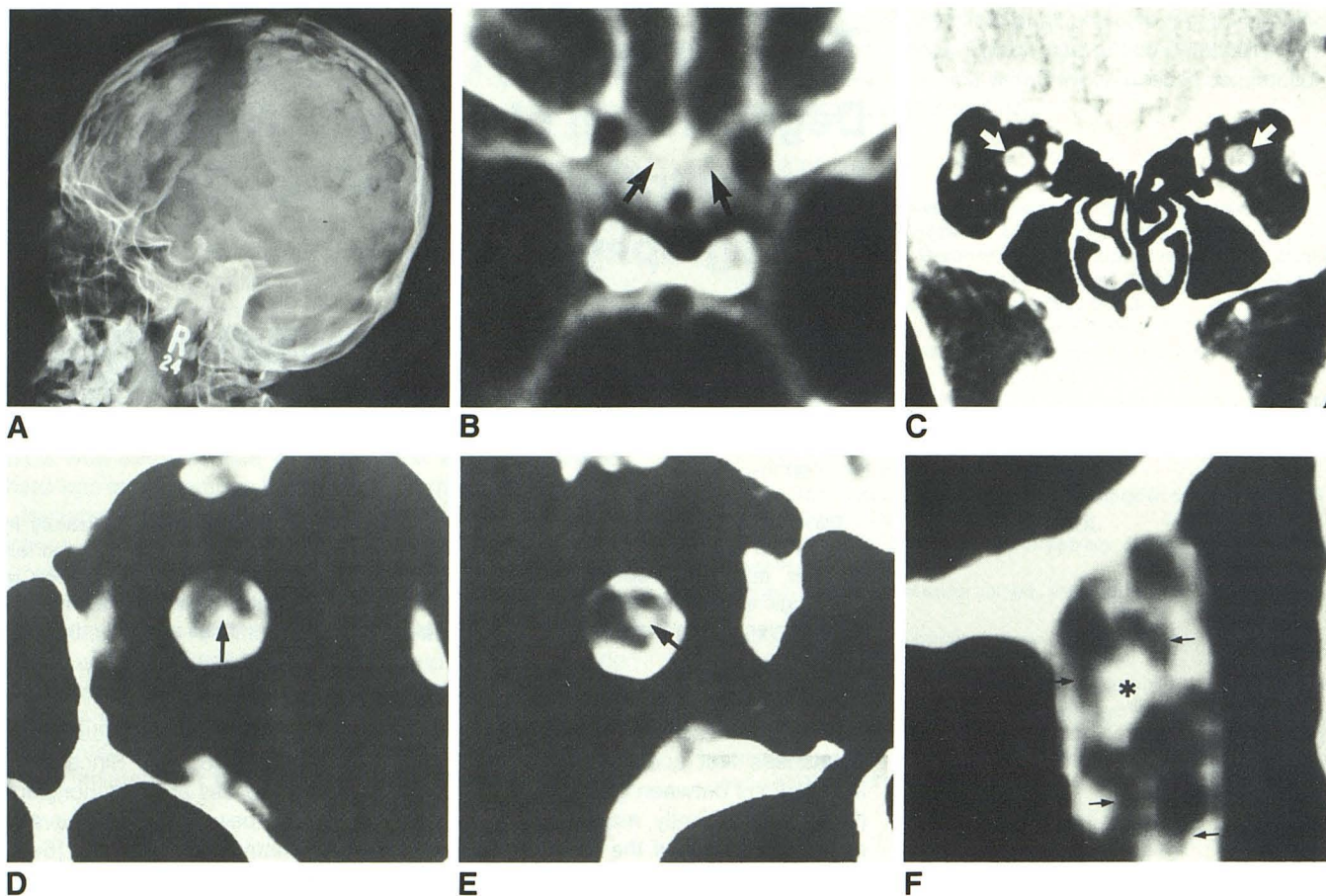


Fig. 1.—23-year-old woman with premature craniosynostosis after craniectomy.

A, Lateral radiograph of skull shows small, rounded shape and past extensive craniectomy/cranioplasty procedure.

B, Suprasellar cisternogram shows hardly visible "ghost" of optic nerves/chiasm in suprasellar cistern indicating extreme atrophy (arrows).

C, Coronal CT of both orbits shows intrathecal contrast within optic nerve sheaths (arrows).

D, Magnified coronal view with narrow-window filming technique centered over left orbit in retrobulbar region shows somewhat eccentric intraneural collection of iopamidol (arrow).

E, Similar coronal section centered over right orbit shows central optic nerve syrinx (arrow).

F, Magnified axial section of right optic nerve shows walls of optic syrinx (arrows) surrounding distally placed neural contrast collection (asterisk).

than right, and external features of neurofibromatosis. The IV contrast CT and optic cisternogram revealed a chiasm glioma and dilated, tortuous intraorbital optic nerve/sheath complexes (Figs. 2A and 2B). The optic neurogram showed moderate enlargement of the left optic nerve, which contained a multiloculated, eccentric collection of iopamidol distally (Figs. 2C and 2D).

## Discussion

Syrinx involving the spinal cord is a fascinating, well described, and readily diagnosable lesion [10–12]. Improved diagnostic techniques show cystic change involving the spinal cord more clearly and more precisely, both in benign and neoplastic disease processes [13, 14]. Pathologic change in the cerebrum leading to cyst formation is also well documented [15]. Thus, it should not be surprising to see cystic degeneration of neural tissue involving extensions of the axial

CNS [16]. In fact, so-called "cavernous degeneration" of the optic nerve has been repeatedly and definitively reported, as noted in the introduction. However, the imaging of this entity in vivo is problematic, owing to limitations of contrast and spatial resolution.

Of further interest is the visualization of syrinx cavities in the optic nerves after just a short delay. Cavities in the spinal cord are visible only after a postmyelographic period of 3–24 hr [11]. In the two reported cases, however, the syrinx cavities became visible within 1 hr after the introduction of intrathecal contrast into the craniospinal subarachnoid space. This might have been caused by any of several mechanisms: (1) free communication of the cystic cavities with the subarachnoid space, (2) extreme thinness of the cavity wall allowing rapid entry of contrast material into the cystic spaces, and (3) a difference in the basic physiologic behavior of the spinal cord and the cranial nerves in terms of their interaction with CSF [17, 18].

It seems clear that in the first case of severe long-standing



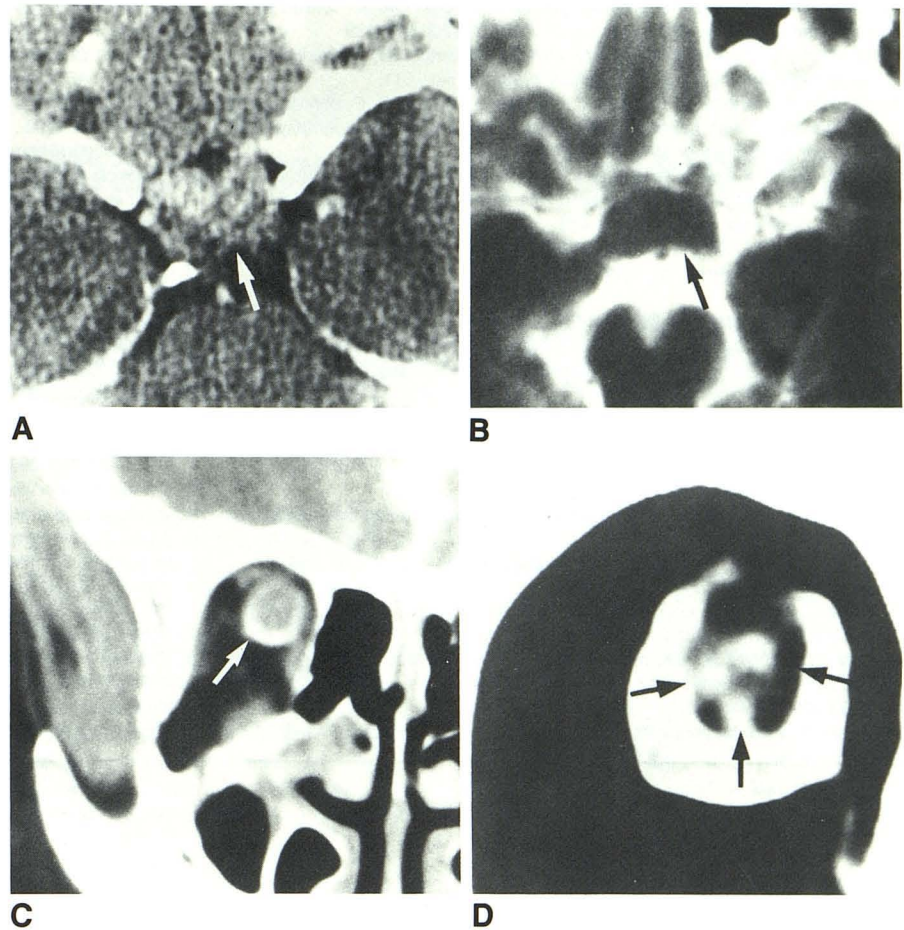
Fig. 2.—14-year-old girl with neurofibromatosis and optic chiasm glioma.

A, Intravenous enhanced CT shows poorly enhancing intra/suprasellar mass (arrow).

B, Optic cisternogram precisely depicts the ovoid confines of chiasm neoplasm (arrow).

C, Coronal CT of right orbit shows enlarged distal optic nerve surrounded by intrathecal iopamidol (arrow).

D, Same coronal section as in C with magnified narrow-window filming technique shows enlarged right optic nerve containing three separate eccentric collections of iopamidol (arrow). These collections are seen faintly in C.



papilledema, the underlying pathology is one of prolonged ischemia to the optic disk and optic nerve leading to cavity formation [19–22]. However, the syrinx formation in the second case of optic chiasm glioma is open to question. Certainly optic disk hypoxia is also known to occur in association with mass lesions intracranially and intraorbitally, which might conceivably result in cavitation [8, 23–26]. On the other hand, cyst formation in astrocytomas of the chiasm, brain, and spinal cord is well known [13, 14, 27–29]. Possibly, then, this second case represents cystic degeneration or orbital extension of the chiasm glioma. However, because the original tumor appears as a solid lesion, the orbital manifestation becomes somewhat more difficult to explain on this basis. Therefore, this second case likely represents a complex degenerative phenomenon. But since no biopsy was taken of the intraorbital optic nerve, this is only speculation.

Regardless, it seems clear that there is great potential for diagnosing syrinx formation in cranial nerves (namely, syringoneuria) in varied disease processes [25, 30–32]. The clinical implication is twofold: (1) the optic nerves in many pathologic conditions may be much more severely involved than was previously thought [26], and (2) these cystic degenerations may be active processes in and of themselves and produce further, progressive damage as they exert pressure and dissect along and through the optic nerve [33, 34].

#### ACKNOWLEDGMENTS

I thank Mrs. A. Radford for manuscript preparation, Mrs. C. Jenkins for manuscript research, and K.F.S.H. Radiology and Photo-Graphics Departments for technical assistance with the illustrations.

#### REFERENCES

1. Wolff E. Schnabel's cavernous atrophy. *Trans Ophthalmol Soc UK* 1947;68:133–140
2. Quigley HA, Addicks EM, Green WR. Optic nerve damage in human glaucoma. III. Quantitative correlation of nerve fiber loss and visual field defect in glaucoma, ischemic neuropathy, papilledema, and toxic neuropathy. *Arch Ophthalmol* 1982;100:135–146
3. Lampert PW, Vogel MH, Zimmerman LE. Pathology of the optic nerve in experimental acute glaucoma. *Invest Ophthalmol Vis Sci* 1968;7(2):199–213
4. Zimmerman LE, de Venecia G, Hamasaki DI. Pathology of the optic nerve in experimental acute glaucoma. *Invest Ophthalmol Vis Sci* 1967;6(2):109–125
5. Brownstein S, Font RL, Zimmerman LE, Murphy SB. Nonglaucomatous cavernous degeneration of the optic nerve. Report of two cases. *Arch Ophthalmol* 1980;98:354–358
6. Giarelli L, Melato M, Campos E. 14 cases of cavernous degeneration of the optic nerve. *Ophthalmologica* 1977;174:316–321
7. Hayreh SS. Pathogenesis of cupping of the optic disc. *Br J Ophthalmol* 1974;58:863–876
8. Trobe JD, Glaser JS, Cassady J, Herschler J, Anderson DR. Nonglaucomatous excavation of the optic disc. *Arch Ophthalmol* 1980;98:1046–1050

9. Jinkins JR. The optic neurogram: evaluation of CSF "block" caused by compressive lesions at the optic canal. *AJNR* 1987;8:135-139
10. Batnitzky S, Price HI, Gaughan MJ, Hall PV, Rosenthal SJ. The radiology of syringohydromyelia. *RadioGraphics* 1983;3(4):585-611
11. Bonafe A, Manelfe C, Espagno J, Guiraud B, Rascol A. Evaluation of syringomyelia with metrizamide computed tomographic myelography. *J Comput Assist Tomogr* 1980;4(6):797-802
12. Quencer RM, Green BA, Eismont FJ. Posttraumatic spinal cord cysts: clinical features and characterization with metrizamide computed tomography. *Radiology* 1983;146:415-423
13. Kan S, Fox AJ, Viñuela F, Barnett HJM, Peerless SJ. Delayed CT metrizamide enhancement of syringomyelia secondary to tumor. *AJNR* 1983;4:73-78
14. Pulicino P, Kendall BE. Computed tomography of "cystic" intramedullary lesions. *Neuroradiology* 1982;23:117-121
15. Raybaud C. Destructive lesions of the brain. *Neuroradiology* 1983;25:265-291
16. Kingsley DPE, Thornton A, Furneaux C, King TT. Transmural passage of subarachnoid metrizamide into a cystic acoustic schwannoma of the cerebellopontine angle: a diagnostic dilemma. *Neuroradiology* 1984;26:319-321
17. Sage MR. Kinetics of water-soluble contrast media in the central nervous system. *AJNR* 1983;4:897-906
18. Sage MR, Wilcox J. Brain parenchyma penetration by intrathecal nonionic iopamidol. *AJNR* 1983;4:1181-1183
19. Green GJ, Lessell S, Loewenstein JI. Ischemic optic neuropathy in chronic papilledema. *Arch Ophthalmol* 1980;98:502-504
20. Hayreh SS. Optic disc edema in raised intracranial pressure. VI. Associated visual disturbances and their pathogenesis. *Arch Ophthalmol* 1977;95:1566-1579
21. Rush JA. Pseudotumor cerebri. Clinical profile and visual outcome in 63 patients. *Mayo Clin Proc* 1980;55:541-546
22. Whittle IR, Johnston IH, Besser M. Intracranial pressure changes in cranio-stenosis. *Surg Neurol* 1984;21:367-372
23. Brovkina AF, Kirillova LI. Blood circulation in the optic nerve disc in patients with orbit tumours. *Vestn Oftalmol* 1980;5:53-56
24. Skarf B, Davis RL, Birsner HA, Hoyt WF. Intracranial optic nerve infarction from subdural hematoma. *Arch Neurol* 1984;41:58-60
25. Schenck JF, Hart HR Jr, Foster TH, et al. Improved MR imaging of the orbit at 1.5 T with surface coils. *AJNR* 1985;6:193-196
26. Quigley HA. Glaucoma's optic nerve damage: changing clinical perspectives. *Ann Ophthalmol* 1982;14(7):611-612
27. Barbaro NM, Rosenblum ML, Maitland CG, Hoyt WF, Davis RL. Malignant optic glioma presenting radiologically as a "cystic" suprasellar mass: Case report and review of the literature. *Neurosurgery* 1982;11(6):787-789
28. Loftus CM, Copeland BR, Carmel PW. Cystic supratentorial gliomas: natural history and evaluation of modes of surgical therapy. *Neurosurgery* 1985;17(1):19-24
29. Messina AV, Potts DG, Rottenberg D, Patterson RH. Computed tomography: demonstration of contrast medium with cystic tumors. *Radiology* 1976;120:345-347
30. Daniels DL, Herfkens R, Gager WE, et al. Magnetic resonance imaging of the optic nerves and chiasm. *Radiology* 1984;152:79-83
31. Edwards JH, Hyman RA, Vacirca SJ, et al. 0.6 T magnetic resonance imaging of the orbit. *AJNR* 1985;6:253-258
32. Kjos BO, Brant-Zawadzki M, Kucharczyk W, Kelly WM, Norman D, Newton TH. Cystic intracranial lesions: magnetic resonance imaging. *Radiology* 1985;155:363-369
33. Conway LW. Hydrodynamic studies in syringomyelia. *J Neurosurg* 1967;27:501-514
34. Watson N. Ascending cystic degeneration of the cord after spinal cord injury. *Paraplegia* 1981;19:89-95