



Get Clarity On Generics

Cost-Effective CT & MRI Contrast Agents



FRESENIUS
KABI

WATCH VIDEO

AJNR

CT of neonatal herpes encephalitis.

T E Herman, R H Cleveland, D C Kushner and J M Taveras

AJNR Am J Neuroradiol 1985, 6 (5) 773-775

<http://www.ajnr.org/content/6/5/773>

This information is current as
of August 16, 2025.

CT of Neonatal Herpes Encephalitis

Thomas E. Herman¹
Robert H. Cleveland¹
David C. Kushner¹
Juan M. Taveras²

Seven neonates with proven herpes (HSV type 2) encephalitis exhibited a characteristic sequence of findings on cranial computed tomography (CT). The initial CT abnormalities in all infants were fingerlike areas of cortical increased attenuation noted on unenhanced scans obtained 2–30 days after presentation. These usually were accentuated by increased white-matter lucency. Subsequently (more than 30 days after presentation), extensive cerebral destruction, multicystic encephalomalacia, and calcification were seen on follow-up CT scans obtained in five infants.

Encephalitis is the most serious manifestation of neonatal herpes simplex infection because of its high mortality and morbidity. This disease, usually due to *Herpesvirus hominis* (herpes simplex virus [HSV]) type 2 (genital) [1, 2], is most often heralded by the onset of seizures during the second to fourth weeks of life. In the end stage this disease may be characterized by cystic encephalomalacia and cortical calcifications both pathologically and radiographically [1, 3, 4]. Unlike the HSV type 1 encephalitis in the older child and adult, which has been well described [5], the radiographic course of the neonatal disease has been less well documented [4]. We report seven infants who have had sequential CT scans demonstrating relatively characteristic findings.

Materials and Methods

A retrospective survey was done of infants seen at Massachusetts General Hospital from 1977 to 1982 with a discharge diagnosis of neonatal herpes encephalitis. All seven were term infants (average gestation, 40 weeks) and were discharged from their home nursery in good condition. In none was a maternal history of genital herpes available at the time of admission. All presented with tonic-clonic seizure. The age at onset of this seizure, which was considered the age at presentation, varied from 12 to 23 days. Three of the seven infants developed cutaneous herpetic vesicles. The diagnosis was confirmed in one child by brain biopsy, in three by nasopharyngeal cultures positive for HSV type 2, in two by rising HSV serum titers, and in one by cytopathology of cutaneous vesicles. Each infant had at least two computed tomographic (CT) scans during the initial month after presentation.

Results

Initial CT scans (performed in only two infants) within the first 2 days after presentation were normal. Subsequently, CT scans became abnormal in all infants during an interval of 2–30 days (average, 20 days) after presentation. In all seven infants, the initial CT abnormalities were fingerlike areas of increased density in the cerebral cortex, probably gyral in location (figs. 1–3), and decreased density in the white matter.

CT scans obtained more than 30 days after presentation in five of the seven cases demonstrated extensive cerebral destruction with multiple low-density areas

Received April 17, 1984; accepted after revision March 16, 1985.

¹ Department of Radiology, Section of Pediatric Radiology, Massachusetts General Hospital, Boston, MA 02114. Address reprint requests to T. E. Herman.

² Department of Radiology, Section of Neuroradiology, Massachusetts General Hospital, Boston, MA 02114.

AJNR 6:773–775, September/October 1985

0195–6108/85/0605–0773

© American Roentgen Ray Society

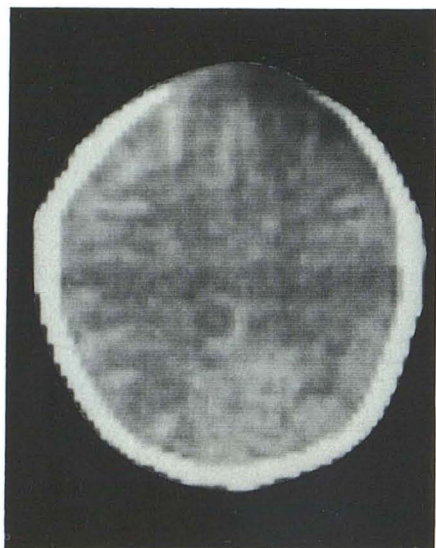


Fig. 1.—31-day-old infant. Unenhanced CT scan at 14 days after presentation. Linear areas of increased density in cortical region, somewhat more obvious in right hemisphere than on left.

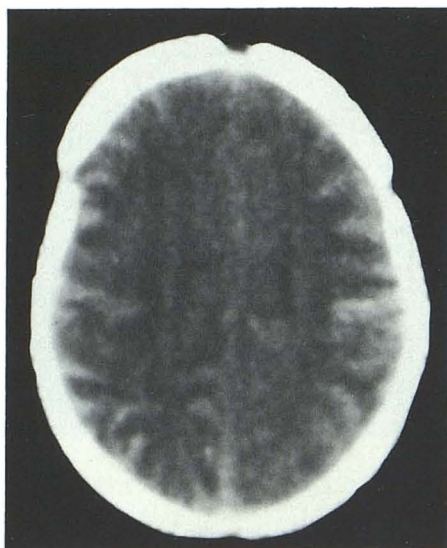


Fig. 2.—27-day-old infant. Unenhanced CT scans at 12 days after presentation. Intense cortical gyral density.

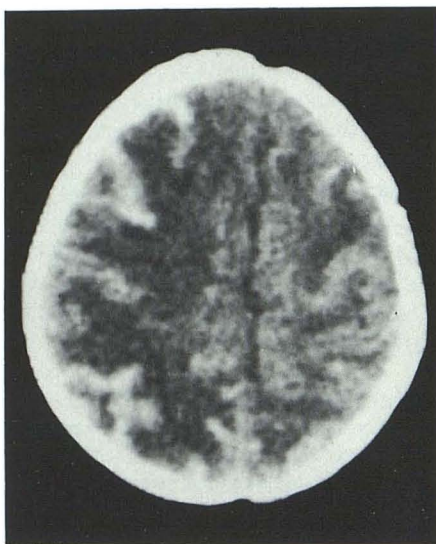
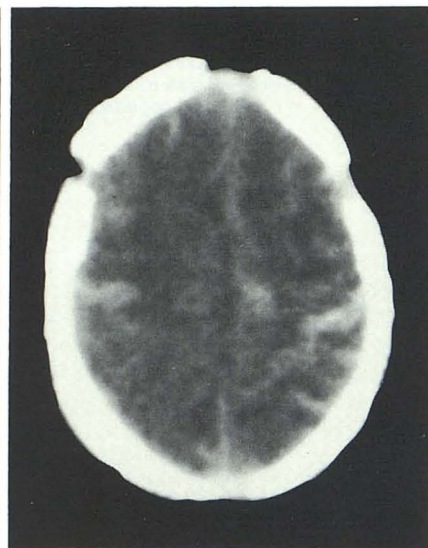


Fig. 3.—35-day-old infant. Unenhanced CT scans at 13 days after presentation. Very intense gyral fingerlike densities, mainly on right.

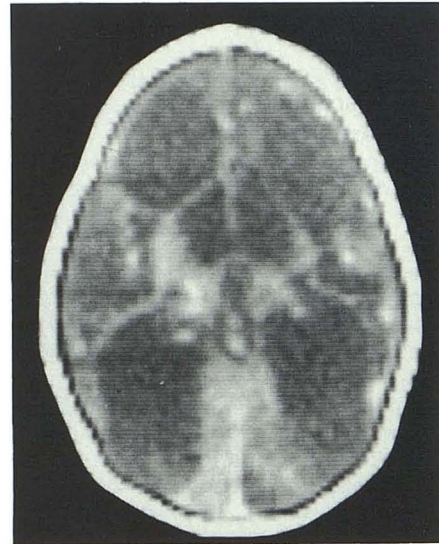
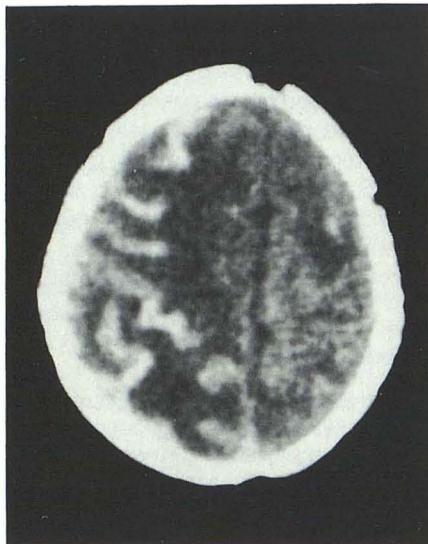


Fig. 4.—Unenhanced CT scan at 3 months after presentation. Widespread low-density cystic changes in cerebral hemispheres.

and calcifications (figs. 4 and 5). In the other two infants no follow-up examinations were available.

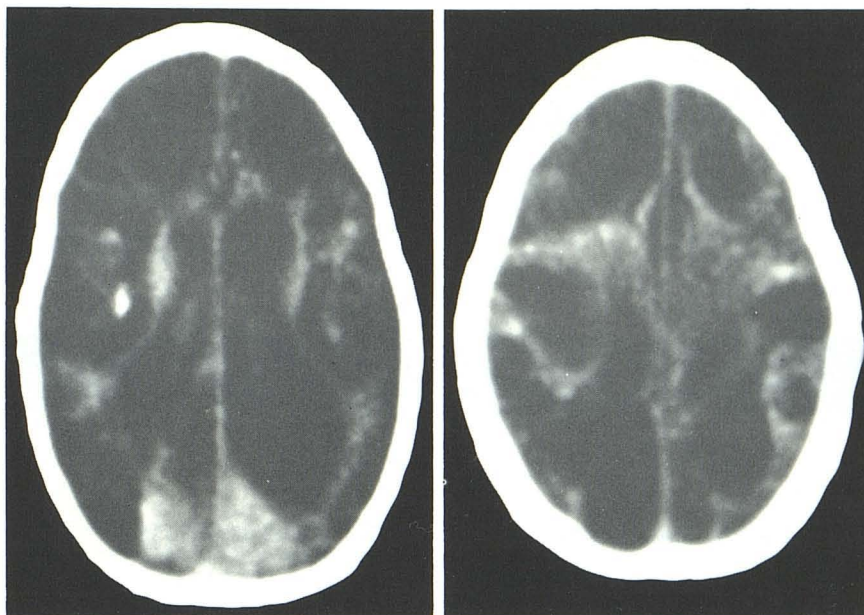
Discussion

Neonatal HSV type 2 infection is most often acquired at delivery as the child passes through an infected birth canal [1]. Four types of presentation of the neonatal infection have been observed [2]: (1) disseminated infection with hepatitis and pneumonitis but without central nervous system (CNS)

involvement, (2) disseminated infection with CNS involvement, (3) localized CNS infection without other manifestations, and (4) localized mucocutaneous infection without CNS or other organ involvement. The mortality of untreated patients with CNS involvement is 30%–80% [6]. The morbidity is high, and many survivors have severe CNS damage [6].

Preferential involvement of the temporal lobe and mass effects were not observed in our series of neonatal herpes encephalitis [5]; rather, a more diffuse involvement was seen. Characteristic initial CT abnormalities consisted of fingerlike

Fig. 5.—Unenhanced CT scans at 1 year after presentation. Extensive low-density lesions and calcification.



areas of cortical density, demonstrated in all the cases; there was also some decrease in white-matter density diffusely as compared with normal. The low attenuation values are due in part to edema and in part to brain tissue destruction, which occurs rapidly in HSV type 2 encephalitis. The pattern of cortical gyral densities has been reported previously in cases of neonatal HSV encephalitis [4, 7]. Biopsy material in one of our patients suggested that the areas of increased cortical density may represent hemorrhage. Follow-up CT scans obtained in five of the seven infants more than 30 days after presentation demonstrated diffuse low-density cystic areas throughout the cerebral hemispheres with scattered calcifications. Similar low-density areas and calcifications were seen in two previously reported cases of neonatal HSV type 2 infection [7]. This CT pattern appears to correspond to multicystic encephalomalacia and has been seen in other neonatal abnormalities, including toxoplasmosis and hypoxic encephalopathy [8, 9].

As treatment becomes available, early diagnosis becomes more important; CT scanning is not really adequate for early diagnosis. The two cases scanned at 2 days yielded negative results. Perhaps magnetic resonance (MR) imaging will demonstrate changes earlier; it has been suggested that MR imaging is more sensitive to CNS inflammatory disease [10] and that the MR imaging appearance of nonneonatal (type 1) HSV encephalitis demonstrates more extensive changes than simultaneous CT [11].

REFERENCES

1. Smith JB, Groover RV, Klass DW, Houser OW. Multicystic cerebral degeneration in neonatal herpes simplex virus encephalitis. *Am J Dis Child* **1977**;131:568-572
2. Whitley RJ, Nahmias AJ, Vistine AM, Fleming CL, Alford CA. The natural history of herpes simplex virus infection of mother and newborn. *Pediatrics* **1980**;66:489-494
3. Chutorian AM, Michener RC, Detendini R, Hilal SK, Gamboa ET. Neonatal polycystic encephalomalacia: four new cases and review of the literature. *J Neurol Neurosurg Psychiatry* **1979**;42:154-160
4. Dubois PJ, Heinz ER, Wessel HB, Zaias BW. Multicystic encephalomalacia of infancy: computed tomographic findings in two cases with associated intracerebral calcification. *J Comput Assist Tomogr* **1979**;3:97-102
5. Davis JM, Davis KR, Kleinman GM, Kirchner HS, Taveras JM. Computed tomography of herpes simplex encephalitis with clinicopathological correlation. *Radiology* **1978**;129:409-417
6. Whitley RM, Nahmias AJ, Seng-Jaws S, Galasso GG, Fleming CL. Vidarabine therapy of neonatal herpes simplex virus infection. *Pediatrics* **1980**;66:495-501
7. Sage R, Dubois J, Oakes S, Rothman S, Heinz E, Drayer B. Rapid development of cerebral atrophy due to perinatal herpes simplex encephalitis. *J Comput Assist Tomogr* **1981**;5:763-766
8. Aicardi J, Goutieres F, Hodebourg de Verbois A. Multicystic encephalomalacia of infants and its relation to abnormal gestation and hydranencephaly. *J Neurol Sci* **1972**;15:357-373
9. Naidich TP, Chakera TMH. Multicystic encephalomalacia: CT appearance and pathological correlation. *J Comput Assist Tomogr* **1984**;8:631-636
10. Gooding CA, Brasch RC, Lallemand DP, Wesbey GE, Brant-Zawadzki MN. Nuclear magnetic resonance imaging of the brain in children. *J Pediatr* **1984**;104:509-515
11. Bailes DP, Young IR, Thomas DJ, Straughan K, Bydder GM, Steiner RE. NMR imaging of the brain using spin-echo sequences. *Clin Radiol* **1982**;33:395-414