



Get Clarity On Generics

Cost-Effective CT & MRI Contrast Agents

 FRESENIUS
KABI

[WATCH VIDEO](#)

AJNR

Assessment of craniocervical junction and atlantoaxial relation using metrizamide-enhanced CT in flexion and extension.

D Osborne, P Triolo, P Dubois, B Drayer and E Heinz

AJNR Am J Neuroradiol 1983, 4 (3) 843-845

<http://www.ajnr.org/content/4/3/843>

This information is current as
of August 15, 2025.

Assessment of Craniocervical Junction and Atlantoaxial Relation Using Metrizamide-Enhanced CT in Flexion and Extension

D. Osborne,¹ P. Triolo, P. Dubois, B. Drayer, and E. Heinz

Metrizamide-enhanced computed tomographic (CT) myelography has made it easier to define the relation of the spinal cord to the vertebral canal. A flexion-extension metrizamide-enhanced CT technique has been developed to study the craniocervical junction that refines evaluation of the relation between the spinal cord and the foramen magnum, atlas, and axis. This technique was used to study 15 adults who had had a structurally normal examination of the upper cervical cord and foramen magnum. The average movement of the upper cervical cord was shown to be 1 mm. The advantages of the flexion-extension metrizamide-enhanced CT examination were evident in 10 other patients who had a variety of craniocervical junction pathologies.

Metrizamide-enhanced computed tomographic (CT) myelography has increased our ability to define the relation between the spinal cord and vertebral canal. We present a simple flexion-extension technique to evaluate the craniocervical junction that refines analysis of the relation between the spinal cord, foramen magnum, atlas, and axis.

The anteroposterior (AP) flexion-extension range of the occipitatlantal junction is 13° and the atlantoaxial junction 10° [1, 2]. This relatively limited range of movement means that the vertebral canal can be evaluated in flexion and extension in its true transverse axis with the gantry tilt available on most CT scanners. In our study we aligned the gantry perpendicular to the vertical axis of the dens and body of the axis on flexion and extension.

In 15 adult patients who showed no evidence of vertebral canal pathology, flexion and extension metrizamide-enhanced CT studies were performed to determine the normal relation between the spinal cord and upper cervical vertebral canal. Ten patients with craniocervical junction pathology were also studied to evaluate the effect of flexion and extension on the dynamics of their pathology.

Subjects and Methods

Normal studies of adult patients were obtained after a normal cisternogram or cervical myelogram. The patients were placed supine on the CT scanning table with the head in maximum comfortable extension. A ScoutView was obtained and the gantry tilted to be perpendicular to the vertical axis of the body and dens of C2 (fig. 1). Back-to-back serial 4- or 5-mm-thick slices were obtained from the lower border of C2 to the margins of the foramen magnum. The study was repeated after the patient's head was placed in

maximum comfortable flexion. After setting an appropriate window [3] measurements were made in both examinations from the anterior margin of the spinal cord to: the posterior surface of the body of C2; the posterior surface of the dens; and the anterior margin of the foramen magnum (fig. 2). A measurement was also made between the posterior surface of the anterior arch of the atlas and the anterior surface of the dens. The differences between the measurements on flexion and extension studies were noted. Ten patients with craniocervical junction abnormalities were similarly studied. These patients' disease processes included spontaneous atlantoaxial subluxation, rheumatoid arthritis with atlantoaxial subluxation, basilar invagination, and the Chiari malformation.

Results

In the normal group, the spinal cord was shown to move 1 mm (range, 0–2.5 mm) between flexion and extension in the supine position. There was no significant difference between the measure-

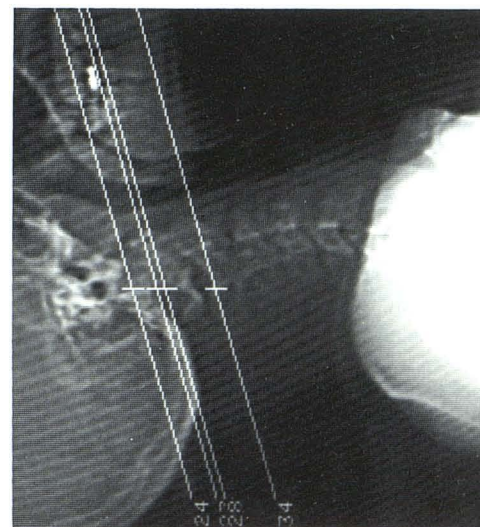


Fig. 1.—ScoutView in comfortable hyperextension shows plane of CT slices perpendicular to vertical axis of C2.

¹All authors: Department of Radiology, Duke University Medical Center, Durham, NC 27710. Address reprint requests to D. Osborne.

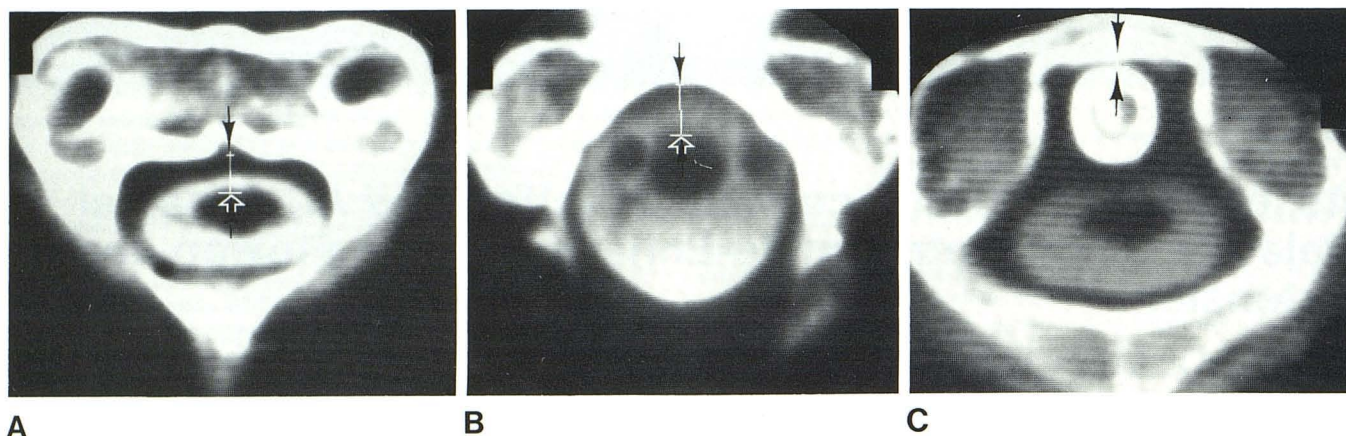


Fig. 2.—Measurements were made on flexion and extension studies between anterior margin of spinal cord and: **A**, Posterior surface of body of C2 (arrows) and, **B**, Anterior margin foramen magnum (arrows). **C**, Measure-

ments were also made between posterior surface of anterior arch of atlas and anterior surface of dens (arrows).

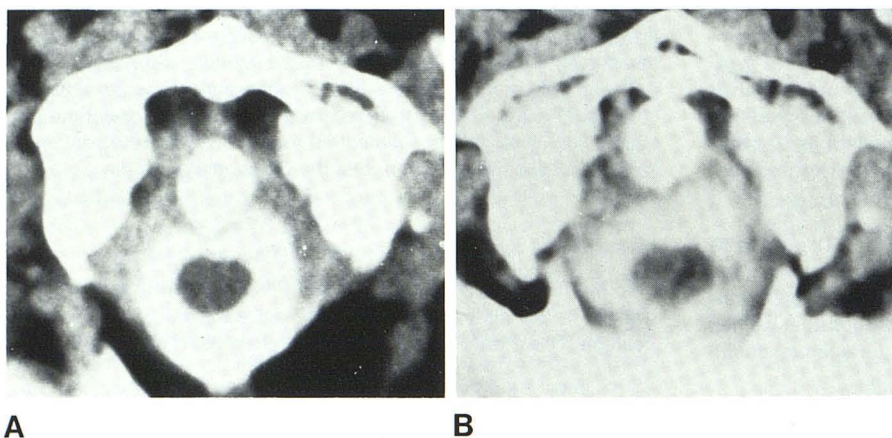


Fig. 3.—Flexion (**A**) and extension (**B**) metrizamide-enhanced CT examinations of craniocervical junction in 54-year-old rheumatoid arthritic patient presenting with myelopathy. Striking displacement of dens on flexion, correction in extension, and change in position of cord in dural sac.

ments of movement taken at the level of the posterior surface of C2, the posterior surface of the dens, or the anterior margin of the foramen magnum. The distance between the anterior surface of the dens and the posterior surface of the atlas altered by 1–2 mm, increasing in flexion.

In the abnormal group, any compromise of the vertebral canal was exaggerated on flexion, especially in those patients with a subluxation. The movements of the spinal cord were, however, not significantly increased over the normal range. In those patients with a Chiari I malformation and those with basilar invagination no movement of the spinal cord was observed.

The advantages of the technique in displaying the dynamics of the abnormal craniocervical junction are demonstrated in figures 3–5.

Discussion

Jirout [4] studied spinal cord movement using air myelography. He calculated an average sagittal plane spinal cord movement of 3.1 mm at C1 and 2.4 mm at C2 in patients whose position had been changed from prone to supine. At these levels we were able

to detect in our normal patients an average movement of the spinal cord in the vertebral canal of 1 mm after supine flexion and extension. Similarly, one normal adult examined with CT metrizamide myelography in both prone and supine extended positions had a 1 mm movement of the cord demonstrated at C1 and C2. Jirout's studies imply a greater range of cord movement at the craniocervical junction, but the 15 normal patients we examined had no more than a 2.5 mm movement of the cord demonstrated. Extreme hyperflexion and extension of the whole cervical spine may increase the range of movement of the cord at the craniocervical junction, but it was not possible to study our patients in these extreme positions. In the normal supine patient the high cervical spinal cord was noted to lie in a slightly anterior position in the vertebral canal on both flexion and extension. It is probably retained in this position by the anterolaterally attached uppermost dentate ligaments [5].

The real value of the flexion-extension technique became obvious when we examined our abnormal population. It refined the analysis of the craniocervical junction and allowed the most appropriate position for fixation to be determined when this operative option was being considered. Although caution should be exercised when using metrizamide, no complications are likely if its volume and concentration are low (5 ml; 170 mg I/dl).

Fig. 4.—Flexion (A) and extension (B) metrizamide-enhanced CT examinations of craniocervical junction in 67-year-old woman with spontaneously subluxing atlantoaxial joint. Marked displacement of dens on flexion and exaggerated distortion of dural sac.

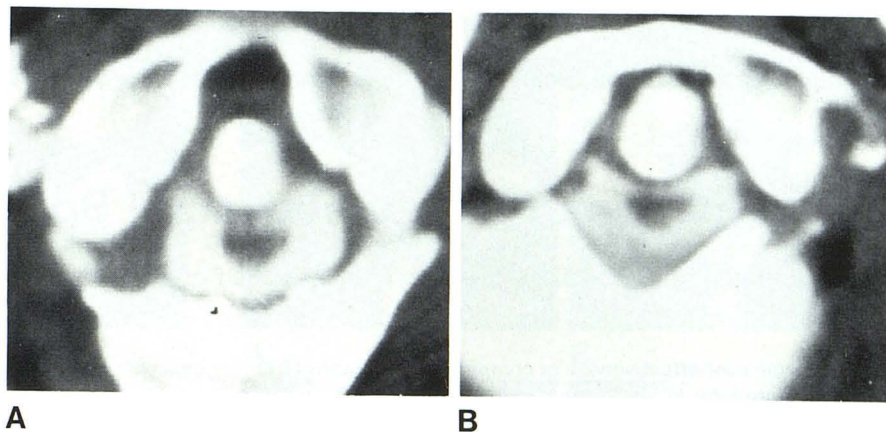
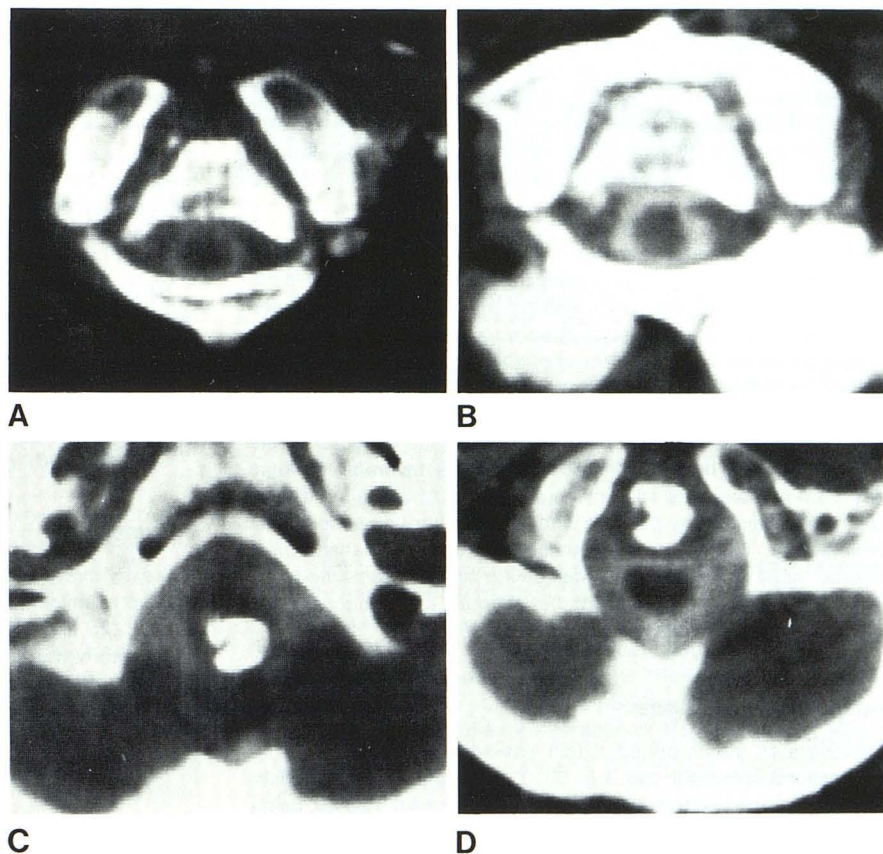


Fig. 5.—Flexion (A) and extension (B) metrizamide-enhanced CT examination of craniocervical junction at level of C2 in 50-year-old patient with basilar invagination and atlantoaxial subluxation. Flexion (C) and extension (D) studies at level of foramen magnum demonstrate basilar invagination and marked encroachment of dens into posterior fossa on flexion.



REFERENCES

1. Werne S. Studies in spontaneous atlas dislocation. *Acta Orthop Scand [Suppl]* 1957;23:82-83
2. White AA, Panjabi MM. *Clinical biomechanics of the spine*. Philadelphia: Lippincott, 1978:61-70
3. Ullrich CG, Binet EF, Sanecti G, Kieffer SA. Quantitative assessment of lumbar spinal canal by computed tomography. *Radiology* 1980;134:137-143
4. Jirout J. *Pneumomyelography*. Springfield, IL: Thomas, 1969:92-112
5. Breig A. *Biomechanics of the central nervous system*. Uppsala, Sweden: Almqvist & Wiksells, 1960:48-95