



Get Clarity On Generics

Cost-Effective CT & MRI Contrast Agents



FRESENIUS
KABI

WATCH VIDEO

AJNR

Unusual computed tomographic presentation of cerebral toxoplasmosis.

S Mazer, J C Araujo, R C Ribeiro and G Kasting

AJNR Am J Neuroradiol 1983, 4 (3) 458-460

<http://www.ajnr.org/content/4/3/458>

This information is current as
of August 14, 2025.

Unusual Computed Tomographic Presentation of Cerebral Toxoplasmosis

Sergio Mazer,¹ João Candido Araujo,² Raul Correia Ribeiro,³ and Gilda Kasting⁴

The computed tomographic appearance of three cases of cerebral toxoplasmosis is described. Two of the patients were children with Hodgkin disease and the third was an adult with systemic lupus erythematosus. All patients were severely immunosuppressed. Computed tomography showed single or multiple hypodense rounded areas with peripheral annular contrast enhancement, suggesting pyogenic cerebral abscesses. Pathologic correlation is presented. The importance of diagnosis and early treatment is emphasized.

Toxoplasmosis is a protozoan infection produced by *Toxoplasma gondii*, which may be either congenital or acquired. Acute infection of the central nervous system has been reported with increasing frequency in immunosuppressed patients [1-4], particularly in those with neoplasms of the hematopoietic system [5, 6]. Several types of lesions of the central nervous system have been described under these circumstances, including "mass lesions" demonstrated by computed tomography (CT) [7-9]. This paper reports two cases with similar CT findings diagnosed postmortem and a third case successfully treated.

Case Reports

Case 1

A 9-year-old boy with a hard mass in his right axilla and several small cervical and inguinal lymph nodes had a diagnosis of Hodgkin disease established by biopsy of one of the cervical lesions. Treatment with mechlorethamine, Oncovin, procarbazine, and prednisone (MOPP) was started. Nine months later he returned with headache, double vision, vomiting, and drowsiness. Neurologic examination showed papilledema, right VI nerve palsy, and left central facial weakness. Routine laboratory tests were unremarkable.

CT showed two round lesions with ringlike contrast enhancement surrounded by edema, one in each cerebral hemisphere (figs. 1A and 1B). Ten days later another CT study revealed enlargement of both lesions and a small left thalamic nodule. IgM and IgG immunofluorescence antibody tests for toxoplasmosis were negative. Biopsy of the right parietal lesion showed nonspecific inflammatory tissue. Neurologic status progressively deteriorated, and the patient died.

At autopsy, a right parietal hematoma was found at the site of biopsy. Posterior to the hematoma a nodular gray lesion was identified. Microscopic examination revealed a mononuclear infiltrate and pseudocysts containing *Toxoplasma gondii* trophozoites (fig. 1C). Another similar lesion was found in the left occipital lobe, in addition to multiple punctate similar lesions elsewhere in the brain.

Case 2

A 22-year-old man was admitted with progressive left hemiparesis, headache, and somnolence. A diagnosis of systemic lupus erythematosus had been made 4 years earlier, and he had been treated with prednisone, cyclophosphamide, and mercaptopurine. A diagnosis of pulmonary tuberculosis 2 years before admission led to successful treatment with streptomycin, rifamycin, and Myambutol over a period of 1 year. Physical examination was normal except for left hemiparesis and hyperreflexia. Laboratory tests were normal. Lupus erythematosus cells were not found, and cerebrospinal fluid examination revealed only abnormally elevated protein levels.

CT (fig. 2A) showed a 3 cm round lesion involving the basal ganglia on the right with a central zone of low density surrounded by an encircling ring of contrast enhancement. There was edema in the surrounding white matter. Biopsy of the lesion demonstrated only nonspecific inflammatory changes. The patient died on postoperative day 25 due to respiratory complications. At autopsy, a single brain lesion was found, measuring 3 × 4 cm, involving the right basal ganglia, thalamus, and internal capsule (fig. 2B), formed by granulomatous and necrotic tissues containing many encysted microorganisms characterized as *Toxoplasma gondii*.

Case 3

A 5-year-old boy was admitted with an 8 month history of fever and weight loss. On examination, enlargement of the cervical lymph nodes, liver, and spleen were noted. A diagnosis of Hodgkin disease, mixed cellularity, stage IIIB, was made by lymph node biopsy and laparotomy, and treatment with MOPP was begun. Five months later he returned with right hemiplegia and bilateral Babinski signs. CT showed a round lesion 12 mm in diameter in the posterior portion of the basal ganglia on the right with ringlike contrast enhancement (fig. 3A), and several small irregular enhancing nodules involving the right parietal and both occipital lobes.

¹ Department of Radiology, Hospital Nossa Senhora das Graças and Hospital de Clínicas of the Federal University of Paraná, Curitiba, Brazil. Address reprint requests to S. Mazer, Benjamin Constant, 90/113, 80.000 Curitiba, Brazil.

² Department of Neurosurgery, Hospital Nossa Senhora das Graças and Hospital de Clínicas of the Federal University of Paraná, Curitiba, Brazil.

³ Department of Pediatrics, Hospital Nossa Senhora das Graças and Hospital de Clínicas of the Federal University of Paraná, Curitiba, Brazil.

⁴ Department of Pathology, Hospital Nossa Senhora das Graças and Hospital de Clínicas of the Federal University of Paraná, Curitiba, Brazil.

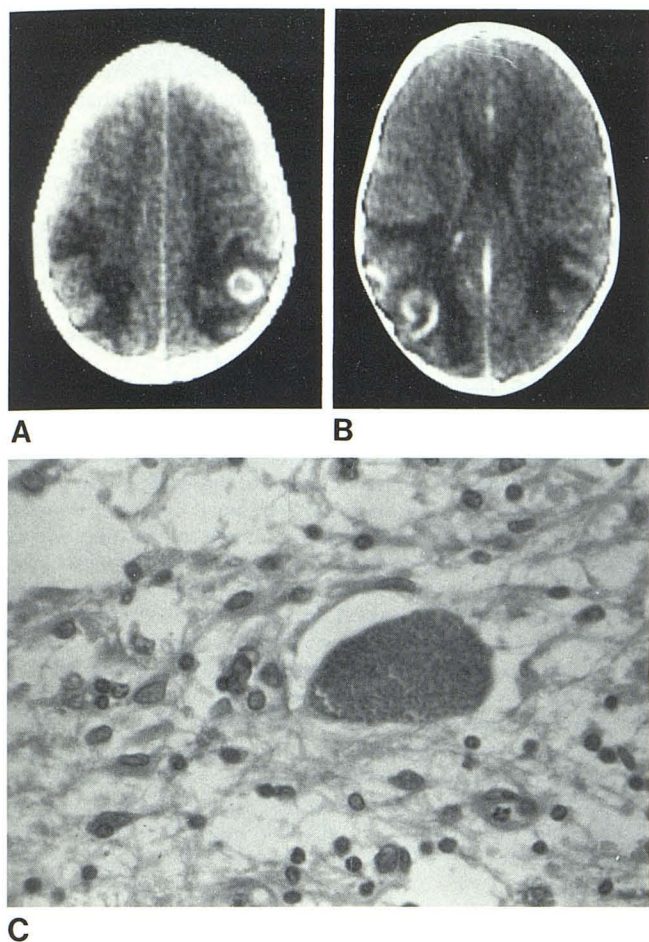


Fig. 1.—Case 1. CT presentation of toxoplasmosis lesions in patient with diagnosis of Hodgkin disease. **A**, Round lesion with peripheral ringlike contrast enhancement and surrounding edema in right parietal lobe. **B**, Incomplete ring of contrast enhancement and adjacent semicircular lesion, both surrounded by white matter edema, in left temporooccipital region. **C**, Microscopic examination showing pseudocysts containing *Toxoplasma gondii* trophozoites.

Considering the experience acquired with the previous cases and despite negative IgM and IgG immunofluorescence antibody tests, a presumptive diagnosis of toxoplasmosis was made. The patient was treated with pyrimethamine, sulfonamide, and leucovorin with total disappearance of the clinical symptomatology. A repeat CT study 1 month later was normal (fig. 3B). On clinical reevaluation 7 months later the patient was neurologically intact.

Discussion

Toxoplasmosis involving the central nervous system may have several different clinical and pathological presentations, including hydrocephalus with multiple intracerebral calcified lesions, which are easily detected by CT. A growing number of cases presenting as one or several intracerebral "mass lesions" are being reported [10, 11] in patients with disturbances of their immunologic systems, notably those harboring neoplasms of the hematopoietic system and/or undergoing treatment with immunosuppressive drugs. In these patients, due to impaired immune reaction, serologic tests

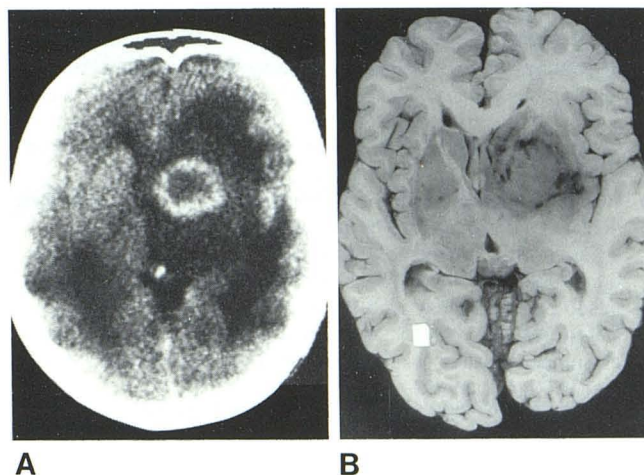


Fig. 2.—Case 2. CT presentation of toxoplasmosis lesions in patient with diagnosis of lupus erythematosus. **A**, 3-cm-diameter single-contrast enhancing ring lesion with central hypodense area and extensive surrounding edema in right basal ganglia. **B**, Corresponding area of granulomatous and necrotic tissues that contained *Toxoplasma* parasites.

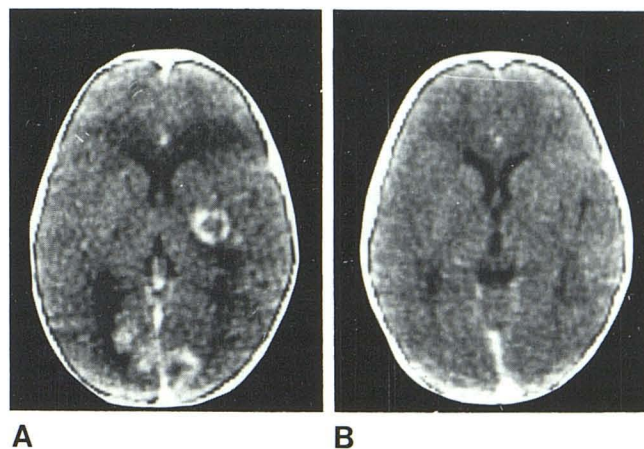


Fig. 3.—Case 3. **A**, Pretreatment scan. Round lesion with peripheral ringlike contrast enhancement involving right basal ganglia posteriorly. Additional irregular enhancing lesions in both occipital lobes. **B**, Repeat postcontrast scan 1 month after specific therapy for toxoplasmosis is normal.

may be negative for toxoplasmosis [3] despite the presence of active disease, as exemplified in our cases 1 and 3. The lesions demonstrated by CT are usually nonspecific, and the differential diagnosis includes all single or multiple ringlike lesions, mainly pyogenic abscesses, gliomas, and intracerebral metastases. The central area of necrosis and the peripheral granulation tissue surrounded by edematous cerebral tissue account for the annular appearance of the "toxoplasmoses" on CT.

Toxoplasmosis, a potentially fatal disease in immunosuppressed patients, may be successfully treated. Therefore, we suggest that even in the absence of positive biopsy or laboratory data, when findings similar to those described above are shown by CT in immunosuppressed patients, clinical suspicion of toxoplasmosis should be raised and vigorous treatment initiated.

REFERENCES

1. Bamford CR. Toxoplasmosis mimicking a brain abscess in an adult with treated scleroderma. *Neurology (NY)* **1975**;25:343-345
2. Townsend JJ, Wolinski JS, Baringer JR, Johnson PC. Acquired toxoplasmosis. *Arch Neurol* **1975**;32:335-343
3. Ruskin J, Remington JS. Toxoplasmosis in the compromised host. *Ann Intern Med* **1976**;84:193-199
4. Emerson RG, Jardine DS, Milvenan ES, et al. Toxoplasmosis: a treatable neurologic disease in the immunologically compromised patient. *Pediatrics* **1981**;67:653-655
5. Carey RM, Kimball AC, Armstrong D, Lieberman PH. Toxoplasmosis—clinical experiences in a cancer hospital. *Am J Med* **1973**;54:30-38
6. Masson R, Fièrè D, Lahnèche B, Cordat CI, Berger F, Revol L. Toxoplasmosis encéphalique pseudo-tumorale au cours d'une hémopathie. *Nouv Presse Med* **1975**;18:2499-2502
7. Mcleod R, Berry PF, Marshall WH Jr, Hunt SA, Ryning FW, Remington JS. Toxoplasmosis presenting as brain abscesses. *Am J Med* **1979**;67:711-714
8. Alenghat JP, Morris JH, Kido DK, Rumbaugh CL. Computed tomography in opportunistic cerebral toxoplasmosis. *Comput Tomogr* **1979**;3:413-416
9. Araujo JC, Cichon E, El Sarraf R, Antoniuk A. Tumoral form of toxoplasmosis. In: *Proceedings of the XVIII Latin American Congress of Neurosurgery*. Buenos Aires, November **1979**:261-263
10. Schulhof LA, Russel JR. Intracerebral toxoplasmosis presenting as a mass lesion. *Surg Neurol* **1975**;4:9-11
11. Tognetti F, Galassi E, Gaist G. Neurological toxoplasmosis presenting as a brain tumor. *J Neurosurg* **1982**;56:716-721