



**Providing Choice & Value**  
Generic CT and MRI Contrast Agents

**FRESENIUS  
KABI**

**CONTACT REP**

**AJNR**

## **Percutaneous Treatment of Cervical Disk Hernias Using Gelified Ethanol**

J. Theron, H. Cuellar, T. Sola, L. Guimaraens, A. Casasco  
and P. Courtheoux

*AJNR Am J Neuroradiol* 2010, 31 (8) 1454-1456

doi: <https://doi.org/10.3174/ajnr.A1923>

<http://www.ajnr.org/content/31/8/1454>

This information is current as  
of July 30, 2025.

## TECHNICAL NOTE

J. Theron  
H. Cuellar  
T. Sola  
L. Guimaraens  
A. Casasco  
P. Courtheoux

# Percutaneous Treatment of Cervical Disk Hernias Using Gelified Ethanol

**SUMMARY:** This study investigates the efficacy of chemonucleolysis using RGE in the treatment of cervical disk hernias in a small sample of patients who had cervical diskogenic or radicular pain secondary to disk herniations. Results were satisfactory in 89.5% patients, with no adverse events recorded during the procedure or after. The use of RGE shows promising results and might be a feasible and safe alternative in the treatment of cervical disk hernias.

**ABBREVIATIONS:** CHU = Centre Hospitalier Universitaire; IDH = intervertebral disk hernias; RGE = radiopaque gelified ethanol

**C**hemonucleolysis is an efficient technique for the treatment of back pain; it consists of a percutaneous intradiskal injection that dissolves the nucleus pulposus and lowers intradiskal pressure. Several years ago, the most widely used substance for this was chymopapain, which had an efficacy of close to 80% in lumbar disk herniations and close to 85% in cervical disk hernias<sup>1-3</sup> but was withdrawn from the market due, in part, to anaphylactic reactions to this enzyme.<sup>4</sup> After this, the search for a new drug that could have the same efficacy as chymopapain but without the complications led to the use of pure ethanol<sup>5</sup> for chemonucleolysis with very good results and no allergic complications. The problem with pure ethanol was the high diffusibility of the liquid, which sometimes led to radicular burning pain after the procedure and, more important, to epidural leaks, which could be severe especially at the cervical level, where the spinal cord is closer to the dura.

In treating venous angiomas, we had experience in using gelified pure ethanol, which had the same properties as liquid ethanol but could be better controlled at the time of injection and did not diffuse away from the site of injection.<sup>6,7</sup> We previously published our experience with a similar radiopaque substance in the treatment of lumbar IDH with good results and no complications.<sup>8</sup> In this study, we investigate the potential efficacy of this substance in cervical disk hernias.

## Technique

RGE is a mixture of pure ethanol and a thickening substance with tungsten powder. To investigate the efficacy of RGE, we set up a prospective preliminary study. Approval of the ethics committee of the hospital was obtained. Patients sent to be treated for a cervical IDH percutaneously, who had cervical diskogenic or radicular pain that did not resolve after the use of conventional therapy, were offered this alternative. An informed consent was obtained.

For treatment purposes, we kept the basis of our original therapeutic concept used for many years: To reach the disk, we positioned

the patient supine with a right anterolateral approach. After the treatment of the disk, we performed a concomitant injection of intra-articular steroids in the adjacent facet joints in all patients.<sup>9</sup>

Procedures were performed with local anesthetic, under surgical conditions and controlled digital fluoroscopy. A diskography was performed before RGE nucleolysis. The dose of RGE injected into the cervical disk was 0.2–0.3 mL. Intradiskal injection of 1–2 mg of gentamicin was systematically performed in all the cases at the end of the procedure to prevent infection. At least 1 facet joint at the level treated was injected with 10 mg of intra-articular triamcinolone acetonide to help reduce inflammation. In case of bilateral symptoms, the injection was performed in both facet joints (10 mg each). The level or levels for treatment were chosen according to the patient's symptoms, MR imaging findings if they were concordant, or a positive provocation test performed during diskography.

All patients underwent thin-section CT of the treated level, performed 3 hours after injection to evaluate the distribution and possible leaks. Patients were left on anti-inflammatory drugs until the follow-up consultation at 15 days. Medical treatment was eventually modified, depending on the residual symptoms. All patients were seen in consultation again 6 weeks after treatment.

Fifty-seven patients were treated by using chemonucleolysis with RGE between 2004 and 2008; 89.5% reported important reduction or disappearance of their symptoms at the first clinical consultation and no adverse events of any kind have been recorded during or after the procedure.

## Discussion

The main goal of percutaneous interventional techniques for the treatment of disk hernias is to reduce the hyperpressure inside the disk and the hernia that compresses the nerve root and also to reduce inflammation produced by annular tears or even by disk degeneration alone, which can be responsible for pain.<sup>9-11</sup> Replacement techniques were sought by using decompressive intradiskal techniques based on physical processes such as disk vaporization in nucleoplasty with radiofrequency, electrothermal therapy, or mechanical reduction of the disk pressure by manual or automated percutaneous discectomy.<sup>12-15</sup> All of them are somewhat effective but more expensive and time-consuming than chemonucleolysis.

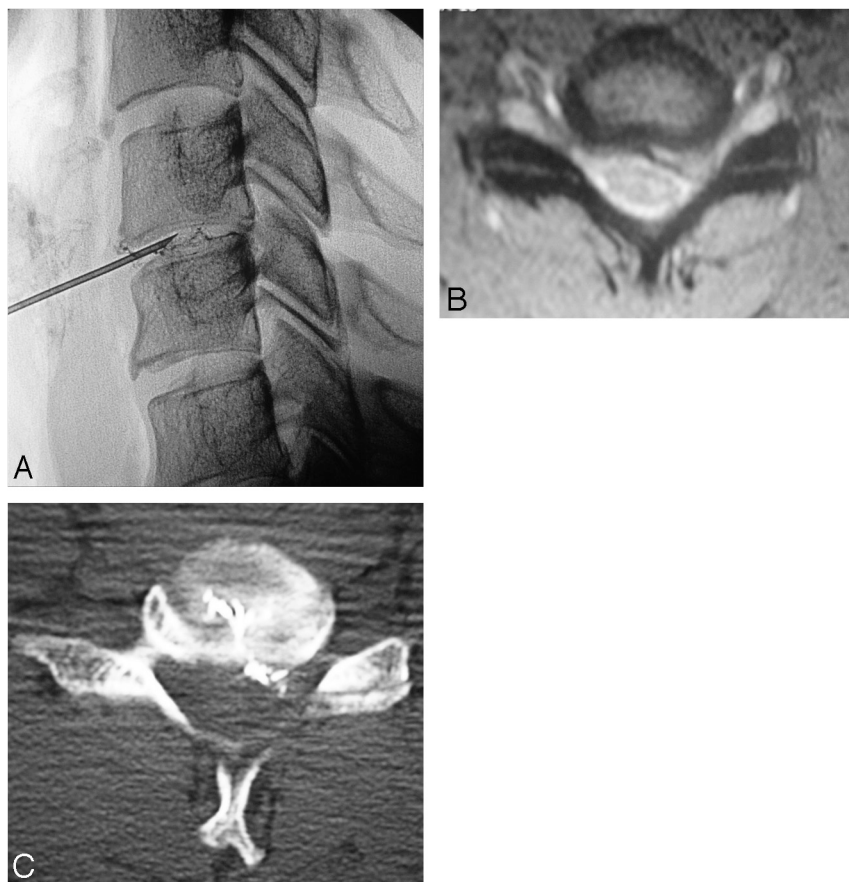
Our initial experience with RGE at the cervical level has shown very promising results for the treatment of cervical IDH, with improvement in symptoms in 89.5% of patients, results similar to those published for chymopapain<sup>16,17</sup> and for ozone,<sup>18</sup> and without allergic complications. The injection of

Received May 21, 2009; accepted after revision September 12.

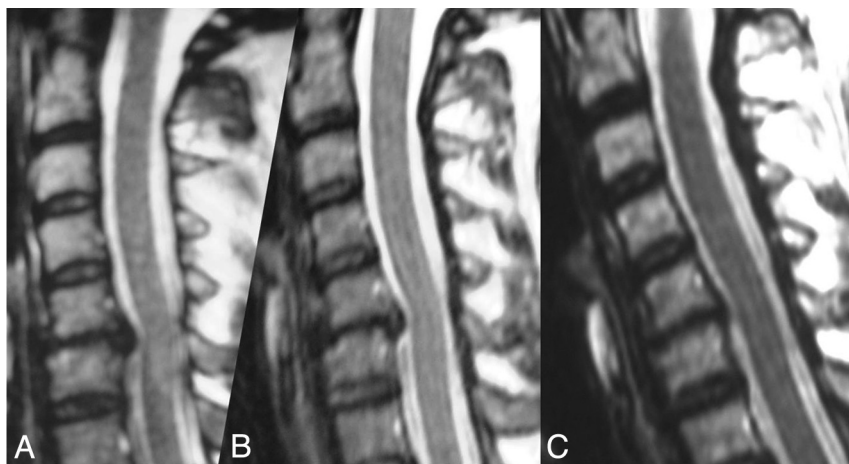
From the Department of Neuroradiologie (J.T., P.C.), CHU Côte de Nacre, Caen, France; Clínica Nuestra Señora del Rosario (H.C., L.G., A.C.), Terapéutica Endovascular y Percutánea, Madrid, Spain; and Department of Therapeutic Neuroangiography (L.G., T.S.), Hospital General de Catalonia, Sant Cugat del Valles, Spain.

Please address correspondence to Jacques Theron, MD, Department of Neuroradiologie, CHU Côte de Nacre, Ave de la Côte de Nacre, Caen, France 14000; e-mail: [theronjcg@aol.com](mailto:theronjcg@aol.com)

DOI 10.3174/ajnr.A1923



**Fig 1.** Cervical disk hernia. *A*, Lateral fluoroscopy during injection of radiopaque gelified ethanol. *B*, MR image obtained before treatment. *C*, CT scan obtained after treatment showing the radiopaque gel following the fissure of the disk and penetrating the extruded fragment.



**Fig 2.** *A*, MR image before treatment in a patient with cervical and radicular pain and a C5-C6 disk hernia. *B*, MR image 6 weeks after treatment with minimal change in the morphology of the hernia, but the patient is clinically asymptomatic. *C*, MR image 4 years after treatment shows complete disappearance of the disk hernia. The patient remains asymptomatic.

RGE was adequately seen under fluoroscopy and was well distributed in the center of the disk and through the tears into the herniated portion without any epidural leaks; this last effect was corroborated on disko-CT performed after the procedure (Fig 1). The results we obtained are similar to ones previously published for lumbar IDH.<sup>8</sup> This similarity makes this technique and the use of RGE a potential alternative for patients with pain secondary to disk pathology at the cervical level (Fig 2).

### Conclusions

Although this was a small sample, we think that the therapeutic efficacy of RGE at the cervical level is promising and without complications related to the procedure so far. In the future, with larger samples and more controlled studies, it might be an alternative in the treatment of cervical IDH, considering that therapeutic solutions respecting the integrity of the spine should be preferred to treat disk hernias when conventional treatment has failed.

## References

1. Gogan WJ, Fraser RD. **Chymopapain: a 10-year, double-blind study.** *Spine (Phila Pa 1976)* 1992;17:388–94
2. Krause D, Drape JL, Jambon F, et al. **Cervical nucleolysis: indications, technique, results—190 patients.** *J Neuroradiol* 1993;20:42–59
3. Theron J, Blais M, Casasco A, et al. **Therapeutic radiology of the lumbar spine: disk chemonucleolysis, infiltration, and coagulation of posterior articulations.** *J Neuroradiol* 1983;10:209–30
4. Hall BB, McCulloch JA. **Anaphylactic reactions following the intradiscal injection of chymopapain under local anesthesia.** *J Bone Joint Surg Am* 1983;65:1215–19
5. Riquelme C, Musacchio M, Mont'Alverne F, et al. **Chemonucleolysis of lumbar disc herniation with ethanol.** *J Neuroradiol* 2001;28:219–29
6. Sannier K, Domp Martin A, Theron J, et al. **A new sclerosing agent in the treatment of venous malformations: study on 23 cases.** *Interventional Neuroradiology* 2004;10:113–27
7. Turet I, Hecquard C, Leroyer R, et al. **Formulation of a sclerosing ethylcellulose alcoholic gel in the treatment of venous malformations.** *J Pharm Clin* 2001;20:12–16
8. Theron J, Guimaraens L, Casasco A, et al. **Percutaneous treatment of lumbar intervertebral disk hernias with radiopaque gelified ethanol: a preliminary study.** *J Spinal Disord Tech* 2007;20:526–32
9. Theron J. **Percutaneous treatment of cervical and lumbar disc herniations.** In: Connors JJ, Wojak, JC, eds. *Interventional Neuroradiology: Strategies and Practical Techniques.* Philadelphia: W.B. Saunders; 1999:424–30
10. Freemont AJ. **The cellular pathobiology of the degenerate intervertebral disc and discogenic back pain.** *Rheumatology (Oxford)* 2009;48:5–10
11. Peng B, Wu W, Hou S, et al. **The pathogenesis of discogenic low back pain.** *J Bone Joint Surg Br* 2005;87:62–67
12. Birnbaum K. **Percutaneous cervical disc decompression.** *Surg Radiol Anat* 2009;31:379–87. Epub 2009 Feb 4
13. Freeman BJ, Mehdian R. **Intradiscal electrothermal therapy, percutaneous discectomy, and nucleoplasty: what is the current evidence?** *Curr Pain Headache Rep* 2008;12:14–21
14. Onik G, Maroon J, Helms C, et al. **Automated percutaneous discectomy: initial patient experience—work in progress.** *Radiology* 1987;162:129–32
15. Theron J, Huet H, Coskun O. **Cervical automated discectomy: report of 150 cases and evolution in the management of failure cases.** *Interventional Neuroradiology* 1996;2:35–44
16. Gomez-Castresana F, Vazquez Herrero C, Baltes Horche JL, et al. **Cervical chymopapain nucleolysis: MR imaging assessment of chymopapain efficacy.** *Neurosurg Clin N Am* 1996;7:1–16
17. Krause D, Grafe JL, Maithor D, et al. **Cervical chymopapain chemonucleolysis.** *Semin Musculoskelet Radiol* 1997;1:207–14
18. Alexandre A, Coro L, Azuelos A, et al. **Intradiscal injection of oxygen-ozone gas mixture for the treatment of cervical disc herniations.** *Acta Neurochir Suppl* 2005;92:79–82