



Get Clarity On Generics

Cost-Effective CT & MRI Contrast Agents

 FRESENIUS
KABI

[WATCH VIDEO](#)

AJNR

Orbital Roof Blow-out Fractures

Hugh D. Curtin, Patrick Wolfe and Victor Schramm

AJNR Am J Neuroradiol 1982, 3 (5) 531-534

<http://www.ajnr.org/content/3/5/531>

This information is current as
of August 23, 2025.

Orbital Roof Blow-out Fractures

Hugh D. Curtin¹
Patrick Wolfe²
Victor Schramm³

Blow-out fractures usually involve the floor or medial wall of the orbit. However, if the roof of the orbit is thin, a blow-out fracture can occur upward into the frontal sinus. Two cases of orbital roof blow-out fractures are presented including plain films and tomographic findings. Neither fracture required surgical correction.

The term *blow-out fracture* was coined by Smith and Regan [1] to describe an orbital floor fracture caused by a very sudden increase in intraorbital pressure without concomitant fracture of the orbital rim. Most blow-out fractures involve the orbital floor. Less often the medial orbital wall is fractured either solely or in conjunction with a fracture of the floor [2]. Upward displacement fractures involving the orbital roof do occur but these accompany extensive craniofacial fractures and usually involve the orbital rim. This type of fracture does not share the hydraulic etiology of true isolated blow-out fractures. We describe two cases of isolated fractures of the orbital roof with intact orbital rims.

Case Reports

Case 1

A 65-year-old man struck the orbital area in a fall on a curb. The left superior lid was ecchymotic and crepitus was palpated. The orbital rim was intact to palpation. Vision was normal. Extraocular motion was full range, and there was no diplopia.

Plain radiographs demonstrated a fragment of bone displaced into the frontal sinus (fig. 1). There was air in the orbit. Pluridirectional tomography confirmed the integrity of the orbital rim and demonstrated the bony fragment to originate from the orbital roof. A small amount of orbital content, presumably fat, was demonstrable into the frontal sinus. A small density was also demonstrated in the ethmoid sinuses that was thought to represent a small fracture through the lamina papyracea.

Case 2

A 16-year-old girl was struck in the left eye by a baseball. The upper and lower lids were ecchymotic and a lid laceration had been sutured at another hospital. Extraocular motion was full and vision was normal. Plain radiographs demonstrated intraorbital emphysema and a bony fragment extending into the frontal sinus (fig. 2). Anteroposterior (AP) and lateral tomography confirmed the upward blow-out of the orbital roof with intact orbital rim. A small amount of soft tissue was demonstrated herniating into the frontal sinus.

Discussion

The so-called blow-out fracture of the orbit results from blunt trauma to the eye with an object of such a configuration that the force is first applied to the globe rather than the orbital rim. Commonly, this is a dashboard, fist, or ball. In

This article appears in the September/October 1982 issue of *AJNR* and the November 1982 issue of *AJR*.

Received November 17, 1981; accepted after revision February 11, 1982.

¹Department of Radiology, Eye and Ear Hospital, 230 Lothrop St., Pittsburgh, PA 15213. Address reprint requests to H. D. Curtin.

²Department of Radiology, Presbyterian-University Hospital, Pittsburgh, PA 15213.

³Department of Otolaryngology, Eye and Ear Hospital, Pittsburgh, PA 15213.

AJNR 3:531-534, September/October 1982
0195-6108/82/0305-0531 \$00.00
© American Roentgen Ray Society

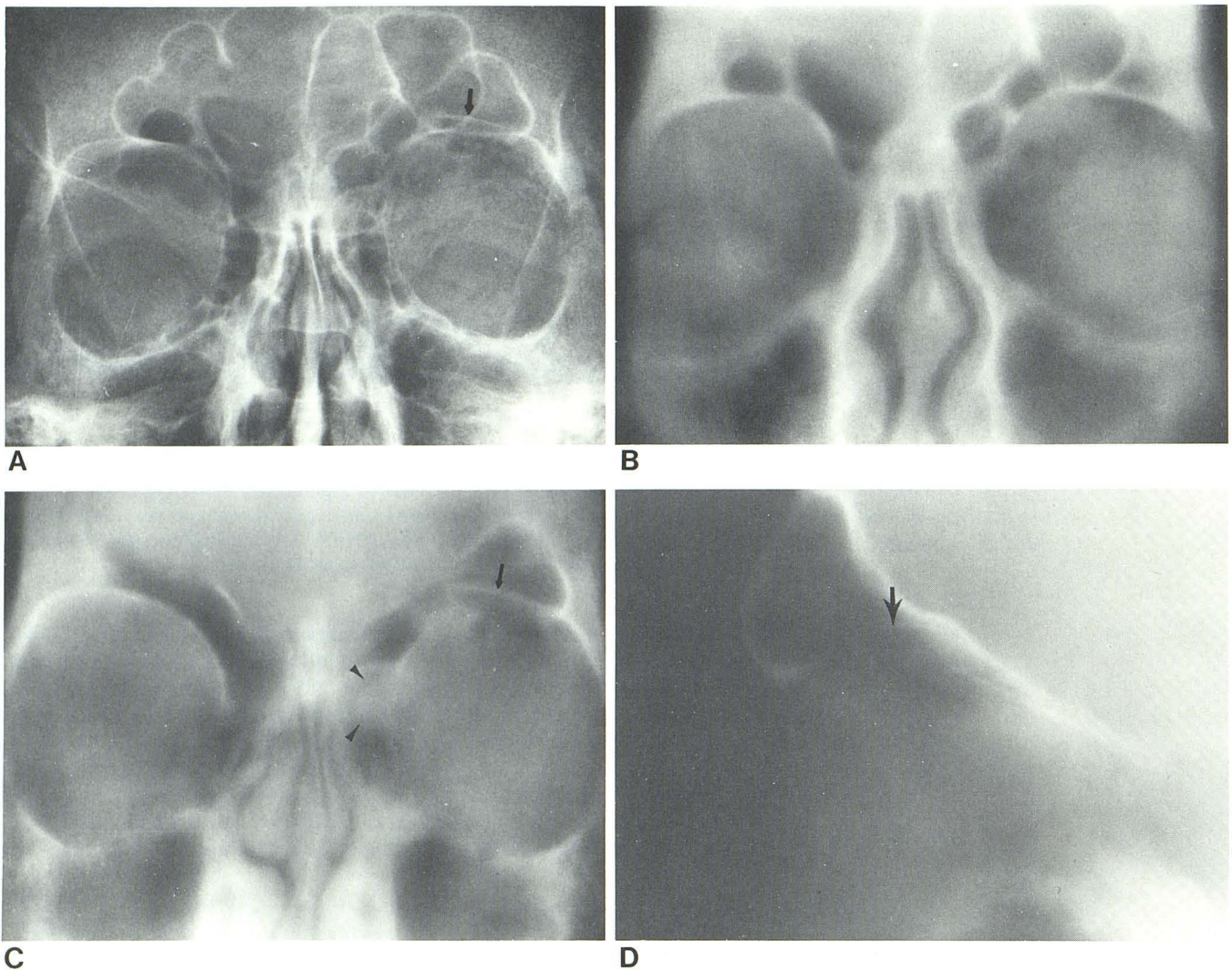


Fig. 1.—Case 1. **A**, Frontal view. Left intraorbital emphysema and fragment of bone displaced upward into left frontal sinus (*arrow*). **B**, Pluridirectional AP tomogram at 19 cm confirms integrity of orbital rim. **C**, Tomogram at 18 cm. Fragment of orbital roof displaced into frontal sinus (*arrow*). Soft-

tissue density in ethmoid sinus (*arrowheads*) suggests lamina papyracea fracture. **D**, Lateral tomogram. Thin bony orbital roof; fragment of bone displaced into frontal sinus (*arrow*).

their classic experiments, Smith and Regan [1] demonstrated that the orbital contents were necessary to produce a typical orbital floor blow-out. They postulated that the sudden increase in intraorbital pressure caused the orbital contents to herniate through the weakest part of the orbit. Clinically and experimentally, blow-outs occur most often through the posterior orbital floor just medial to the infraorbital groove [2]. Less often, the orbital plate of the ethmoid is involved solely or in combination with the floor fracture. Distribution of blow-out location results from a combination of thinness of the bone and its geometric relation to the orbital axis. Complications of blow-out fracture such as diplopia and enophthalmos have several causes and may require surgery to release the entrapped soft tissue and to reconstruct the orbital floor.

Orbital roof fractures usually are part of severe craniofacial injuries. Isolated superior orbital rim fractures result from extensive or localized trauma. Displacement of the orbital rim can cause linear extension into or comminution of the orbital roof. With entrapment of the orbital soft tissues or persistent displacement of the globe, surgery is sometimes required to prevent permanent functional and cosmetic impairment [3, 4]. These fractures are not pure blow-outs in that the roof fracture results from direct compressive or buckling forces rather than the hydraulic pressure. McClurg and Swanson [5] reported a roof fracture causing diplopia as part of a more extensive skull fracture. They postulated that elevation of the intraorbital pressure accompanying a fracture dislocation of the orbital roof caused the orbital fat to become entrapped when the fracture immedi-

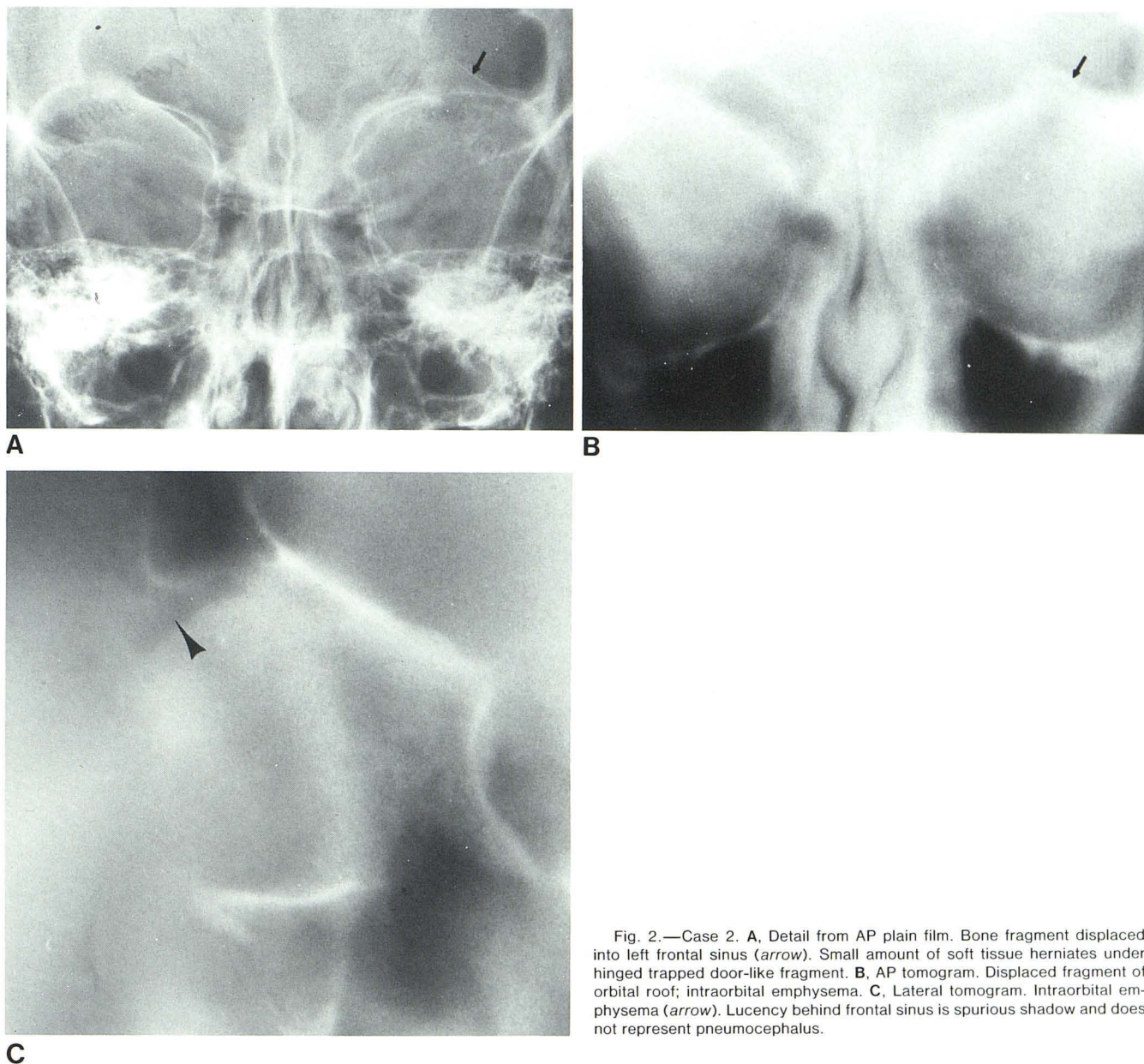


Fig. 2.—Case 2. **A**, Detail from AP plain film. Bone fragment displaced into left frontal sinus (*arrow*). Small amount of soft tissue herniates under hinged trapped door-like fragment. **B**, AP tomogram. Displaced fragment of orbital roof; intraorbital emphysema. **C**, Lateral tomogram. Intraorbital emphysema (*arrow*). Lucency behind frontal sinus is spurious shadow and does not represent pneumocephalus.

ately and spontaneously reduced. The mechanism of injury, the fracture of the orbital rim, and the severe accompanying cerebral, skull, and facial injuries makes this distinct from a blow-out fracture. Therefore, they proposed the designation frontosphenoidal fracture with orbital entrapment. Converse et al. [6] relate the rare observation of blow-outs through the greater wing of the sphenoid and roof of the orbit in association with other fractures of the facial and cranial bones.

Fractures of the orbital roof without concomitant fractures of the orbital rim are unusual. Isolated orbital roof fractures can result from penetrating injuries [7]. Very rarely, the orbital roof can be blown downward by distant skull fractures. This results from a sudden increase in intracranial

pressure being transmitted through the anterior fossa and decompressed by a fracture of the orbital roof [8].

The mechanism of injury and integrity of the orbital rim make our cases similar to the common blow-out fractures of the floor and medial wall of the orbit. In these patients, the thin bone between the frontal sinus and the orbit offered the least resistance to the sudden increase in intraorbital pressure (fig. 3). The thinness of the bony plate in these particular patients may be due to extension of the large frontal sinuses posteriorly into the orbital roofs. The intraorbital emphysema in these cases may have come from the frontal sinus or from associated lamina papyracea fractures into the ethmoid. Neither patient had diplopia, limitation of ocular motion, or enophthalmus, and no surgery was required. No

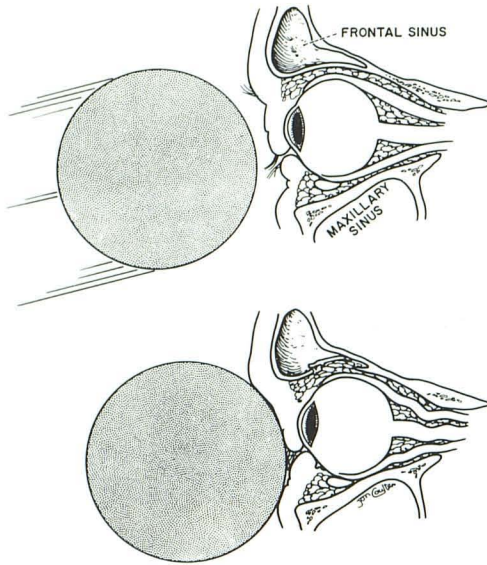


Fig. 3.—Mechanism of upward blow-out fracture: kinetic energy of ball deforms relatively noncompressible orbital contents. Hydraulic pressure is then dissipated by fracture of least resistant surrounding bone, in this case orbital roof.

fracture of the floor of the anterior fossa communicating with the frontal sinus was demonstrated, indicating that the risk of cerebrospinal fluid leak or meningitis was low.

REFERENCES

1. Smith B, Regan WF Sr. Blowout fracture of the orbit: mechanism and correction of internal orbital fractures. *Am J Ophthalmol* 1957;44:733-739
2. Jones DEP, Evans JNG. "Blowout" fractures of the orbit: an investigation into their anatomical basis. *J Laryngol Otol* 1967;81:1109-1120
3. Stranc MF, Gustavson EH. Primary treatment of fractures of the orbital roof. *Proc R Soc Med* 1973;66:303-304
4. Bloem JJ, Meulen JC, Ramselaar JM. Orbital roof fractures. *Mod Probl Ophthalmol* 1975;14:510-512
5. McClurg FL, Swanson PJ. An orbital roof fracture causing diplopia. *Arch Otolaryngol* 1976;102:497-498
6. Converse JM, Smith B, Obear MF, Wood-Smith D. Orbital blowout fractures: a ten-year survey. *Plast Reconstr Surg* 1967;39:20-36
7. Zizmor J, Noyek AM. Orbital trauma. In: Newton TH, Potts DG, eds. *Radiology of the skull and brain*. St. Louis: Mosby, 1971:551-558
8. Sato O, Kamitani H, Kokunai T. Blow-in fracture of both orbital roofs caused by shear strain to the skull. *J Neurosurg* 1978;49:734-738