



Get Clarity On Generics

Cost-Effective CT & MRI Contrast Agents



FRESENIUS
KABI

WATCH VIDEO

AJNR

Dense cystic craniopharyngiomas.

I F Braun, R S Pinto and F Epstein

AJNR Am J Neuroradiol 1982, 3 (2) 139-141

<http://www.ajnr.org/content/3/2/139>

This information is current as
of August 29, 2025.

Dense Cystic Craniopharyngiomas

Ira F. Braun¹
Richard S. Pinto¹
Fred Epstein²

Characteristic computed tomographic (CT) findings of craniopharyngioma include calcification, contrast enhancement, and cyst formation. Sharp margins associated with a hypodense centrum usually characterize the CT appearance of a cystic tumor. The appearance of "dense" cysts in craniopharyngiomas has not been emphasized. Four cases of craniopharyngiomas with isodense to hyperdense cysts are reported. Comparative biochemical and in vitro CT analysis of cyst aspirates taken from these lesions demonstrate that high intracystic protein concentration accounts for the greater part of the hyperdensity. Various mechanisms for intracystic protein accumulation are discussed. Lesion characteristics, and not necessarily attenuation coefficients, are stressed in differentiating "dense" cystic from solid craniopharyngiomas.

Craniopharyngiomas have an epithelial origin and are considered to arise from remnants of Rathke's pouch [1]. They are located, in most cases, in the suprasellar region with occasional extension into the anterior, middle, and posterior cranial fossae. About one-fifth of these tumors are intrasellar [1]. Cyst formation is common, occurring in 84% of craniopharyngiomas studied pathologically [1].

Computed tomographic (CT) diagnosis of craniopharyngiomas relies on three basic CT characteristics: tumoral calcification, contrast enhancement, and intratumoral cyst(s). Not all tumors, however, will display all these features [2]. We report four cases of surgically resected cystic craniopharyngiomas that presented as iso- to hyperdense suprasellar lesions on noncontrast CT. Surgically aspirated intracystic contents in three of four cases had markedly high protein concentrations which we believe account for the major part of the increased density seen on CT.

Materials and Methods

Two of four patients were scanned preoperatively by a Delta 50 scanner, one by an EMI Mark I scanner, and the fourth by a General Electric CT/T 8800. All patients had noncontrast scan and a contrast-enhanced CT scan after the intravenous administration of 4 ml/kg of Reno-M-DIP by infusion technique. One patient had a dynamic CT study using the General Electric CT/T 8800. Coronal scans were made in addition to the axial scans in two patients.

All four patients had intraoperative cyst aspiration. The cyst fluid aspirates were analyzed for total protein in three patients, for albumin and iron in two patients, and for sodium and potassium in one patient. In addition, protein electrophoresis was also obtained in two cases. Before biochemical analysis, the cyst fluid aspirate was scanned in vitro to obtain a numerical attenuation value in two patients.

Results

A summary of the clinical history and symptoms, results of plain film examinations, preoperative CT studies, operative findings, and pertinent laboratory

Received June 8, 1981; accepted after revision September 19, 1981

Presented at the annual meeting of the American Society of Neuroradiology, Chicago, April 1981.

¹ Department of Radiology, New York University Medical Center, 550 First Ave., New York, NY 10016. Address reprint requests to I. F. Braun.

² Department of Neurosurgery, New York University Medical Center, New York, NY 10016.

values obtained in analysis of the intracystic contents are presented in table 1 and illustrated in figures 1-4.

All four tumors were suprasellar. Three had dense nodular calcification and two had curvilinear capsular calcification. All tumors were iso- to hyperdense and lacked enhancement in the interior of the lesion. Dynamic CT (fig. 5) in case 4 showed a flat contrast attenuation curve within the interior of the lesion.

The cyst fluid, obtained intraoperatively, was scanned in a water bath in two patients. The aspirate from case 2 had a CT attenuation value of 20 H and that obtained from case 3, 30 H.

Discussion

The CT characteristics of craniopharyngioma have been reported by Fitz et al. [2] and are described as suprasellar lesions that may be cystic, demonstrate calcified areas, and/or show contrast enhancement. The authors describe a well demarcated area of low attenuation within the tumor mass when describing the lesions as cystic. Although a high density cyst is reported in their series of 40 patients, this was seen postoperatively and no explanation of this hyperdensity was offered, although at reoperation the cyst was said to contain "extremely viscous fluid."

The tumors in our series were partly calcified showing nodular calcification in two and a calcific capsule in the other two. In addition to the areas of calcification, a well circumscribed iso- to hyperdense nonenhancing region is seen in the center of the lesions. All these lesions proved to be grossly cystic at surgery despite the central areas of iso- to hyperdensity on CT.

We believe that high intracystic protein concentration accounts for the major part of the increased density in these cystic lesions. New and Aronow [3] have shown in vitro that

a linear relation exists between observed attenuation coefficients and protein concentration. Salzman [4] obtained similar results using aspirates of various intracranial fluids obtained at surgery. Total intracystic protein concentrations obtained in three of our four cases revealed values similar to that found in human serum in two and a markedly elevated value of 15.2 g/dl in the third. From New and Aronow's study [3], these correspond approximately to 16 H and 36 H, respectively.

In vitro scanning of two of our four cyst aspirates revealed attenuation values in the hyperdense range. Close correlation between in vivo attenuation measurements and in vitro measurements of the aspirates was not obtained. Bydder and Kreel [5] have obtained similar results and regard this difference between in vivo and in vitro measurement of the same sample as due to spectral errors. Other possibilities, such as degradation of unstable proteins with time or in vivo intracystic protein concentration variation from the time of initial CT scan to operation, may account for the discrepancy but remain unproven to date.

The contribution of calcium and iron to the overall CT density is negligible. New and Aronow [3] calculated that 1 mg of iron/100 ml yields an attenuation of 0.0708 H and 1 mg of calcium yields an attenuation of 0.068 H. The values obtained from our aspirates (table 1) are thus clearly too small to contribute to the CT density of the observed cysts.

Cyst formation is common in craniopharyngioma. Of 245 craniopharyngiomas examined at the Armed Forces Institute of Pathology, 84% were at least in part cystic while 60% were exclusively so [1]. Three fundamental mechanisms for cyst formation have been postulated by these authors. These include: (1) degenerative changes in the central part of cellular nests, (2) degenerative changes in the stroma, and (3) maturation and desquamation of squamous epithelium with accumulation of sloughed debris. These three

TABLE 1: Summary of Findings in Case Material

Case No. (age, gender)	Clinical Features	Plain Film	CT	Surgery	Laboratory
1 (13,F)	Headache, nausea, papilledema	Undercut clinoids, suprasellar calcification	Single, dense, sharply marginated, nonenhancing suprasellar mass; hydrocephalus	Cyst drainage, 6 ml fluid obtained	NA
2 (11,F)	Blurred vision o.s.	Suprasellar calcification, erosion of dorsum	Single, hyperdense, nonenhancing, sharply marginated suprasellar mass with posterior calcification	10 ml xanthochromic fluid drained	TP, 3.8 g/dl; Ca ⁺⁺ , 8.6 mg/dl; Fe ⁺⁺ , 246 µg/dl
3 (5,F)	Headache, nausea, vomiting	Suprasellar calcification	Multiple large, sharply marginated, slightly hyperdense masses with peripheral capsular enhancement and calcification	30 ml "crankcase oil" drained	TP, 15.2 g/dl
4 (32,M)	Delayed maturation, nausea, vomiting, headache, chiasmal compression syndrome	...	Single dense, sharply marginated mass; peripheral curvilinear and nodular calcification; erosion of R orbital wall and maxillary antrum; brainstem rotation; flat attenuation curve in lesion interior on dynamic CT	15 ml fluid drained	TP, 5.5 g/dl; Ca ⁺⁺ , 8.6 mg/dl; Fe ⁺⁺ , 180 µg/dl

Note.—TP = total protein; Ca⁺⁺ = calcium concentration; Fe⁺⁺ = iron concentration.

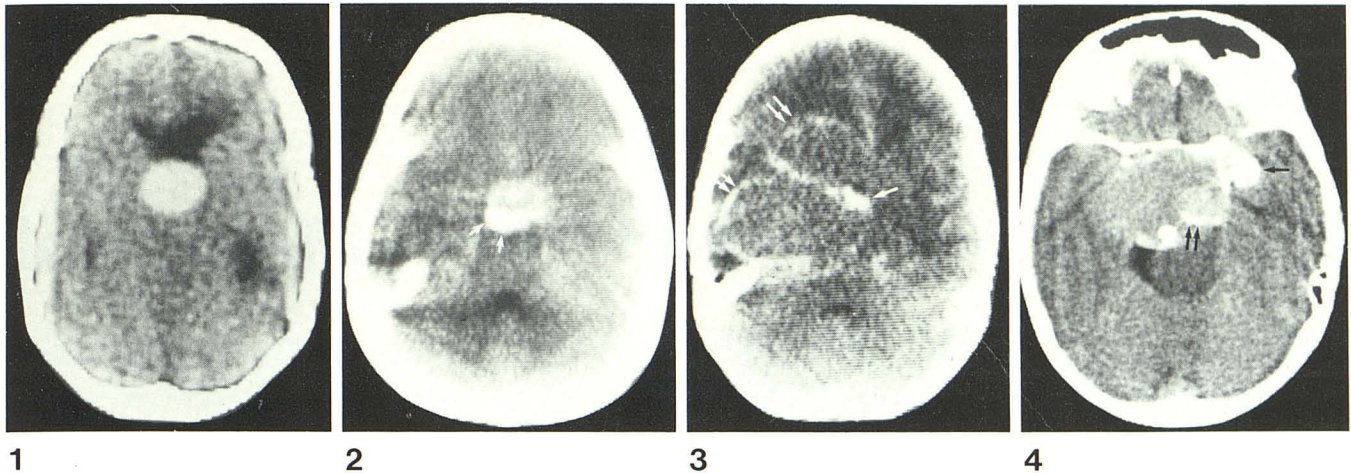


Fig. 1.—Case 1. Noncontrast CT scan. Midline, well circumscribed, sharply margined, hyperdense mass causing ventricular enlargement. After intravenous administration of contrast material, no significant enhancement was noted (not shown).

Fig. 2.—Case 2. Contrast-enhanced image. Sharply margined, midline suprasellar mass which did not have significant contrast enhancement (non-contrast scan not shown). Posterior nodular calcification (arrows).

Fig. 3.—Case 3. Noncontrast axial scan. Several iso- to hyperdense masses emanate from suprasellar region and extend into both anterior and

middle cranial fossae on right. Shift of midline structures toward left. Nodular (arrow) and curvilinear capsular (double arrows) calcification associated with this lesion.

Fig. 4.—Case 4. Contrast-enhanced axial image. Hyperdense, sharply margined suprasellar lesion associated with nodular (arrow) and peripheral curvilinear (double arrows) calcification and brainstem rotation. Comparison with noncontrast scan (not shown) revealed no significant contrast enhancement.

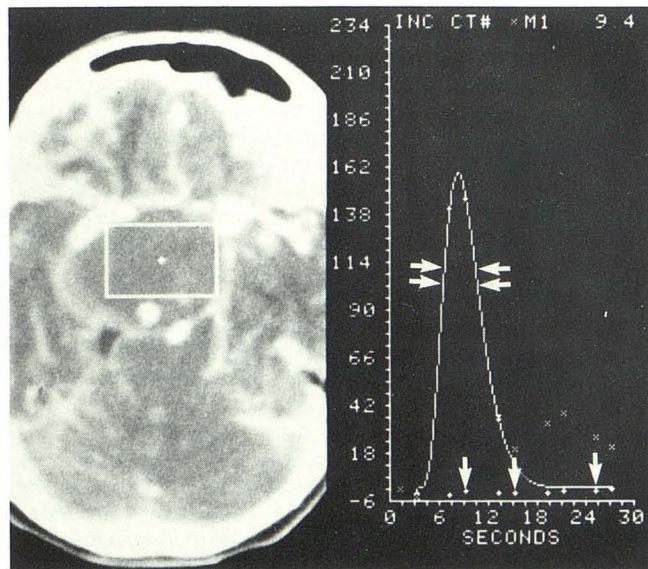


Fig. 5.—Case 4. Dynamic CT scan. Flat time-density curve (single arrows) obtained from interior of lesion, compared to normal rapid washin and washout of vascular time-density curve (double arrows) obtained from middle cerebral artery. This finding is consistent with cyst.

mechanisms, either alone or in combination, may give rise to differing intracystic protein concentration which would account for the observed spectrum of attenuation values. In addition, Hirano et al. [6] reported the occurrence of fenestrated capillaries in craniopharyngiomas which might allow free passage of plasma protein into the cysts.

Clinically, the diagnosis of a cystic or predominantly cystic lesion is important preoperative information. In large lesions, simple cyst aspiration may be the surgical goal for chiasmic decompression and relief of increased intracranial

pressure. Initial cyst decompression may also allow easier access for total and subtotal removal from the vital suprasellar-hypothalamic region.

Lesion characteristics on CT and not specific attenuation coefficients should be considered in differentiating cystic from solid tumors. A dense cyst on noncontrast scan in craniopharyngioma is uncommon, occurring in only four of our series of 63 surgically resected craniopharyngiomas. However, this entity should be suspected if one encounters a well demarcated lesion with sharp margins with a central area of unenhancing homogeneous density regardless of the attenuation values. In addition, calcification of the tumor capsule is common and will raise the index of suspicion of an intratumoral cyst. The diagnosis of cystic lesions may be facilitated by dynamic CT which demonstrates absence of any intratumoral time/density change after contrast infusion.

REFERENCES

- Petito CK, DeGirolami U, Earle KM. Craniopharyngiomas: a clinical and pathological review. *Cancer* 1976;37:1944-1952
- Fitz CR, Wortzman G, Harwood-Nash DC, Holgate RC, Barry JF, Boldt DW. Computed tomography in craniopharyngiomas. *Radiology* 1978;127:687-691
- New PFJ, Aronow S. Attenuation measurements of whole blood and blood fractions in computed tomography. *Radiology* 1976;121:635-640
- Salzman M. Correlation of absorption coefficients with intracranial fluid protein concentrations and specific gravities. *Neurosurgery* 1979;5:16-20
- Bydder GM, Kreel L. Attenuation values of fluid collections within the abdomen. *J Comput Assist Tomogr* 1980;4:145-150
- Hirano A, Chatek NR, Zimmerman HM. Fenestrated blood vessels in craniopharyngioma. *Acta Neuropathol (Berl)* 1973;26:171-177