

Get Clarity On Generics

Cost-Effective CT & MRI Contrast Agents

**FRESENIUS
KABI**

[WATCH VIDEO](#)

AJNR

Serial MR Imaging, Diffusion Tensor Imaging, and MR Spectroscopic Findings in a Child with Progressive Encephalopathy, Edema, Hypsarrhythmia, and Optic Atrophy (PEHO) Syndrome

This information is current as of August 19, 2025.

T.A.G.M. Huisman, A. Klein, B. Werner, T. Straube and E. Boltshauser

AJNR Am J Neuroradiol 2006, 27 (7) 1555-1558
<http://www.ajnr.org/content/27/7/1555>

Serial MR Imaging, Diffusion Tensor Imaging, and MR Spectroscopic Findings in a Child with Progressive Encephalopathy, Edema, Hypsarrhythmia, and Optic Atrophy (PEHO) Syndrome

CASE REPORT

T.A.G.M. Huisman
A. Klein
B. Werner
T. Straube
E. Boltshauser

SUMMARY: PEHO syndrome is a rare symptom complex of severe progressive encephalopathy, edema, hypsarrhythmia, and optic atrophy. Disease onset is in early infancy. The current case report presents and discusses serial conventional MR imaging findings and serial functional studies including diffusion tensor imaging and quantitative MR spectroscopy findings in a 6-year-old child with PEHO.

The PEHO syndrome is a rare symptom complex of severe progressive encephalopathy with edema, hypsarrhythmia, and optic atrophy that has only recently been described by Salonen et al.¹ The distinct clinical features include profound mental retardation, edema of the face and limbs (especially in early childhood), infantile spasms with hypsarrhythmia, and severe hypotonia with prominent deep tendon reflexes.¹ The dysmorphic facial features may raise the suspicion of the PEHO syndrome; these features are, however, nonspecific and result from the progressive microcephaly, edema, and hypotonia.^{1,2} Disease onset is in early infancy. Most children appear healthy at birth or may be slightly hypotonic.^{1,2} Visual failure with abnormal eye movement usually develops early in infancy. The occurrence of affected siblings of both sexes suggest an autosomal recessive inheritance.² No chromosomal abnormality or biochemical marker has yet been identified. Neuroimaging findings have progressively been used in addition to the clinical criteria for diagnosis. CT and MR imaging may show a severe progressive atrophy of the cerebellum and brain stem. Less frequently, a mild cerebral atrophy is noted. Several authors also reported dysmyelination of the cerebral white matter.³⁻⁹

We present and discuss the serial MR imaging, diffusion tensor imaging (DTI), and quantitative MR (¹H-MR) spectroscopy findings of a 6-year-old child with PEHO.

Case Report

We report the case of a girl who was first seen at 4 months of age because of seizures. Neurologic examination showed hypotonia, reduced spontaneous movements, lack of visual fixation, and repeated episodes of upward deviation of the eyes. At the time of presentation, she had plump small hands and feet with tapered fingers. Edematous

hands and feet had been observed previously. Multifocal spike waves and an abnormal background activity were seen on initial electroencephalography. There was, however, no clear ictal pattern. Within the following weeks, hypsarrhythmia developed. Treatment with antiepileptic drugs was started. Flashlight visual evoked potentials showed no cortical response at the age of 7 months, though fundoscopy was normal. At 18 months of age, the left optic disk became pale, and at 30 months a definite bilateral optic nerve atrophy was seen. The child's parents decided to discontinue antiepileptic treatment when she was 3.5 years of age because seizure activity did not improve significantly with treatment. Seizure activity remained stable. The girl was not seen for several years. At the age 6.5 years, her parents found her unresponsive with generalized hypotonia and paleness on the occasion of a febrile gastrointestinal infection. Diazepam and phenobarbitone was given by the emergency physician on the assumption that she was suffering from an epileptic seizure. She was admitted to our children's hospital. She remained somnolent for 3 days with development of a status dystonicus complicated by a rhabdomyolysis. No renal or respiratory complications occurred. In the following weeks, she suffered from multiple hypotonic episodes lasting minutes or hours. During these states, her blood pressure was not measurable and her heart rate was borderline slow (70–80 beats per minute).

Since her initial presentation, 3 MR examinations were performed (at 5 months, 6 years 5 months, and 6 years 11 months). The first MR imaging examination was performed on a 2T MR scanner, the remaining examinations on a 1.5T MR imaging unit. Conventional MR imaging included T1- and T2-weighted sequences. The last 2 examinations also included whole-brain DTI and single voxel quantitative ¹H-MR spectroscopy of the left parietal white matter and left basal ganglia. DTI was performed by using a single-shot spin-echo echo-planar imaging sequence (TR, 6500 milliseconds; TE, 81 milliseconds; field of view, 260 × 260 mm; matrix 128 × 128; section thickness, 4 mm; acquisition, 1). Diffusion encoding was applied along 6 orthogonal directions with an effective b-factor of 1000 s/mm². Isotropic diffusion-weighted images, apparent diffusion coefficient (ADC), and fractional anisotropy maps were calculated. ¹H-MR spectroscopy was acquired by using a point-resolved spectroscopy sequence (TR, 3000 milliseconds; TE, 35 milliseconds; 64 averages; voxel size, 4.54 mL). Calibration of cerebral metabolite concentrations was achieved by using internal tissue water as reference. The spectra were fitted by time-domain data processing by using the LCModel as published previously by Provencher.¹⁰

Received August 30, 2005; accepted September 23.

From the Department of Diagnostic Imaging (T.A.G.M.H., B.W., T.S.) and Division of Neurology (A.K., E.B.), University Children's Hospital Zurich, Zurich, Switzerland.

Addendum: The clinical findings of this child have been discussed in a clinical case study that has been published previously by 2 of the coauthors.⁹ Our case report presents new information that focuses on the neuroradiologic findings, including ¹H-MR and DTI findings, that have not been discussed in the clinical case study.

Address correspondence to Thierry A.G.M. Huisman, MD, Department of Diagnostic Imaging, University Children's Hospital Zurich, Steinwiesstrasse 75, CH-8032 Zurich, Switzerland; e-mail: thierry.huisman@kispi.unizh.ch

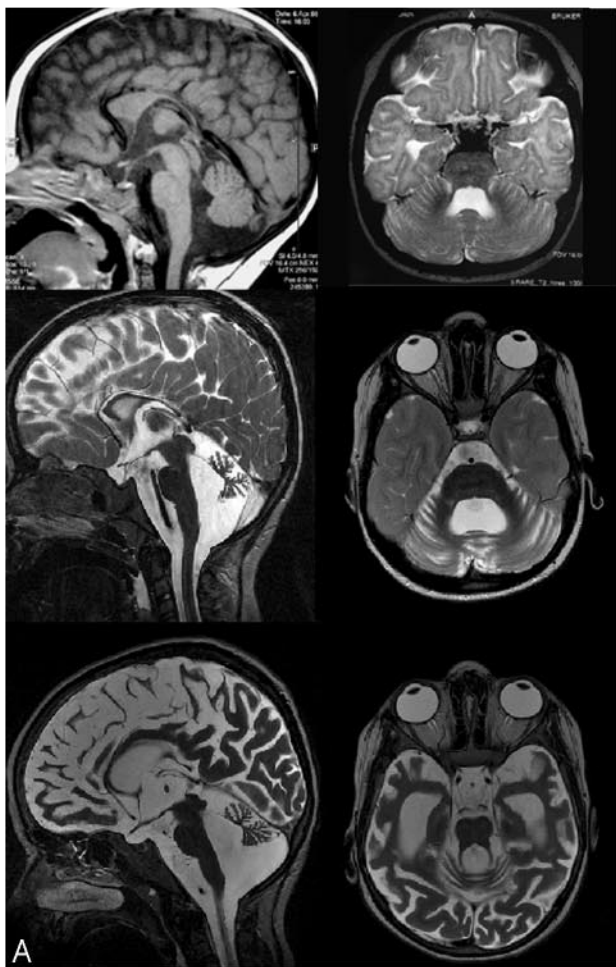


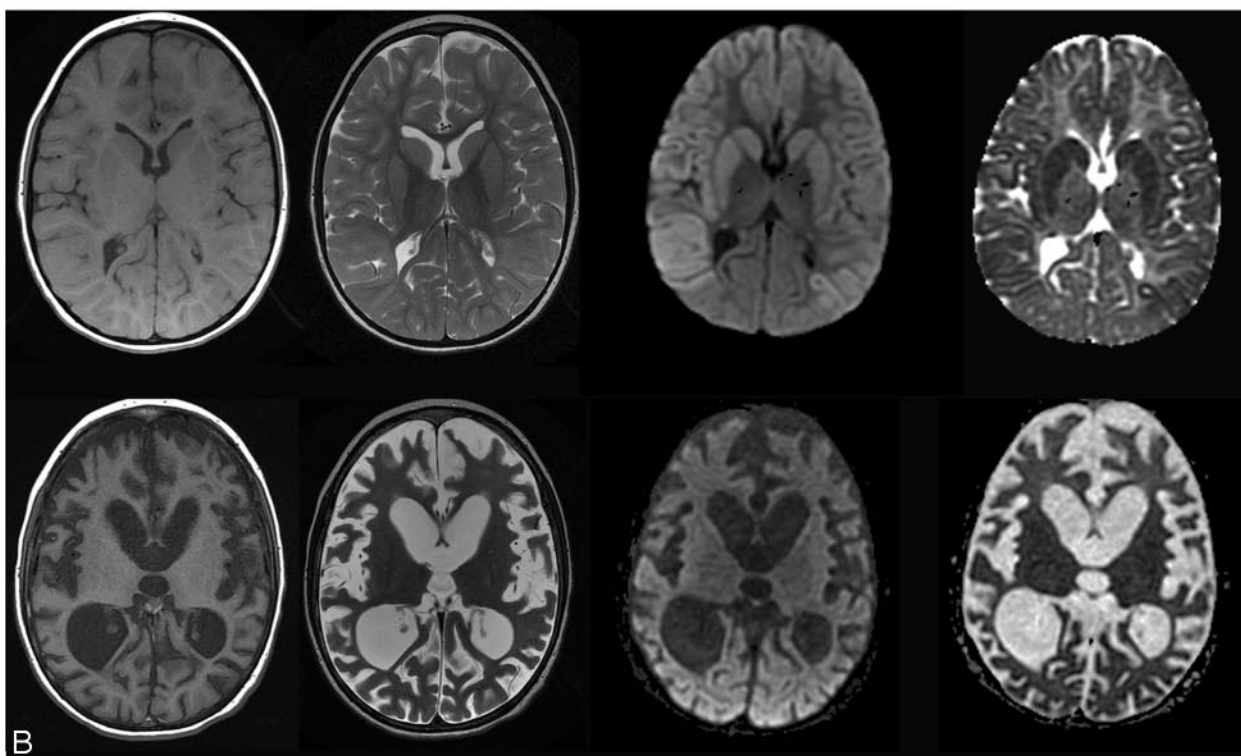
Fig 1. A, Serial MR imaging at 5 months (*top row*), at 6 years 5 months (*middle row*), and 6 years 11 months (*bottom row*). Initial MR imaging shows a thinned corpus callosum and a mild enlargement of the IV ventricle. Follow-up MR imaging shows a severe cerebellar atrophy, the cerebrum appears unaffected. Final MR imaging shows a marked cerebral cortical atrophy. Cerebellar atrophy remains constant.

B, Serial T1-SE, T2-FSE, isotropic DWI, and ADC images at 6 years 5 months (*upper row*) and 6 years 11 months (*bottom row*). At 6 years 5 months, a significant restricted diffusion is seen within the fronto-parieto-temporal cortex, including lateral basal ganglia. The occipital cortex and thalami appear spared. At 6 years 11 months, a corresponding tissue and volume loss are seen of the cortex and lateral basal ganglia. The occipital cortex remains spared.

Table 1: Quantitative ¹H-MR spectroscopy at 6 years 5 months and 6 years 11 months of age

	2nd MR Imaging	3rd MR Imaging	Normative
White matter			
NAA	1.77	2.13	6.9 ± 0.6
Cr	4.81	4.81	4.9 ± 0.4
Cho	1.87	1.83	1.6 ± 0.3
Gray matter			
NAA	4.73	5.02	8.3 ± 0.8
Cr	6.97	6.53	7.6 ± 0.6
Cho	1.85	2.46	1.9 ± 0.2

Note:—NAA indicates *N*-acetylaspartate; Cr, creatine; Cho, choline. Metabolite concentrations are $\mu\text{mol/L}$. NAA concentrations are significantly reduced in the white and central gray matter; Cho and Cr concentrations are normal. Normative age-matched regional values were derived from Pouwels et al.¹¹



Serial conventional MR imaging showed a progressive injury of the brain. Initial MR imaging performed at 5 months of age showed, with the exception of a thin corpus callosum, a morphologically un-

remarkable brain. Myelination was appropriate for age (Fig 1A). No optic atrophy was seen. Follow-up MR imaging at the age of 6 years 5 months showed a severe global atrophy of the cerebellum and optic

Table 2: Apparent diffusion coefficient (ADC) values at 6 years 5 months and 6 years 11 months of age

	2nd MR Imaging	3rd MR Imaging	Normative
Frontal	0.780	0.930	1.02 ± 0.07
Parietal	0.830	0.960	1.01 ± 0.06
Occipital	0.885	0.880	1.01 ± 0.14
Internal capsule	0.590	0.750	0.77 ± 0.04
Putamen	0.420	0.650	0.82 ± 0.08

Note:—ADC values are $\times 10^{-3}$ mm²/s. Initial diffusion tensor imaging revealed a significant reduction of the ADC values within the frontal white matter, internal capsule, and putamen, as well as a mild reduction within the parietal white matter. On follow-up, the ADC values recovered were within normal limits. Normative age-matched regional values were derived from Schneider et al.¹²

nerves with preservation of the brain stem (Fig 1A, -B). No cerebral atrophy was seen. DTI, however, showed a significant restricted diffusion (cytotoxic edema) within most of the cerebral cortex and basal ganglia (Fig 1B). The occipital cortex and thalami appeared normal. Quantitative analysis of the ADC values showed a severe ADC decrease of the frontal, parietal, and temporal cortex next to the internal capsule and putamen. The ADC values of the frontal white matter were mildly decreased, and the ADC values of the parietal and occipital white matter were normal (Table 2). ¹H-MR spectroscopy of the parietal white matter showed a significantly reduced *N*-acetylaspartate (NAA) concentration, whereas choline (Cho) and creatine (Cr) concentrations were within the range of age-matched normative values (Table 1, Fig 2A).¹¹ A double lactate peak was seen. ¹H-MR spectroscopy of the left basal ganglia showed a less severe reduction of NAA concentration, whereas Cho and Cr concentrations were again within the range of age-matched normative values (Table 1; Fig 2B).¹¹ These findings in combination with the cortical cytotoxic edema indicated acute cerebral injury. Follow-up MR imaging 6 months later showed a severe volume loss of the cerebral cortex and basal ganglia that exactly matched the areas of cytotoxic edema on the 2nd MR imaging (Fig 1A, -B). With the exception of the occipital cortex virtually, no cerebral cortex could be seen. Consequently, an *e vacuo* enlargement of the ventricular system was seen because of a global cerebral tissue loss. At the time of follow-up examination, no old or new lesions with restricted diffusion were seen. Quantitative analysis of the ADC values showed a mild ADC increase within the frontal, parietal, and temporal white matter and a significant ADC increase within internal capsule and putamen (Table 2). The ADC values of the cortex could not be measured, because the high degree of cortical atrophy prevented a reliable positioning of a region of interest. Quantitative ¹H-MR spectroscopy showed similar metabolite concentrations within the parietal white matter and basal ganglia with significantly reduced NAA concentrations and normal Cho and Cr concentrations (Table 1; Fig 2A, -B). The lactate peak had diminished. The shapes, or “fingerprints,” of the consecutive ¹H-spectra within the white matter matched each other.

Diagnosis of PEHO was made at 6 years 5 months on the basis of the combination of the progressive encephalopathy, hypsarrhythmia, optic and cerebellar atrophy, edematous hands and feet, and the neuroradiologic imaging findings.

Discussion

PEHO syndrome is a rare progressive neurodegenerative syndrome that has only recently been described.^{1,2} Diagnosis is made by fulfilling a combination of diagnostic criteria, including (1) infantile, usually neonatal, hypotonia; (2) convulsive episodes with myoclonic jerking and infantile spasms (hypsar-

rhythmia); (3) profound psychomotor retardation; (4) absence or early loss of visual fixation with optic atrophy by 2 years of age, extinguished visual evoked potentials; and (5) progressive cerebellar and brain stem atrophy. Supportive criteria include facial dysmorphic features, edema of the face and limbs, brisk tendon reflexes in early childhood, abnormal brain stem auditory evoked potentials, absence of cortical responses of somatosensory evoked potentials, and slow nerve conduction velocities in late childhood.²

Pathogenesis is unclear. Although an autosomal recessive inheritance is suspected, no chromosomal abnormalities or biochemical abnormalities have yet been identified.^{3,4,5,7} Neuropathologic studies have shown a severe neuronal loss within the cerebellar granular layer in combination with a narrowing of the molecular layer and identification of deformed and misaligned Purkinje cells.^{1,2} Within the cerebral cortex, spongy vacuolation of the neuropil, neuronal loss, and proliferation of hypertrophic astrocytes have been seen.^{1,2}

Neuroradiologic features have been described elsewhere.²⁻⁷ The key features of PEHO syndrome encompass a progressive, predominantly cerebellar and brain stem atrophy. Less frequently a minor, nonprogressive supratentorial atrophy is observed.^{2-4,6,7} In addition, an increased T2-signal intensity of the cerebral white matter has been reported by Somer et al.³ This is believed to represent dysmyelination or demyelination. Hypoplasia of the corpus callosum, as well as optic atrophy, has also been identified by MR imaging.^{5,7}

In our case, conventional MR imaging identified all previously described imaging findings, with the exception of the T2-hyperintensity of the cerebral white matter (Fig 2). To the best of our knowledge, this report is the first to discuss serial DTI and ¹H-MR findings in a child with PEHO syndrome.

The identification of a restricted diffusion within the cerebral cortex, white matter, and central gray matter combined with a decreased NAA concentration of the corresponding brain areas and the identification of lactate indicate acute injury of the cerebrum. On follow-up, diffuse injury of the cerebral gray and white matter is confirmed by the corresponding tissue loss and atrophy, as well as the increased ADC values (tissue loss) and persisting low NAA concentrations. (NAA is a marker of neuronal integrity and attenuation.)

It is interesting to note that DTI revealed different degrees of injury comparing cerebral gray and white matter. DTI identified severe injury with profound cytotoxic edema of the cerebral cortex and basal ganglia, whereas the white matter showed only a mild degree of cytotoxic edema. This cerebral gray matter injury may have resulted from the repetitive hypotonic episodes, possibly in combination with brain stem dysregulation (hypoventilation) that occurred on the occasion of the gastrointestinal infection. The low blood pressures may have resulted in a cerebral hypoxic ischemic injury. The higher metabolic rate and coupled higher perfusion rate of the cerebellar and cerebral cortex as well as of the central gray matter compared with the white matter make these regions more susceptible for injury and/or hypoxia.

Another possible explanation in this child with PEHO could be that the cerebral and cerebellar findings represent different degrees and distributions of tissue injury based on a yet unknown inborn or acquired metabolic disorder. The finding that the ¹H-spectra “fingerprint” measured within the

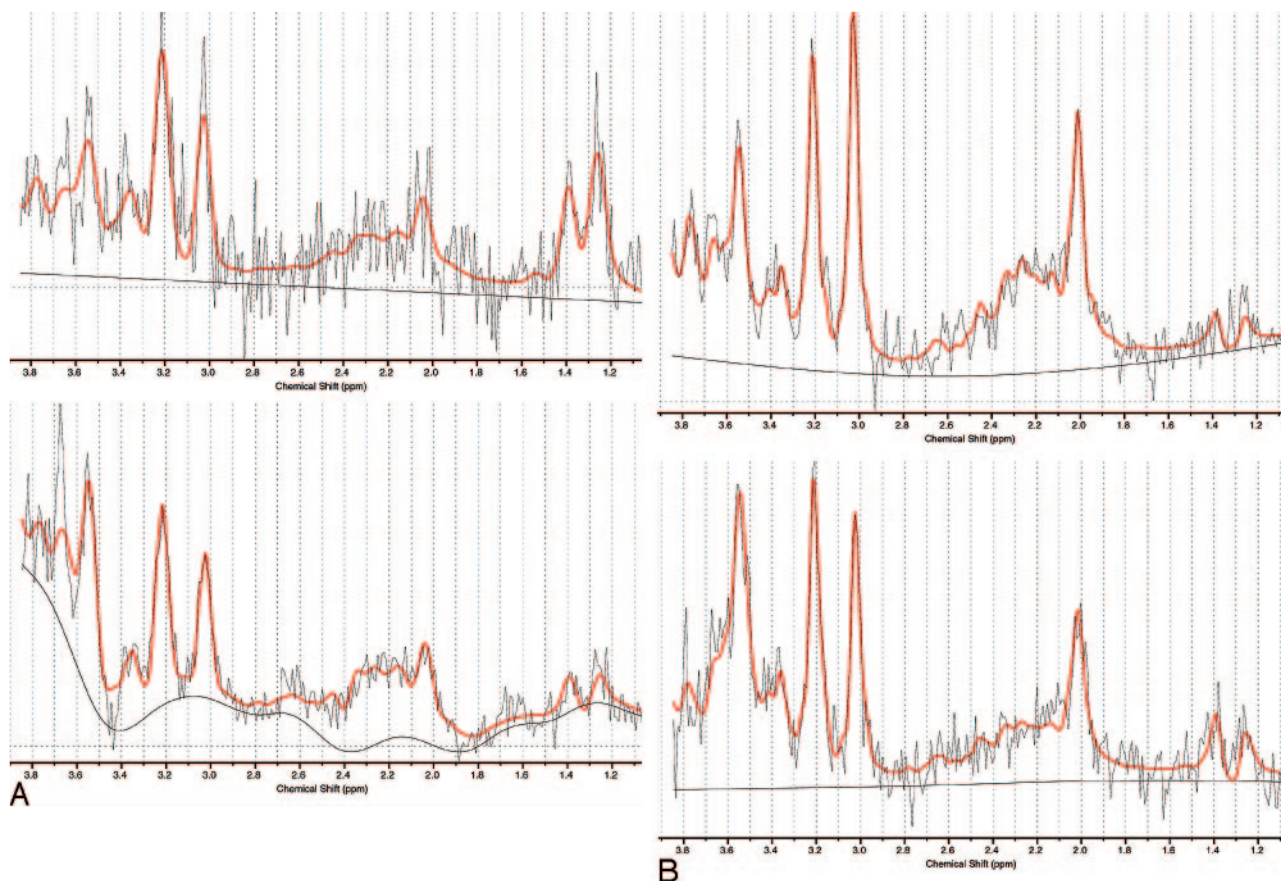


Fig 2. A, Quantitative ^1H -MR spectroscopy of the left parietal white matter at 6 years 5 months (upper spectrum) and 6 years 11 months (lower spectrum). Significant reduction of the NAA peak (at 2 ppm) at both time points. The double lactate peak (at 1.3 ppm) reduces on follow up. Cho and Cr peaks are normal in both serial spectra. B, Quantitative ^1H -MR spectroscopy of the left basal ganglia at 6 years 5 months (upper spectrum) and 6 years 11 months (lower spectrum). The NAA peak (at 2 ppm) is reduced on both spectra. Cho and Cr peaks are within normal limits. A discrete amount of lactate (at 1.3 ppm) is seen on both serial spectra.

white matter remained identical on follow-up with the exception of the reduction of lactate could underline this hypothesis. An exacerbation or acceleration of tissue injury due to a systemic infection is known to occur in various metabolic disorders. It is possible that a similar pathogenesis should be postulated in cases of PEHO. In our patient, MR imaging showed an acute cerebral injury in the setting of a gastrointestinal infection.

In conclusion, further case studies are required to determine whether PEHO is a symptom complex that results from a slowly progressive metabolic disorder that can be accelerated by severe systemic infections or if in PEHO children a sequence of injury (cerebellum > cerebrum) occurs with progressive destruction of different parts of the brain. Functional MR imaging techniques including diffusion tensor imaging, perfusion-weighted imaging, and ^1H -MR spectroscopy could be helpful for a better understanding of the etiology and progression of injury.

References

- Salonen R, Somer M, Haltia M, et al. **Progressive encephalopathy with edema, hypsarrhythmia, and optic atrophy (PEHO syndrome).** *Clin Genet* 1991;39:287–93
- Somer M. **Diagnostic criteria and genetics of the PEHO syndrome.** *J Med Genet* 1993;30:932–36
- Somer M, Salonen O, Pihko H, et al. **PEHO syndrome (progressive encephalopathy with edema, hypsarrhythmia, and optic atrophy): neuroradiologic findings.** *AJNR Am J Neuroradiol* 1993;14:861–67
- Fujimoto S, Yokochi K, Nakano M, et al. **Progressive encephalopathy with edema, hypsarrhythmia, and optic atrophy (PEHO syndrome) in two Japanese siblings.** *Neuropediatrics* 1995;26:270–72
- Nieto-Barrera M, Nieto-Jimenez M, Diaz-Fernandez F, et al. **Progressive encephalopathy with oedema, hypsarrhythmia, and optic atrophy (PEHO syndrome): a case report.** *Rev Neurol* 2003;36:1044–46
- Vanhatalo S, Somer M, Barth PG. **Dutch patients with progressive encephalopathy with edema, hypsarrhythmia, and optic atrophy (PEHO) syndrome.** *Neuropediatrics* 2002;33:100–104
- Field MJ, Grattan-Smith P, Piper SM, et al. **PEHO and PEHO-like syndromes: report of five Australian cases.** *Am J Genet* 2003;122A:6–12
- Riikonen R. **The PEHO syndrome.** *Brain Dev* 2001;23:765–69
- Klein A, Schmitt B, Boltshauser E. **Progressive encephalopathy with edema, hypsarrhythmia and optic atrophy (PEHO) syndrome in a Swiss child.** *Eur J Paediatr Neurol* 2004;8:317–21
- Provencher SW. **Estimation of metabolite concentrations from localized in vivo proton NMR spectra.** *Magn Reson Med* 1993;30:672–79
- Pouwels PJ, Brockmann K, Kruse B, et al. **Regional age dependence of human brain metabolites from infancy to adulthood as detected by quantitative localized proton MRS.** *Pediatr Res* 1999;46:474–85
- Schneider JF, Il'yasov KA, Hennig J, et al. **Fast quantitative diffusion-tensor imaging of cerebral white matter from the neonatal period to adolescence.** *Neuroradiology* 2004;46:258–66