



Providing Choice & Value

Generic CT and MRI Contrast Agents



**FRESENIUS
KABI**

CONTACT REP

AJNR

**Pallidoreticular Damage in Acute Carbon
Monoxide Poisoning: Diffusion-Weighted MR
Imaging Findings**

Toshibumi Kinoshita, Shuji Sugihara, Eiji Matsusue, Shinya
Fujii, Motoki Ametani and Toshihide Ogawa

This information is current as
of July 30, 2025.

AJNR Am J Neuroradiol 2005, 26 (7) 1845-1848
<http://www.ajnr.org/content/26/7/1845>

Pallidoreticular Damage in Acute Carbon Monoxide Poisoning: Diffusion-Weighted MR Imaging Findings

Toshibumi Kinoshita, Shuji Sugihara, Eiji Matsusue, Shinya Fujii, Motoki Ametani, and Toshihide Ogawa

Summary: We describe a case of carbon monoxide poisoning that led to pallidoreticular damage and delayed leukoencephalopathy. Serial diffusion-weighted MR imaging was performed. A restricted water diffusion pattern was demonstrated in the globus pallidus and substantia nigra in the early stage. Diffusion-weighted imaging is useful for early identification of the effects of acute carbon monoxide poisoning.

MR imaging clearly demonstrates various brain abnormalities following carbon monoxide poisoning (1, 2). Although the lesions more commonly involve the globus pallidus and cerebral deep white matter, they occasionally involve the putamen, caudate nucleus, thalamus, or hippocampus (1, 2). Alterations in the substantia nigra are a less common and conspicuous result of carbon monoxide poisoning (3, 4).

Abnormalities of the white matter on diffusion-weighted images have been reported elsewhere (5–7). To the best of our knowledge, however, diffusion-weighted imaging findings of the pallidoreticular pattern of brain damage due to carbon monoxide poisoning have not been described. We present the serial diffusion-weighted MR imaging findings in a patient with carbon monoxide poisoning with pallidoreticular brain damage.

Case Report

A 35-year-old man was admitted to our hospital in an unresponsive condition. He was found after a fire in an automobile. Hyperbaric oxygen therapy was undertaken. Over the next few days, the patient became more alert. MR imaging was performed 5 days after exposure to carbon monoxide. T2-weighted images showed high signal intensity in the bilateral globi pallidi (Fig 1A).

Diffusion-weighted imaging was performed by using 2 levels of diffusion sensitization ($b = 0$ and 1000 s/mm^2) acquired in 3 orthogonal orientations to calculate apparent diffusion coefficient (ADC). Diffusion-weighted imaging revealed high signal intensity in bilateral globi pallidi (Fig 1B). On ADC maps, the corresponding regions revealed discrete areas of low signal

intensity (Fig 1C). The ADC values of the right and left globi pallidi were $0.76 \times 10^{-3} \text{ mm}^2/\text{s}$ and $0.75 \times 10^{-3} \text{ mm}^2/\text{s}$, respectively, whereas the ADC value of the right putamen was $0.86 \times 10^{-3} \text{ mm}^2/\text{s}$. High-signal-intensity rims consistent with vasogenic edema were also noted around the darker restricted areas in the bilateral globi pallidi.

A subsequent MR imaging was performed 12 days after exposure. T1-weighted images showed relatively high-signal-intensity lesions with low-signal-intensity rim in the bilateral globi pallidi (Fig 2A). T2-weighted images showed slightly low-signal-intensity lesions with high-signal-intensity rims in the bilateral globi pallidi (Fig 2B). Coronal T2-weighted images demonstrated high-signal-intensity lesions in the bilateral substantia nigra (Fig 2C). Diffusion-weighted images obtained at the level of the basal ganglia revealed no high-signal-intensity lesions, and no areas of decreased ADC were found in the basal ganglia. Diffusion-weighted images obtained at the level of the midbrain disclosed discrete high-signal-intensity lesions in the pars reticulata of the bilateral substantia nigra (Fig 2D). On ADC maps, the corresponding regions revealed low signal intensity (Fig 2E). The pars compacta of the substantia nigra seemed to be spared relatively on diffusion-weighted images. Hyperbaric oxygen therapy was undertaken until the 18th day after exposure. He was discharged 24 days after exposure to carbon monoxide.

The patient was readmitted 35 days after exposure to carbon monoxide because he had memory disturbance, dysarthria, urinary incontinence, and Parkinsonian symptoms, including rigidity and gait disturbance. He demonstrated a short-stepping gait. Hyperbaric oxygen therapy was again undertaken.

Follow-up MR imaging was performed 2 months after exposure to carbon monoxide. T1-weighted images revealed slightly high-signal-intensity lesions in the pars reticulata of the bilateral substantia nigra (Fig 3A). T2-weighted images showed diffuse high-signal-intensity lesions in the bilateral periventricular deep white matter (Fig 3B). Diffusion-weighted images showed diffuse high-signal-intensity lesions in the bilateral periventricular deep white matter (Fig 3C). Corresponding ADC maps showed low signal intensity in the periventricular deep white matter (Fig 3D). The ADC values of the hypointense deep white matter and isointense subcortical white matter were $0.58\text{--}0.69 \times 10^{-3} \text{ mm}^2/\text{s}$ and $0.78\text{--}0.83 \times 10^{-3} \text{ mm}^2/\text{s}$, respectively. In addition, the symmetrical lesions in the bilateral globi pallidi showed low signal intensity on T1-weighted images and markedly high signal intensity on T2-weighted images. On ADC maps, the signal intensity of the pallidal lesions was increased. The ADC value of the right globus pallidus was $2.1 \times 10^{-3} \text{ mm}^2/\text{s}$. The patient's symptoms gradually improved, although mild Parkinsonian symptoms with slight dysarthria persisted at the 6-month follow-up examination.

Discussion

Carbon monoxide intoxication is one of the most common causes of morbidity due to poisoning (8). It may be intentional or accidental, and exposure can be

Received August 25, 2004; accepted after revision October 5.

From the Division of Radiology, Department of Pathophysiological and Therapeutic Science, Faculty of Medicine, Tottori University, Tottori, Japan.

Address reprint requests to T. Kinoshita, MD, Division of Radiology, Department of Pathophysiological and Therapeutic Science, Tottori University, Faculty of Medicine, 36-1 Nishi-cho, Yonago, Tottori, 683-8504, Japan.

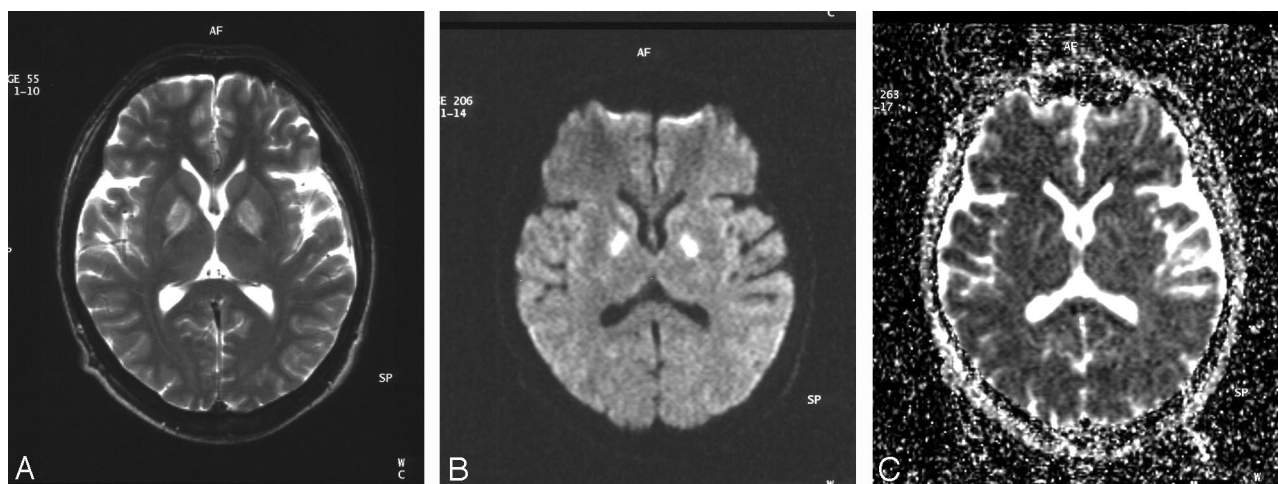


FIG 1. T2-weighted image obtained 5 days after exposure to carbon monoxide (A) shows symmetrical high-signal-intensity lesions in the bilateral globi pallidi. Diffusion-weighted image (B) reveals symmetrical high-signal-intensity lesions in the globi pallidi. Corresponding ADC map (C) demonstrates low-signal-intensity lesions with high-signal-intensity rims in the bilateral globi pallidi.

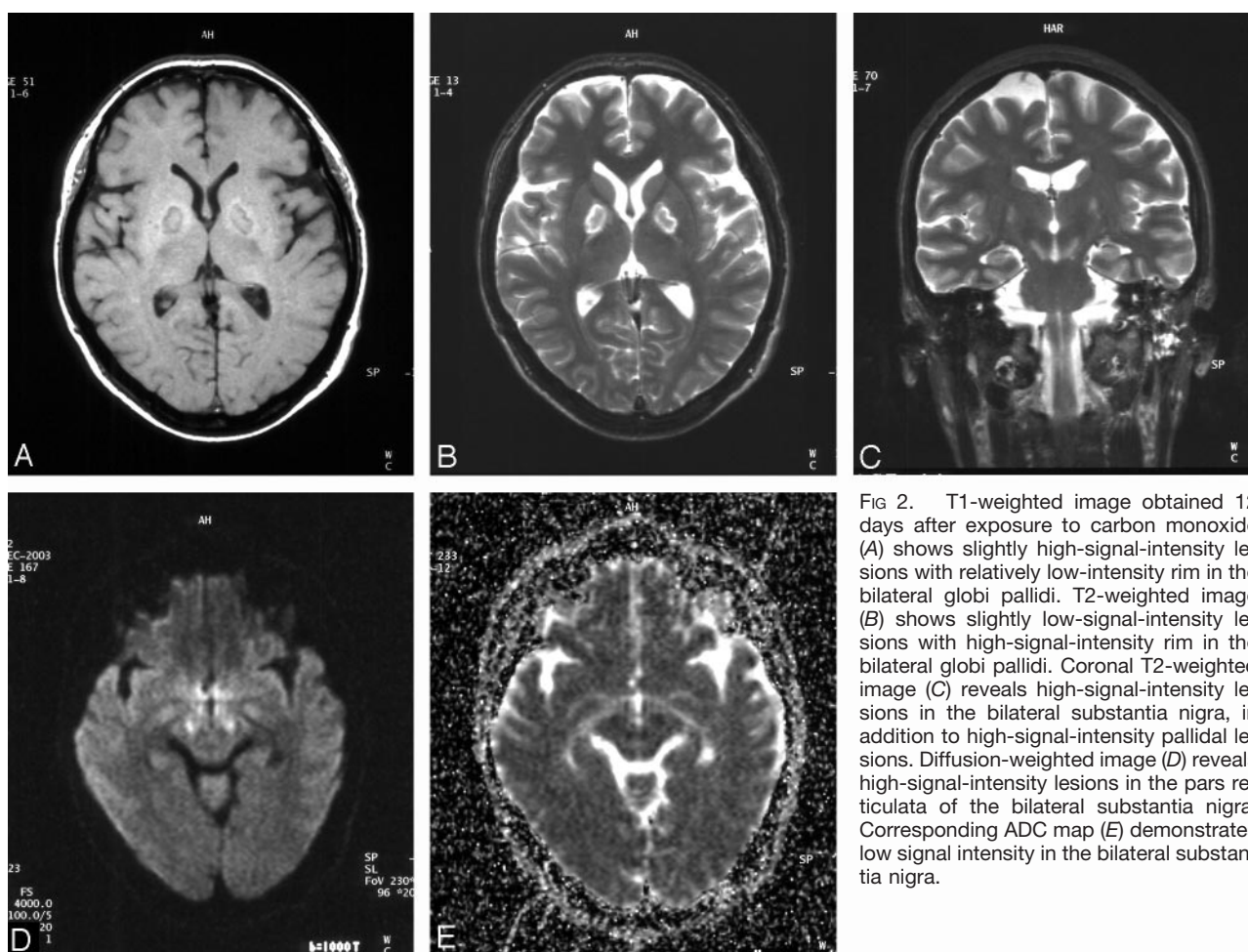


FIG 2. T1-weighted image obtained 12 days after exposure to carbon monoxide (A) shows slightly high-signal-intensity lesions with relatively low-intensity rim in the bilateral globi pallidi. T2-weighted image (B) shows slightly low-signal-intensity lesions with high-signal-intensity rim in the bilateral globi pallidi. Coronal T2-weighted image (C) reveals high-signal-intensity lesions in the bilateral substantia nigra, in addition to high-signal-intensity pallidal lesions. Diffusion-weighted image (D) reveals high-signal-intensity lesions in the pars reticulata of the bilateral substantia nigra. Corresponding ADC map (E) demonstrates low signal intensity in the bilateral substantia nigra.

lethal (8). Carbon monoxide crosses the alveolar capillary membrane and binds strongly to heme-containing compounds. The affinity of hemoglobin for carbon monoxide is approximately 250 times as great as its affinity for oxygen (8, 9). Carbon monoxide toxicity appears to result from a combination of tissue hyp-

oxia and direct carbon monoxide-mediated damage at the cellular level (8).

A sharply demarcated area of necrosis is seen in the pars reticulata of the substantia nigra as well as the globus pallidus when the brain is studied at autopsy after carbon monoxide poisoning (3). The globus pal-

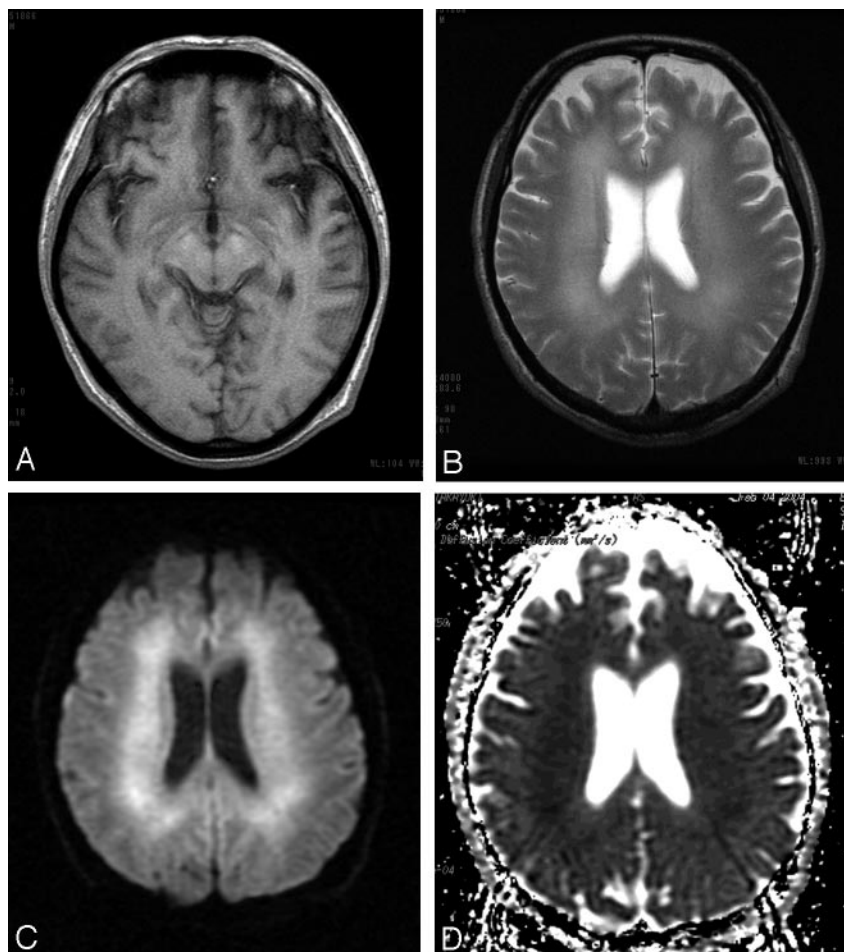


FIG 3. T1-weighted image obtained 2 months after exposure to carbon monoxide (A) shows slightly high-signal-intensity lesions in the bilateral substantia nigra. T2-weighted image (B) shows confluent high-signal-intensity lesions in the bilateral periventricular deep white matter. Diffusion-weighted image (C) reveals diffuse high-signal-intensity lesions in the bilateral periventricular deep white matter. Corresponding ADC map (D) demonstrates low-signal-intensity in the bilateral periventricular deep white matter.

lidus and the pars reticulata of the substantia nigra are the brain regions with the highest iron content (3). Carbon monoxide binds directly to heme iron in these two brain regions (3). This direct histotoxicity explains the selective vulnerability of the pallidoreticularis to carbon monoxide poisoning (3).

To the best of our knowledge, Kawanami et al (4) are the only authors to have reported the MR imaging features of the pallidoreticular pattern of brain damage caused by carbon monoxide poisoning. In their case report, MR imaging was performed 1 year after exposure to carbon monoxide (4). T2-weighted MR imaging disclosed high-signal-intensity lesions in the bilateral substantia nigra in the midbrain, in addition to bilateral high-signal-intensity pallidal lesions (4).

Our case demonstrated that involvement of the identical sites in the early stage of pallidoreticular damage could be visualized by using diffusion-weighted imaging. Reduced water diffusivity could be due to early cytotoxic edema resulting in acute tissue necrosis. The increased ADC of pallidal lesions in the subacute stage is likely to represent a series of pathologic changes from cytotoxic edema to vasogenic edema, and destruction of the cell membrane, culminating cell necrosis.

The lesions with decreased ADC in the globus pallidus and substantia nigra shared a slight increase of signal intensity on follow-up T1-weighted images.

This increased signal intensity on T1-weighted images may indicate the deposition of hemoglobin degradation products due to previous petechial hemorrhage in the globus pallidus, as described elsewhere (9). An alternative explanation for T1 shortening in the globus pallidus and substantia nigra is a nonhemorrhagic mechanism, such as deposition of fat-laden macrophages, degradation of protein, or presence of free radicals or cellular components of necrotic tissue, as described in cases of ischemic injury in the basal ganglia (10, 11). High T1 signal intensity is likely to represent the sequela of acute necrosis.

Carbon monoxide poisoning can lead to demyelination and destruction of cerebral white matter in the late subacute period (3, 5). A local cytotoxic effect of carbon monoxide along with moderate reduction in blood flow may be responsible for the clinical syndrome of delayed deterioration of neurologic and psychiatric symptoms, including cognitive and personal changes, Parkinsonism, urinary or fecal incontinence, mutism, dementia, and psychosis (2, 5, 6, 8). White matter T2 hyperintensities in the centrum semiovale are reported to be significantly associated with cognitive impairment (2). Although extensive white matter lesions may be related to the delayed onset of neuropsychiatry symptoms, pallidoreticular damage is likely to be partially associated with Par-

kinsonian symptoms. Further studies are needed to investigate this in detail.

In patients with delayed anoxic encephalopathy of carbon monoxide poisoning, bilateral, confluent, white matter lesions show decreased water diffusivity on diffusion-weighted imaging (5, 6). A decrease in ADC persists much longer than the few days after acute cell necrosis (5, 6). A relatively persistent decrease in ADC might be caused by slowly progressive cytotoxic edema in the white matter demyelination (5, 6). Alternatively, spongiform leukoencephalopathy with vacuole formation might be involved in restricting the mobility of water molecules in the white matter, as seen in heroin poisoning (12, 13).

In conclusion, diffusion-weighted imaging is useful for delineation of the pallidoreticular pattern of early brain damage, as well as evaluation of delayed white matter damage, in carbon monoxide poisoning.

References

1. O'Donnell P, Buxton PJ, Pitkin A, Jarvis LJ. **The magnetic resonance imaging appearances of the brain in acute carbon monoxide poisoning.** *AJNR Am J Neuroradiol* 2000;55:273-280
2. Parkinson RB, Hopkins RO, Cleavinger BS, et al. **White matter hyperintensities and neuropsychological outcome following carbon monoxide poisoning.** *Neurology* 2002;58:1525-1532
3. Mirra SS, Hyman BT. **Ageing and dementia.** In: Graham DI, Lantos PL, eds. *Greenfield's neuropathology*. 7th ed. London, Arnold;2002:195-272
4. Kawanami T, Kato T, Kurita K, Sasaki H. **The pallidoreticular pattern of brain damage on MRI in a patient with carbon monoxide poisoning.** *J Neurol Neurosurg Psychiatry* 1998;64:282
5. Kim JH, Chang KH, Song IC, et al. **Delayed encephalopathy of acute carbon monoxide intoxication: diffusivity of cerebral white matter lesions.** *AJNR Am J Neuroradiol* 2003;24:1592-1597
6. Murata T, Kimura H, Kado H, et al. **Neuronal damage in the interval form of CO poisoning determined by serial diffusion weighted magnetic resonance imaging plus 1H-magnetic resonance spectroscopy.** *J Neurol Neurosurg Psychiatry* 2001;71:250-253
7. Sener RN. **Acute carbon monoxide poisoning: diffusion MR imaging findings.** *AJNR Am J Neuroradiol* 2003;24:1475-1477
8. Ernst A, Zibrak JD. **Carbon monoxide poisoning.** *N Engl J Med* 1998;339:1603-1608
9. Graham DI. **Hypoxia and vascular disorders.** In: Adams JU, Duchon LW, eds. *Greenfield's neuropathology*. 5th ed. London, Arnold;1992:153-268
10. Komiyama M, Nakajima H, Nishikawa M, Yasui T. **Chronological changes in nonhaemorrhagic brain infarcts with short T1 in the cerebellum and basal ganglia.** *Neuroradiology* 2000;42:492-498
11. Fujioka M. **Specific changes in human brain after hypoglycemic injury.** *Stroke* 1997;28:584-587
12. Egan PJ, Becker FW, Schumm F. **Spongiform leukoencephalopathy after inhaling illicit heroin and due to carbon monoxide-intoxication.** *Fortschr Neurol Psychiatr* 2004;72:26-35
13. Chen CY, Lee KW, Lee CC, et al. **Heroin-induced spongiform leukoencephalopathy: value of diffusion-weighted MR imaging.** *J Comput Assist Tomogr* 2000;24:735-737