



Get Clarity On Generics

Cost-Effective CT & MRI Contrast Agents



FRESENIUS
KABI

WATCH VIDEO

AJNR

Neurologic Applications of Positron Emission Tomography

AJNR Am J Neuroradiol 2004, 25 (5) 902-903

<http://www.ajnr.org/content/25/5/902>

This information is current as
of August 17, 2025.

Neurologic Applications of Positron Emission Tomography

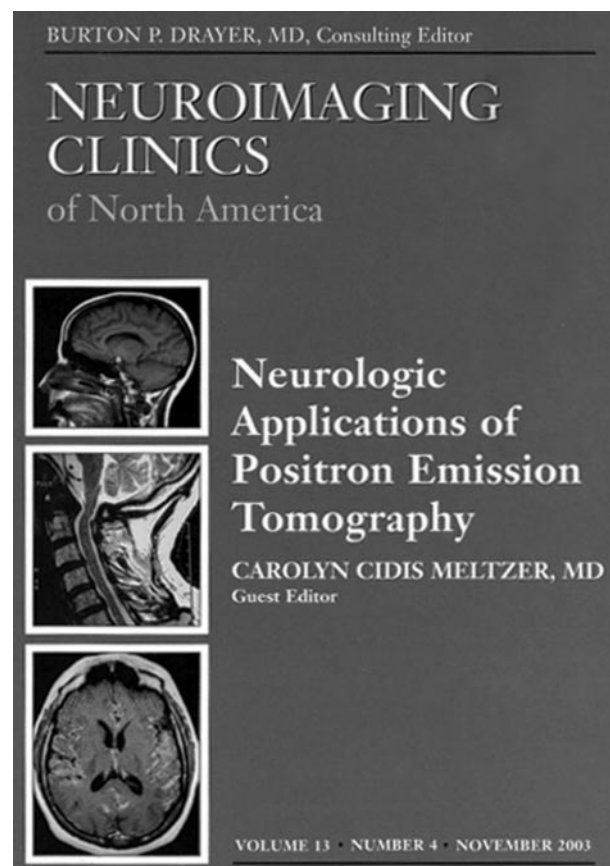
Carolyn Cidis Meltzer, ed. Philadelphia: W.B. Saunders Co.; 2003. 227 pages, 103 illustrations. \$81.

Neuroimaging and positron-emission tomography (PET) have both evolved considerably during the past few decades. Owing to the lack of widespread availability of this technique until recently, very few radiologists (including neuroradiologists) have received formal training in PET imaging. However, there has been an explosion of papers and abstracts focusing on this broad topic over the past few years, although the literature that incorporates all of the pertinent aspects of PET imaging of the brain is limited. For this reason, the November 2003 publication of *Neuroimaging Clinics of North America's Neurologic Applications of Positron Emission Tomography* is fortuitous.

The book is divided into 15 chapters. The first chapter touches on the historical perspective of molecular imaging of the brain. The three chapters that follow cover the basic sciences applicable to PET imaging of the brain. The bulk of the next 10 chapters concerns the clinical applications of PET imaging of the brain. The final chapter gives an overview of the pharmacologic research and development process in which PET imaging is used. Most pertinent subjects are covered adequately in this book.

The historical perspective of molecular imaging of the brain was appropriately chosen as a topic of chapter 1. In that chapter, the author highlights the important advances that occurred leading to the current molecular imaging methods using PET. This easily readable, concise, five-page chapter provides a historical introduction to the subsequent contents of this book.

The next three chapters provide a detailed explanation of the physics of the instrumentation, the pharmacology, and the tracer kinetic analysis pertinent to PET imaging. With a basic knowledge of the physics of the instrumentations and of nuclear physics covered in the second chapter, the reader will have obtained great insight of the capabilities and limitations of this technique, the methods that can be used to optimize the performance of this technique, and a basic knowledge of the most suitable scanner to purchase for one's practice. The third chapter stresses that F-18 fluorodeoxyglucose (FDG) is now the most commonly used radiopharmaceutical for PET imaging. It also provides a brief overview of the production of positron-emitting radionuclides and the other radiopharmaceuticals that potentially will be used for functional imaging of the brain in the future. The fourth chapter covers in detail the principles of tracer kinetics modeling pertinent to PET imaging. The information provided in the chapter will enable the reader to understand how to perform quantifications such as regional cerebral perfusion with O-15 O₂ and receptor binding by mathematic operations. Having a sound knowledge in that subject is important for prac-



tioners having access to a cyclotron and/or actively doing research about neuroreceptor function.

The bulk of this volume emphasizes the possible clinical applications of PET imaging of the brain. The two most common indications are reviewed in the 5th and 6th chapters covering epilepsy and brain tumors. Chapter 5, "Imaging the Epileptic Brain with Positron Emission Tomography," reviews PET imaging with FDG, although the use of other radiopharmaceuticals is also discussed. The scenarios in which FDG-PET offers valuable information not provided by other modalities and the findings of a positive test of a patient with epilepsy are described adequately. The illustrations are also pertinent, clear, and clearly labeled. Chapter 6, "Positron Emission Tomography Imaging of Brain Tumors," emphasizes the use of PET with FDG and discusses situations in which PET imaging is potentially valuable in the evaluation of brain tumors. Examples of positive and negative studies for active tumor with correlation with MR imaging are clearly illustrated in the chapter. The uses of other radiotracers are also discussed, and some clear illustrations of PET with these radiotracers, along with the appropriate correlations, are provided. It is

highly recommended that neuroradiologists or other radiologists reading images of the brain have a good knowledge of these two topics. These two chapters should be considered as required reading materials for all radiology residents during neuroradiology or nuclear medicine rotations.

The next eight chapters discuss other disorders in which PET imaging is potentially useful. They include cerebrovascular disease, Alzheimer disease, movement disorders, depression, schizophrenia, and drug abuse. One chapter discusses the changes of brain function that occur with aging. Although PET is not the imaging technique of choice for diagnosis of cerebrovascular disease, chapter 7, "The Use of Positron Emission Tomography in Cerebrovascular Disease" stresses that PET imaging is a useful specialized research tool because it provides insight of the effects of hemodynamics and changes of metabolism evolving during acute ischemic stroke and intracranial hemorrhage, the potential important prognostic information in acute ischemic stroke, and the mechanisms of stroke recovery and changes of hemodynamics. Two chapters in this book discuss dementia disorder. Chapter 9, "Imaging Alzheimer Disease: Clinical Applications," provides an overview of the appearance of PET images of the brain in patients with Alzheimer disease and with various other dementia disorders. All of these disorders are well illustrated in the chapter. After reading the chapter, one should be able to recognize the cerebral regional metabolic abnormalities on FDG-PET images. The current Medicare reimbursement policy for PET imaging for dementia is also discussed in this chapter. In the next chapter, concerning imaging Alzheimer disease with amyloid-avid agents, provides an overview of the pathologic characteristics and pathogenesis of this disease. The chapter also stresses the promising potential role of amyloid-binding imaging agent for the early diagnosis and clinical management of Alzheimer disease and that some research is currently underway. In the chapter about the role of PET imaging in movement disorders, the various possible radiotracers for Parkinson disease, as well as an overview of the other movement disorders, are provided. In the chapter on the imaging of depression with PET, the changes of regional cerebral glucose metabolism in patients with depression and the effect of therapy in responders and nonresponders are explained. Research to optimize diagnosis and treatment of patients with depression is currently taking place. The chapter about molecular imaging in schizophrenia focuses on the findings of various neurotransmission functions in patients with that disorder, with emphasis in the dopamine system. Chapter

14, "Neuroimaging and Mechanism of Drug Abuse: Interface of Molecular Imaging and Molecular Genetics," provides a scientific overview of the alterations of the neurotransmitter systems with exposure to drugs of abuse, by using PET or SPECT.

The final chapter provides a brief, five-page, overview of the role of PET imaging in the discovery and development of new drugs. This chapter is intended to give insights into value of PET for pharmaceutical companies to study the therapeutic effect of prospective medications and to accelerate the development of new pharmacological treatments.

This volume provides a well-referenced discussion of the application of positron emission tomography in various disorders, the instrumentation of PET, the radiopharmacy, and tracer kinetics. It would have been appropriate to add another chapter about the role of PET imaging of traumatic and chemical brain injuries. Although Medicare does not classify PET imaging of head injury as a reimbursable indication, this technique can provide additional information about functioning abnormalities without structural findings. PET can be valuable in the prognostication of patients with rehabilitation. Fortunately, this topic is well covered in other recent journals.

It is important for radiologists, particularly neuroradiologists, to have reasonable knowledge of this subject because the technique offers complementary and useful clinical information that is not available on anatomic imaging modalities. A sound knowledge of the applications of this technique will be of great benefit in care for a number of patients, because appropriate recommendations can be made by neuroradiologists reporting on other imaging studies of the brain, such as MR imaging and CT scanning, when PET imaging will offer additional valuable information.

A sound understanding of the basic instrumentation of PET and the clinical applications in epilepsy and in brain tumors is important for all neuroradiologists and other radiologists reporting CT and MR findings of the brain. These topics are well covered in the book. Likewise, for practitioners interpreting PET brain images, having a good knowledge of all of the clinical applications described in this book is important. The work is also valuable to researchers of new central neurologic system medications as the radiopharmacy, tracer kinetics, and the role of PET in the development of medications are discussed. This book belongs in every department's library and should be on the shelf of every chief of neuroradiology or neuroradiologic practice. In sum, it is difficult to imagine a radiology practice or a radiologist to whom this book will not be helpful.