



Providing Choice & Value
Generic CT and MRI Contrast Agents



CONTACT REP

AJNR

The Brain Atlas

AJNR Am J Neuroradiol 2004, 25 (4) 658
<http://www.ajnr.org/content/25/4/658>

This information is current as
of July 30, 2025.

The Brain Atlas

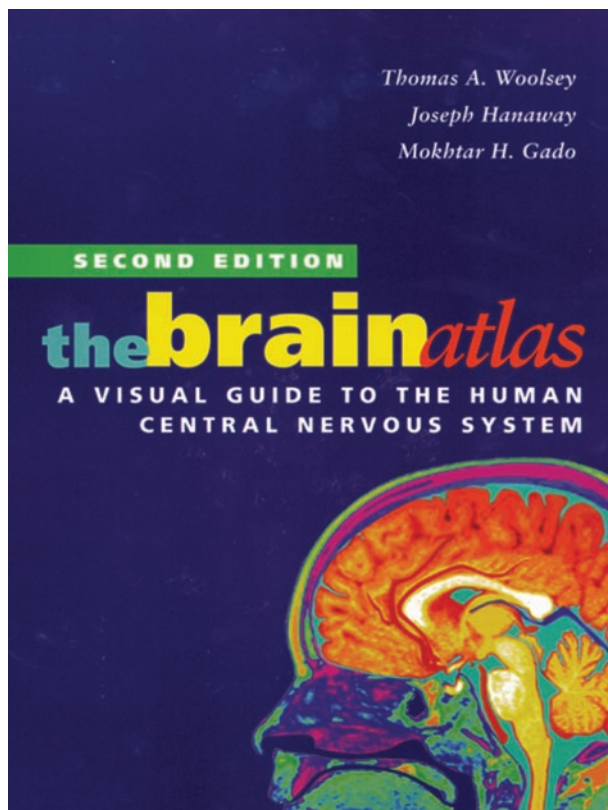
Thomas A. Woolsey, Joseph Hanaway, and Mokhtar H. Gado. 2nd ed. New York: Wiley; 2002. 240 pages, 400 illustrations. \$48.

The second edition of *The Brain Atlas*, by Woolsey, Hanaway and Gado, brings improvements to an already highly successful reference text in the neurosciences. This practical 240-page work brings together basic concepts in neurobiology, functional pathways, gross anatomy, cross-sectional histology, and neuroradiologic images in a single volume. Its audience is primarily medical students and other health science professional students, but it also finds a welcome place with residents in training, academic staff, and practicing physicians.

The book is clearly and logically laid out in five parts. Part I consists of an introduction to the nervous system, including basic concepts of neurobiology and organization of the brain. The end of this section also gives an overview the organization of the book itself, a task which the authors and publisher have done quite well. Throughout the text, figures are clearly labeled clockwise beginning at 12 o'clock, both by number and structural name, with an alphabetized list at the bottom. Each page also contains a small reference drawing to indicate the level of section and plane displayed. The new organization and labeling scheme makes it very easy to navigate through various structures and facilitates streamlined review.

Part II is a short atlas of gross neuroanatomy photographs, brain stem dissections, and neurovascular anatomy. Excellent diagrams depict the major white matter bundles and vascular territories for the brain and spinal cord. These are supplemented by conventional angiograms and MR angiograms. Part III contains gross brain sections, which are beautifully displayed and labeled, well-matched with corresponding T1-weighted MR sections and color-coded vascular territory maps. Part IV continues logically into a multiplanar series of histologic sections of the cord and brain. Although vascular territory correlations are depicted here, unfortunately no correlative radiologic images appear in this chapter. In part V, an excellent series of stacked histologic sections, schematic color overlays, and brief text gives an excellent overview of the major functional pathways of the brain and spinal cord.

A relative weakness is the quality and number of the MR imaging figures. They have been included as routine T1-weighted images of good but not spectacular quality. In future editions, it would be ideal to take advantage of newer technology to provide higher resolution, higher-quality MR imaging figures, perhaps drawn from 3T material. This could also include high-resolution T2-weighted images to compliment the T1 anatomy and new images to match with the brain stem sections. The vascular diagrams in part III should be scaled to better fill the page and match the size of the corresponding histologic sections, facilitating visualization and comparison. Another strong per-



sonal preference for this reviewer would be to reorient the axial brain stem histologic sections and the brain stem pathway diagrams according to conventional neuroradiologic anatomy, not vertically flipped as is the time-honored custom for anatomic atlases. This is a plea driven by the fact that most real-world encounters with the brain stem occur in the radiology reading rooms on cross-sectional CT and MR images, not in anatomy labs and textbooks. Why not reorient brain stem anatomy teaching so it appears as the clinical world sees it? I hope that this and other correlative anatomy-radiologic atlases will adopt the neuroradiologic convention.

Overall, this book is successful in bringing together basic brain biology, gross anatomy, histology, neuro-radiologic correlation, and major functional pathways in a single volume. Its spiral bound format, exceptionally well-organized layout, clear labeling, and excellent figure quality again justify its placement in medical school curricula and allied health teaching programs. It is also useful as a reference or refresher for residents in training and practicing physicians interested in neurosciences. The authors should be congratulated on improving on their prior work and providing this excellent new textbook.