



Get Clarity On Generics

Cost-Effective CT & MRI Contrast Agents

 **FRESENIUS
KABI**

[WATCH VIDEO](#)

AJNR

High-Concentration Ethylene-Vinyl Alcohol Copolymer and Endovascular Treatment of Experimental Aneurysms: Feasibility of Embolization without Protection Devices at the Neck

This information is current as of August 11, 2025.

Jean Raymond, Igor Salazkin, Annick Metcalfe, François Guilbert, Alain Weill and Daniel Roy

AJNR Am J Neuroradiol 2003, 24 (9) 1778-1784
<http://www.ajnr.org/content/24/9/1778>

High-Concentration Ethylene-Vinyl Alcohol Copolymer and Endovascular Treatment of Experimental Aneurysms: Feasibility of Embolization without Protection Devices at the Neck

Jean Raymond, Igor Salazkin, Annick Metcalfe, François Guilbert, Alain Weill, and Daniel Roy

BACKGROUND AND PURPOSE: Coiling of intracranial aneurysms is both safe and effective but may be followed by recurrences. The purpose of this study was to assess the feasibility of endovascular treatment of aneurysms with high-concentration ethylene-vinyl alcohol copolymer (HCEVOH), without the use of protection devices at the neck.

METHODS: Wide-necked bifurcation aneurysms with a high propensity for recurrences were constructed in 22 dogs. HCEVOH embolization was performed with a dedicated high-pressure microcatheter in 12 animals. Angiographic results at 3 and 12 weeks and pathologic results at 12 weeks were compared with those of a separate group of 10 animals treated with platinum coils. We used a qualitative scoring system to grade angiographic results, neointima formation, and recanalization at the neck.

RESULTS: Intraaneurysmal HCEVOH injections could be performed without carotid emboli and without a protection device in 11 of 12 animals. Fragments detached upon traction of the microcatheters at the end of the procedure on two occasions. Immediate and late angiographic results were not significantly different between the two groups ($P = .807$), with a tendency for angiographic recurrences at 3 months (angiographic scores were significantly worse in both groups at 12 weeks as compared with T0 [$P < .02$]). A complete occlusion, including the neck, even at the cost of protrusion of material at the level of the branches, is necessary to decrease risks of recurrences. Neointima formation at the surface of the embolic agent was complete at the neck of aneurysms treated with HCEVOH. The neointimal score was significantly improved with HCEVOH as compared with coil embolization ($P = .03$).

CONCLUSION: HCEVOH embolization of aneurysms without neck protection is feasible. It does not, however, eliminate recurrences in an experimental wide-necked aneurysm model.

Endovascular treatment of acutely ruptured aneurysms with platinum coils is both safe and effective and can improve the outcome of patients with subarachnoid hemorrhage as compared with surgery (1–3). Angiographic recurrences, however, are more frequent after coil embolization than after surgical

clipping (4–6). Among strategies designed to improve long-term results of endovascular treatment, the use of liquid polymers has shown some promise (7). Cyanoacrylates have never gained wide acceptance in aneurysms, mainly because of the risks of cerebral infarction from uncontrolled escape of the polymers during deposition (7). Adjunct methods designed to improve delivery and decrease risks of parent artery embolization during treatment with liquid polymers have included balloon-assisted techniques and deposition under the protection of stents, coils, or aneurysmal neck-bridge devices. These methods are, at best, suboptimal (7–11). Ethylene-vinyl alcohol (EVOH), or Onyx [Micro Therapeutics, Inc., Irvine, CA], deposited under the protection of a balloon expandable stent, has recently been proposed for the treatment of difficult aneurysms (10). Poor or insuf-

Received March 25, 2003; accepted May 11.

From the Department of Radiology (J.R., F.G., A.W., D.R.), Centre Hospitalier de l'Université de Montréal (CHUM), Notre-Dame Hospital, and the Interventional Neuroradiology Research Laboratory, Research Center of CHUM (J.R., I.S., A.M.), Montreal, Quebec, Canada.

Address correspondence and reprint requests to Jean Raymond, MD, Interventional Neuroradiology Laboratory, CHUM Research Center, Notre-Dame Hospital, 1560 Sherbrooke East, Suite M-8203, Montreal, Quebec, Canada, H2 L 4M1.

© American Society of Neuroradiology

ficient control of delivery, despite the use of neck protection devices, however, has been observed in experimental models (11). Increasing concentration and viscosity may allow the injection of a cohesive mass of EVOH even in high-flow situations and without the use of protection devices. The use of liquid embolic materials that may more completely fill aneurysms could improve long-term results of endovascular treatment.

We tested these hypotheses in a wide-necked bifurcation aneurysm model with a high propensity for recurrences (8). We wanted to assess the feasibility of this approach, as well as compare angiographic and pathologic results of wide-necked aneurysms treated with high-concentration ethylene-vinyl alcohol copolymer (HCEVOH) with the results of platinum coil embolization.

Methods

Aneurysm Construction

Protocols for animal experimentation were approved by the institutional animal committee in accordance with guidelines of the Canadian Council on Animal Care. Surgical and endovascular procedures were performed under general anesthesia. Twenty-two beagles weighing 10–15 kg were sedated with an intramuscular injection of acepromazine (0.1 mg/kg), glycopyrrolate (0.01 mg/kg), and butorphanol (0.1 mg/kg) and anesthetized with intravenous thiopental (15 mg/kg). Animals were ventilated artificially and maintained under surgical anesthesia with 2% isoflurane. Postoperative anesthesia was provided for 3 days by a 50- μ g Fentanyl skin patch. Wide-necked venous pouch aneurysms were constructed by using a previously described technique (8). In brief, the left common carotid artery was ligated near its origin, transected, and the distal end was mobilized and tunneled to the contralateral side to construct a Y-type bifurcation. After ligation, a 2-cm segment of the left external jugular vein was prepared for the anastomosis. Two longitudinal, partial lateral incisions were made on the venous segment to anastomose it to the arteriotomies on the medial aspects of both carotid arteries. In this model, the “anatomical neck” of the aneurysm, consisting of the wall of the venous segment, is wide and devoid of suture lines, while “the surgical neck” forms a “dysplastic bifurcation,” which incorporates the origin of the left carotid artery (8). Bifurcation aneurysms were 14 mm in size with 7–8-mm necks. Transfemoral angiography was undertaken immediately after surgery in all animals. During recovery, the dogs were fed a normal diet, and their activities were not restricted.

Endovascular Treatment

Endovascular treatment was performed by transfemoral techniques employed routinely in clinical practice at least 2 weeks after aneurysm construction. The room was equipped with a single plane C-arm fluoroscopic unit without subtraction or road-mapping possibilities.

In a first group of 10 animals, coil embolization was performed by maximal packing with 0.015-inch diameter platinum coils (Target Therapeutics, Fremont, CA) of decreasing diameters until coils could no longer be introduced. Sometimes embolization had to be interrupted to avoid coil protrusion into the parent artery and stenosis of the left carotid artery.

In a second group of 12 animals, HCEVOH was used for embolization. This material consists of EVOH in dimethyl sulfoxide (DMSO). It is similar to the one used for embolization of arteriovenous malformations (Onyx 18; Micro Therapeutics, Inc., Irvine, CA), but with higher concentrations of

EVOH (Onyx 2500; Micro Therapeutics, Inc.) and tantalum powder (42% DMSO, 47% tantalum and 11% EVOH w/w). High-pressure microcatheters (Titan), syringes, and HCEVOH were provided by Micro Therapeutics. In brief, the microcatheter was positioned in the distal third of the aneurysmal sac. It was slowly rinsed with 0.4 mL of DMSO and loaded with HCEVOH, up to the marker 3 cm proximal to the catheter tip. A 1-mL syringe, specially designed for HCEVOH injections, was equipped with a screw-type metallic plunger and a clip for immediate pressure release. The material was then injected very slowly to form a 1–3-mm kernel, outside but still attached to the microcatheter tip. The injection was stopped to permit DMSO diffusion and EVOH precipitation. The HCEVOH mass was progressively enlarged by series of slow injections (0.1 mL/min) and curing periods, until complete or near-complete occlusion of the aneurysms. In five animals, the goal of the interventionist was to occlude the aneurysm without any protrusion of material into the parent vessel, while in seven animals some protrusion was accepted in an effort to fully occlude the neck of aneurysms. In one case, we attempted to exclude a residual neck by using injections through a second microcatheter close to the bifurcation. Microcatheters were retrieved by sudden traction 5–10 minutes after final angiography.

Data Analysis

Angiographic evaluation and scoring. Carotid angiography was performed in anesthetized animals immediately after embolization, at 3 weeks, and at 3 months before euthanasia by barbiturate overdose, to document the degree of aneurysmal obliteration. Multiple projections were evaluated, and the results were scored by the same observer (J.R.) according to a previously described classification scheme (8). A score of 0 indicated complete obliteration; 1, “dog ears”; 2, residual or recurrent neck; and 3, residual or recurrent aneurysm. A score of 4 was added for large saccular recurrences.

Macroscopic photography, neointimal scores, and pathology. The carotid arterial wall was longitudinally opened to expose the luminal surface of the neck of aneurysms. After fixation, the necks of aneurysms were photographed by using an operating microscope. Morphologic results at the neck of treated aneurysms were graded according to a previously described classification system, taking into consideration neointima formation and recanalization (8). In brief, neointima formation was labeled score 0 when a thick neointima completely sealed the orifice of the aneurysmal neck; score 1 when the neointima was similarly sealing the neck, but small areas of recanalization were seen adjacent to the transition between the neck and the wall of the aneurysm; score 2 when a crescent of recanalization was present around the neointima covering the coil mass or the embolic agent; score 3 when the neointimal covering was only partial; and score 4 when no neointima, only thrombus, was covering most of the embolic material or coil mass. Pathologic specimens were studied after formalin fixation, axial sectioning, and staining as described elsewhere (7).

Statistics

Angiographic and neointimal scores were compared by using Wilcoxon signed ranks tests and Kruskal-Wallis tests when appropriate.

Results

Complications and angiographic and neointimal scores for each group are summarized in the Table.

Endovascular Procedures and Angiographic Results

Embolization with platinum coils. Mean dimensions of aneurysms treated with coils were 14.0 ± 2.1 mm

Treatment groups and results

	n	Protrusion	Median Angiographic Scores			Median Neointimal Scores
			T ₀	T _{3 weeks}	T _{12 weeks}	
Platinum coils	10	4	0	3	3	3
HCEVOH	12	7	0	2	3 ^a	2 ^b

a: $P = .807$; b: $P = .3$

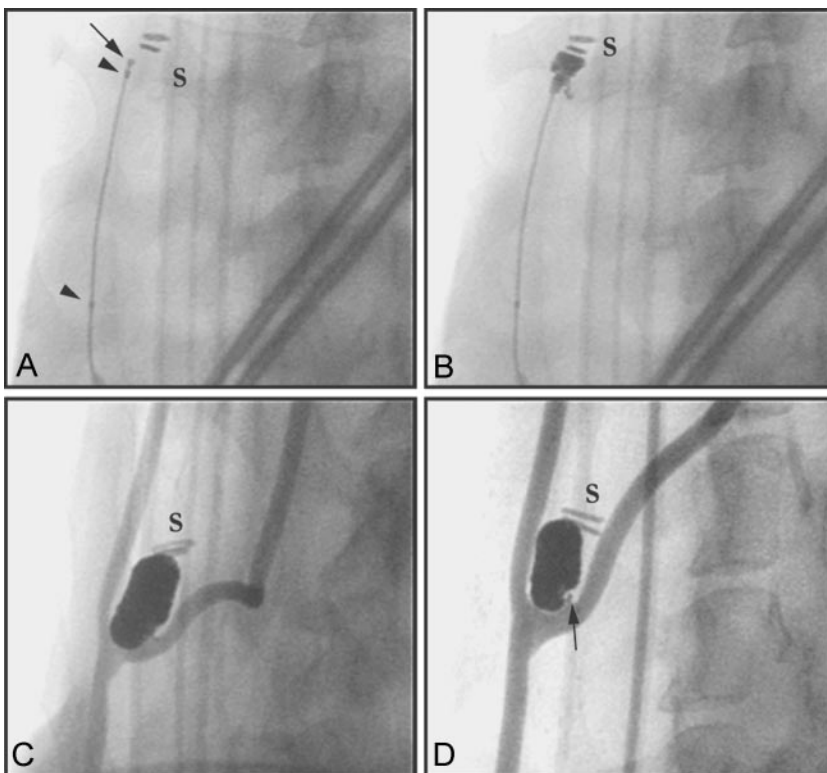
with 8.3 ± 1.2 mm necks. The first coil was difficult to position without protrusion in the bifurcation and necessitated multiple attempts at repositioning to respect the origin of the left carotid artery. Treatment was possible in all cases, but coiling was sometimes incomplete to prevent left carotid occlusion. Coil protrusion into the bifurcation but without complication occurred in four of 10 aneurysms. Total length of platinum coils deployed into aneurysms averaged 124 ± 27 cm for a mean packing density of $23 \pm 6\%$. There was a progressive increase in the angiographic scores with time, so that the 3-month follow-up scores were significantly different from scores at T₀ ($P = .017$) showing a recurrence in seven of 10 animals and a median angiographic score of 3.

Embolization with HCEVOH. Mean dimensions of aneurysms treated with HCEVOH were 14.1 ± 3.0 mm with 7.0 ± 1.4 mm necks. There was no complication from the use of DMSO. Performance of the dedicated microcatheter and visibility of the material under fluoroscopy were excellent (Fig 1). The initial injection of HCEVOH was well controlled with the formation of a small kernel of material at the catheter tip in 11 of 12 animals (Fig 1A). In one case, the

material formed a string that was carried by blood flow into the left carotid artery, an event that was associated with a defective pressure release mechanism of the syringe (Fig 2A). The HCEVOH mass, when smaller than the aneurysm, was stable and attached to the catheter, so that it could be moved freely within the lesion. Lesions were occluded with a mean of 0.53 ± 0.45 mL of HCEVOH when aneurysms were assimilated to cylinders, this corresponded to a packing density of $83 \pm 45\%$. Attempts at completely occluding the sac and neck of aneurysms were typically associated with protrusion (seven animals), into branches of the bifurcation, of finger-like projections of material still attached to the main HCEVOH mass (Fig 1). On two occasions, protrusions were larger than necessary because they were not noted immediately owing to the lack of biplane imaging and subtraction (Fig 2B and C). There was no fragmentation of this material, and there were no delayed neurologic events during the follow-up period. Catheter retrieval was uneventful in 10 animals; in one case, in which we used a second microcatheter to form a second HCEVOH mass to fully occlude a residual neck, the fragment of material still attached to the tip of the catheter was pulled during traction and was dropped at the femoral puncture site, without complication (Fig 2D). In another case, a small fragment of polymer detached and embolized into the maxillary artery on catheter retrieval. There was a progressive increase in the angiographic scores with time, so the 3-month follow-up scores were significantly different from scores at T₀ ($P = .008$) showing a recurrence in nine (75%) of 12 animals and a

Fig 1. HCEVOH embolization of aneurysms

Selected frames from angiographic monitoring of endovascular intervention show initial kernel formation (arrow, A), progressive enlargement of HCEVOH mass (B), final (C), and follow-up angiographic results at 3 months (D). Arrowheads in panel A indicate metallic markers on microcatheter. S indicates surgical clips at fundus of aneurysm. Note minimal neck remnant (arrow, D).



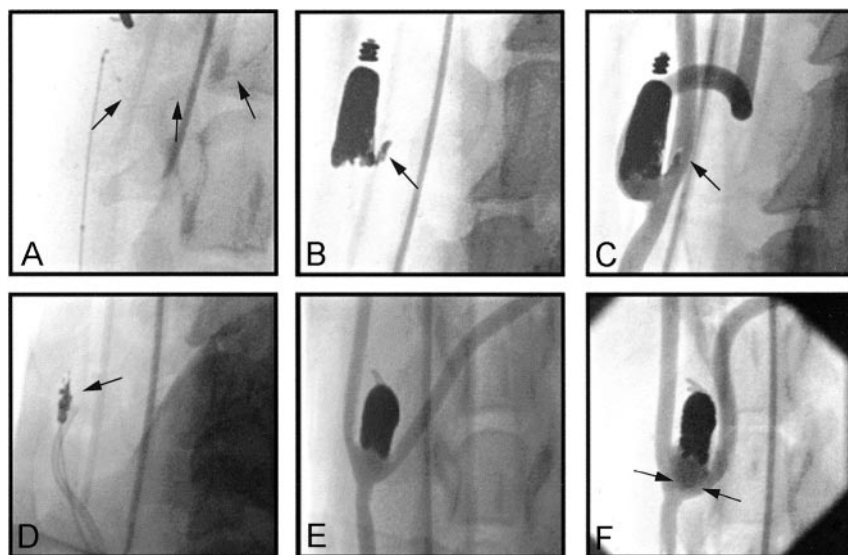


FIG 2. Complication and recurrence with HCEVOH embolization

Selected frames from angiographic monitoring of procedure showing (A) stringing of HCEVOH and carotid embolization (arrows), excess HCEVOH protrusion (B, C), tearing of attached material (arrow, C) on catheter retrieval (D), and recurrence 3 months (arrows, F) after satisfactory occlusion of bifurcation aneurysm (E). The apparent residuum in panel E consists mostly of the bifurcation itself surgically constructed to obtain this morphology associated with a high incidence of recurrence (9).

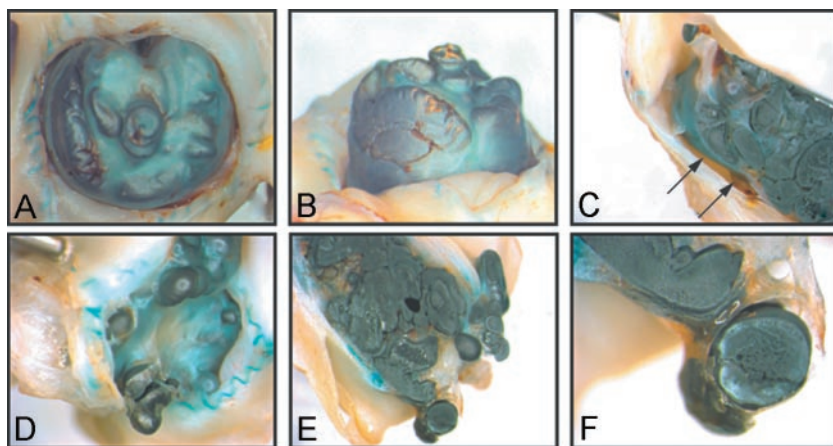


FIG 3. Macroscopic observations after HCEVOH embolization

Photography of specimens 3 months after embolization showing recurrence (A–C) or excess protrusion (D–F). Note complete neointima formation over HCEVOH (F) and recanalizing crescents in an example of recurrence (arrows, C).

median angiographic score of 3 (Fig 2E and F). There was no significant difference between overall angiographic results of aneurysms treated with HCEVOH or platinum coils ($P = .807$). When aneurysms were fully occluded with HCEVOH the angiographic scores at 12 weeks were significantly better than results obtained with coiling ($P = .036$).

Pathologic Results

Stereo photography of the neck of aneurysms embolized with platinum coils have been published previously (8). In brief, they showed incomplete closure of the neck, with obvious recurrences in most specimens. Each platinum filament was covered with neointimal tissue that could be very thin, to the point that coils sometimes seemed to be bare, especially when coil loops were protruding in the high flow area of the neck. In many cases, minute clots could be found at the surface of coils, but rarely was the neck occupied by unorganized clot (one specimen). The median neointimal score of aneurysms treated with platinum coils was 3.

Histopathologic sections constantly showed neointimal tissue, although sometimes it was very thin. In other areas the neointima was much thicker and continuous

with the richly vascularized fibrocellular tissue replacing the spaces between coils deeper inside the coil mass. Foreign body giant cells could be found at the surface of many platinum loops. Recanalizing crescents were frequent and always bordered by neointimal tissue.

By comparison, the neointimal coverage of aneurysms treated with HCEVOH was more complete (Figs 3, 4, 5). The median neointimal score was 2, a significant difference with the one found in aneurysms treated with coils ($P = .03$). The neointima was barely visible at the surface of the polymer where it was protruding into the bifurcation or at the origin of a branch, again presumably areas of high blood flow (Figs 3 and 4). In some specimens, the neointima showed irregular plaques covered with small adherent clots. In other areas, protruding blebs of polymer were bridged with thick neointima (Fig 5A and B). Areas of recanalization were less frequently found than in aneurysms treated with platinum coils. The most striking histopathologic difference was found inside the aneurysmal sac, which was almost completely filled with polymer (Fig 5A). There were long but thin layers of richly vascularized fibrocellular tissue, of a similar nature to the one found within the coil mass, septating the core of the polymeric mass with connec-

FIG 4. Neointima formation over HCEVOH

Macroscopic photography (A, C) and corresponding histopathologic sections (B, D) of neointima formation over HCEVOH at the neck of the aneurysm (A, B) or over an example of protrusion in the carotid artery (C, D). (B, D: Movat's pentachrome stain; original magnification $\times 200$).

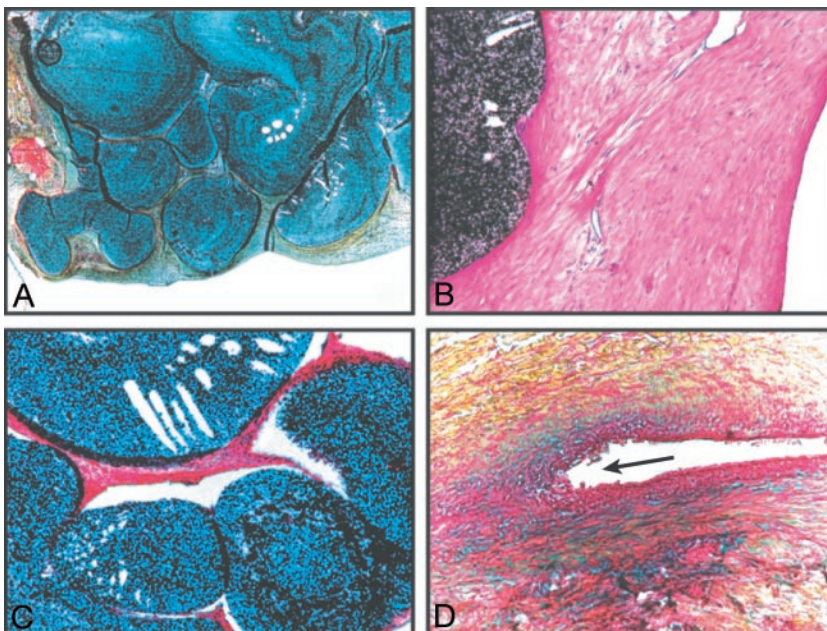
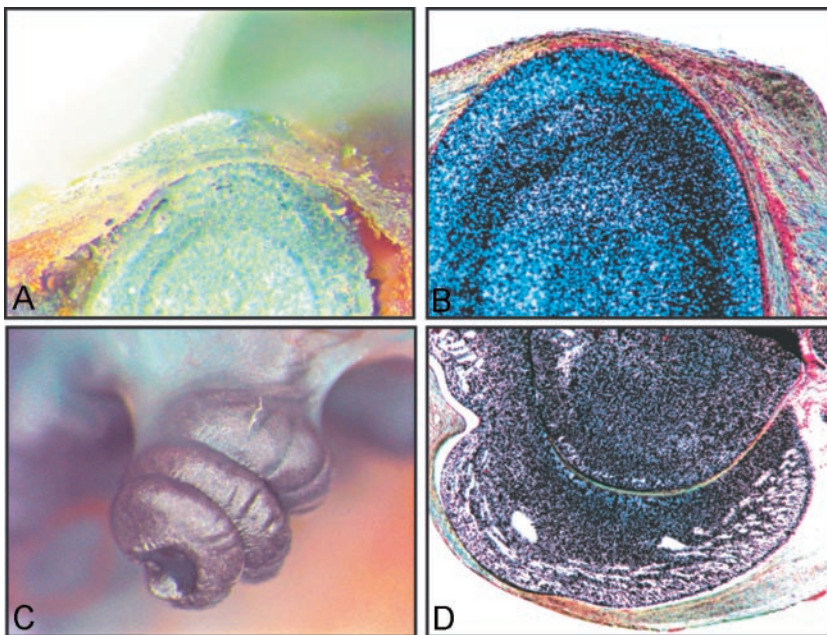


FIG 5. Pathologic findings 3 months after HCEVOH embolization

Note complete replacement of aneurysmal sac with HCEVOH (A) and excellent neointima formation at the neck (B). Some tissue septations can be found within HCEVOH mass (C). A recanalizing crescent related to recurrence is shown in panel D (arrow). (A, D: Movat's pentachrome stain; B, C: Hematoxylin Phloxin Saffron (HPS) stain; Original magnification: A, $\times 100$; B and D, $\times 400$, C, $\times 200$).

tions to the aneurysmal wall (Fig 5C). Foreign body giant cells and inflammatory cells were rare. Recanalizing crescents could easily be found between the aneurysmal wall and the polymeric mass near the neck in specimens harboring recurrences (Figs 3C and 5D). The surface of the embolic agent at the level of these recanalizing spaces was always covered with neointima.

Discussion

Embolization of experimental aneurysms with HCEVOH without a protection device at the neck is feasible. The technique was easy to reproduce, even at the beginning of these experiments when we were

not familiar with the material. It was surprisingly controlled, when one considers the challenge involved in treating these lesions. In a previous study, where the same model was used to assess the aneurysmal neck-bridge device, complications, suboptimal results, and recurrences were frequent (8). This highly concentrated material permitted to treat aneurysms with a control at least similar to, if not better than, the one obtained with other polymers combined with the use of protection devices, without the added complexity and potential risks of dual catheter techniques, balloons or stents (7–11). Embolization with HCEVOH remains a polymer injection, however, with risks of stray emboli and the intrinsic impossibil-

ity to recapture material that escapes in undesirable locations. As a result, along with other polymeric agents, we believe this material cannot duplicate the security provided by retrievable coils (7–11).

The HCEVOH mass was firm and stable, without fragmentation and delayed emboli that we have witnessed with other polymeric agents in animal models (9).

Although deposition of the material within the aneurysmal sac could be controlled in most cases, we were confronted with a conceptual difficulty once the material reaches the neck. Because HCEVOH was injected without any restrictive device at the neck, the dilemma was to choose either to fully occlude the lesion and accept some protrusion of material into branches or to stop short of complete occlusions. Reconstruction of the parent vessel, as suggested with the stent-EVOH combination, cannot be reliably reproduced in this situation (10). Likewise, stents or balloon-assisted coiling cannot be easily performed with this model. Small projections of HCEVOH into carotid branches were not associated with visible thrombus formation and did not cause delayed neurologic deficits. In that respect, they may behave similarly to platinum loop protrusions that are frequently benign and clinically silent; however, many bifurcation aneurysms arise near perforators that may be jeopardized by these projections. In clinical practice, such a technique would necessitate excellent imaging and understanding of the anatomy of the bifurcation, including three-dimensional angiography for planning and biplane and subtracted fluoroscopy to minimize complications during injections.

Another difficulty relates to the need to retrieve the catheter by traction, with risks of pulling some material out of the aneurysm, an event that occurred twice in these experiments and that could be more frequent in small or shallow aneurysms. A detachable tip microcatheter may be helpful in that regard.

Healing after coil embolization relies on thrombosis and replacement of the clot by connective tissue and neointima formation at the surface of the coil mass (7, 8, 12, 13). Unfortunately, clot is simultaneously subject to recanalization, a process linked to early endothelial invasion that has been associated with the use of a wide variety of embolic agents (14, 15). Thus, recanalization and recurrences are frequent after coil embolization, and this problem can be reproduced at 3 months in canine bifurcation aneurysm models (7, 8, 13, 14). By filling the entire volume of aneurysms with HCEVOH, we hoped to circumvent this recanalization problem; if there is no clot involved, there should be no recanalization. This simplistic approach has been used to explain improved results of cyanoacrylate embolization of experimental aneurysms as compared with coils (7). Recurrences, however, were frequent after selective balloon embolization of aneurysms, even when a polymer was used to fill balloons, and other mechanisms such as the

“water hammer effect” have been evoked to explain recurrences (16, 17).

Our interpretation of macroscopic and microscopic findings of this study, however, is that no matter how completely the aneurysmal volume is replaced with polymer, the final biologic reaction always include some thrombosis, which is then recanalized or converted to neointima, or more likely is simultaneously subjected to both phenomena (14, 18). Recurrences found between the HCEVOH mass and the aneurysmal wall had a similar pathologic appearance to those found around a coil mass filled with fibrous tissue. One important difference with coiling is that recanalization can develop in between coils, whereas the homogeneous nature of the polymeric mass did not permit this event, a factor that largely explains the better neointimal scores found in aneurysms treated with HCEVOH.

When the aneurysm was completely excluded from the circulation, often at the price of some protrusion in the parent vessel or branches, angiographic results were significantly improved at 3 months as compared with coil embolization. This may not be surprising, in light of the fact that completely coiled lesions have good long-term results, as shown in clinical studies (4–6) as well as in experimental models (7). The fact that complete obliteration could be achieved in a difficult wide-necked aneurysm model, however, remains an important gain.

Conclusion

Embolization of aneurysms with HCEVOH is feasible without a protection device at the neck. It remains, in our opinion, less controlled than embolization with detachable coils and as such should not replace coil embolization in current routine practice. Overall angiographic results were not significantly different at 3 months as compared with coil embolization. To gain from this new material and minimize risks of recurrences, lesions must be completely excluded from the circulation, at the expense of increasing risks of protrusion and potential complications.

Acknowledgments

We thank Bill Paterson from Micro Therapeutics, Inc., for expert advices during interventions and Guylaine Gevry for assistance with the preparation of the manuscript and artwork. This work was supported by Micro Therapeutics Inc.

References

1. Molyneux A, Kerr R, Stratton I, et al. **International Subarachnoid Aneurysm Trial (ISAT) Collaborative Group. International Subarachnoid Aneurysm Trial (ISAT) of neurosurgical clipping versus endovascular coiling in 2143 patients with ruptured intracranial aneurysms: a randomised trial.** *Lancet* 2002;360:1267–1274
2. Raymond, J, Roy D. **Safety and efficacy of endovascular treatment of acutely ruptured aneurysms.** *Neurosurgery* 1997;41:1235–1245; discussion 1245–1236
3. Raymond J, Roy D, Bojanowski M, et al. **Endovascular treatment of acutely ruptured and unruptured aneurysms of the basilar bifurcation.** *J Neurosurg* 1997;86:211–219

4. Cognard C, Weill A, Spelle L, et al. **Long-term angiographic follow-up of 169 intracranial berry aneurysms occluded with detachable coils.** *Radiology* 1999;212:348–356
5. Raymond J, Guilbert F, Weill A, et al. **Long-term angiographic recurrences after selective endovascular treatment of aneurysms with detachable coils.** *Stroke* 34:1398–1403
6. Hayakawa M, Murayama Y, Duckwiler GR, et al. **Natural history of the neck remnant of a cerebral aneurysm treated with the Guglielmi detachable coil system.** *J Neurosurg* 2000;93:561–568
7. Raymond J, Berthelet F, Desfaits AC, et al. **Cyanoacrylate embolization of experimental aneurysms** *AJNR Am J Neuroradiol* 2002; 23:1–10
8. Raymond J, Salazkin I, Georganos SA, et al. **Endovascular treatment of wide-necked experimental aneurysms: a comparison of results using coils or cyanoacrylate with the assistance of an aneurysm neck-bridge device.** *AJNR Am J Neuroradiol* 2002;23:1710–1716
9. Raymond J, Metcalfe A, Desfaits AC, et al. **Alginate for endovascular treatment of aneurysms and local growth factor delivery.** *AJNR Am J Neuroradiol* 24:1214–1221
10. Mawad ME, Cekirge S, Ciceri E, Saatci I. **Endovascular treatment of giant and large intracranial aneurysms by using a combination of stent placement and liquid polymer injection.** *J Neurosurg* 2002; 96:474–482
11. Murayama Y, Vinuela F, Tateshima S, et al. **Endovascular treatment of experimental aneurysms by use of a combination of liquid embolic agents and protective devices.** *AJNR Am J Neuroradiol* 2000;21:1726–1735
12. Bavinsky G, Talazoglu V, Killer M. **Microscopic histopathological findings in aneurysms of the human brain treated with Guglielmi detachable coils.** *J Neurosurg* 1999;91:284–293
13. Raymond J, Venne D, Allas S, et al. **Healing mechanisms in experimental aneurysms. I. Vascular smooth muscle cells and neointima formation.** *J Neuroradiol* 1999;26:7–20
14. Raymond J, Leblanc P, Desfaits A-C, et al. **In situ beta radiation to prevent recanalization after coil embolization of cerebral aneurysms.** *Stroke* 2002;33:421–427
15. Schweitzer JS, Chang BS, Madsen P, et al. **The pathology of arteriovenous malformations of the brain treated by embolotherapy. II. Results of embolization with multiple agents.** *Neuroradiology* 1993; 35:468–474
16. Higashida RT, Halbach VV, Barnwell SL, et al. **Treatment of intracranial aneurysms with preservation of the parent vessel: results of percutaneous balloon embolization in 84 patients.** *AJNR Am J Neuroradiol* 1990;11:633–640
17. Heilman CB, Kwan ES, Wu JK. **Aneurysm recurrences following endovascular balloon occlusion.** *J Neurosurg* 1992;77:260–264
18. Raymond J, Sauvageau E, Salazkin I, et al. **Role of the endothelial lining in persistence of residual lesions and growth of recurrences after endovascular treatment of experimental aneurysms.** *Stroke* 2002;33:850–855