



Get Clarity On Generics

Cost-Effective CT & MRI Contrast Agents



FRESENIUS
KABI

WATCH VIDEO

AJNR

Contrast Enhancement of a Hyperacute Spontaneous Spinal Epidural Hematoma

Hiroshi Nawashiro and Reiko Higo

AJNR Am J Neuroradiol 2001, 22 (7) 1445

<http://www.ajnr.org/content/22/7/1445>

This information is current as
of August 29, 2025.

Contrast Enhancement of a Hyperacute Spontaneous Spinal Epidural Hematoma

Spontaneous spinal epidural hematomas are rare clinical conditions that are sometimes difficult to diagnose. The severity of preoperative neurologic deficits and the interval between the onset of symptoms and surgical decompression mainly determine therapeutic outcome. Thanks to recent advances in MR imaging, acute spinal epidural hematomas with minimal neurologic deficits have been reported to be treatable by means of a non-operative approach (1, 2). Although conservative management, based on frequent monitoring of patient neurologic function and repeated MR imaging, is often successful, it can also put such patients at risk of developing spinal cord damage that may not be reversed by an evacuation of the hematoma. The MR imaging characteristics that can accurately predict which patients can successfully undergo conservative treatment are thus important, as mentioned by Fukui et al (1). We recently encountered a case of hyperacute spontaneous spinal epidural hematoma in a 60-year-old woman who suddenly developed low back pain without any predisposing illness, followed by weakness in both legs. Within several hours, the weakness in her legs progressed to complete paraplegia. Neurologic examinations revealed flaccid paraparesis and a decreased tactile and pain sensation below the L1 dermatomes, with a preservation of deep sensations. She also presented with urinary retention. Spinal MR imaging performed 5 hours after the onset of symptoms revealed a posterior epidural isointense mass on the T1-weighted images and heterogeneous hyperin-

tensity on the T2-weighted images (Fig 1A) at the T9–L1 levels. The center of the cord showed hyperintensity on T2-weighted images (Fig 1A), indicating secondary ischemic changes. After IV contrast material administration, sizeable dotted enhancement was noted in the lower part of the mass (Fig 1B), thus suggesting the extravasation of contrast-enhanced blood. Surgical intervention revealed a pure epidural hematoma without any causative disease. To investigate the underlying disease entity, such as tumor or vascular anomalies associated with spinal epidural hematomas, contrast-enhanced MR images may be useful. Furthermore, a sizeable enhancement in the hyperacute stage of the hematoma itself might indicate continuing bleeding. Taking the above MR findings into consideration, together with clinical neurologic conditions, it is therefore possible to predict the need for surgical intervention of hyperacute spinal epidural hematomas.

Hiroshi Nawashiro, MD, DMSC

Reiko Higo, MD

Department of Neurosurgery

National Defense Medical College

Tokorozawa, Saitama 359-8513 Japan

References

1. Fukui MB, Swarnkar AS, Williams RL. **Acute spontaneous spinal epidural hematomas.** *AJNR Am J Neuroradiol* 1999;20:1365–1372
2. Holtås S, Heiling M, Lønftoft M. **Spontaneous spinal epidural hematoma. Findings at MR imaging and clinical correlation.** *Radiology* 1996;199:409–413

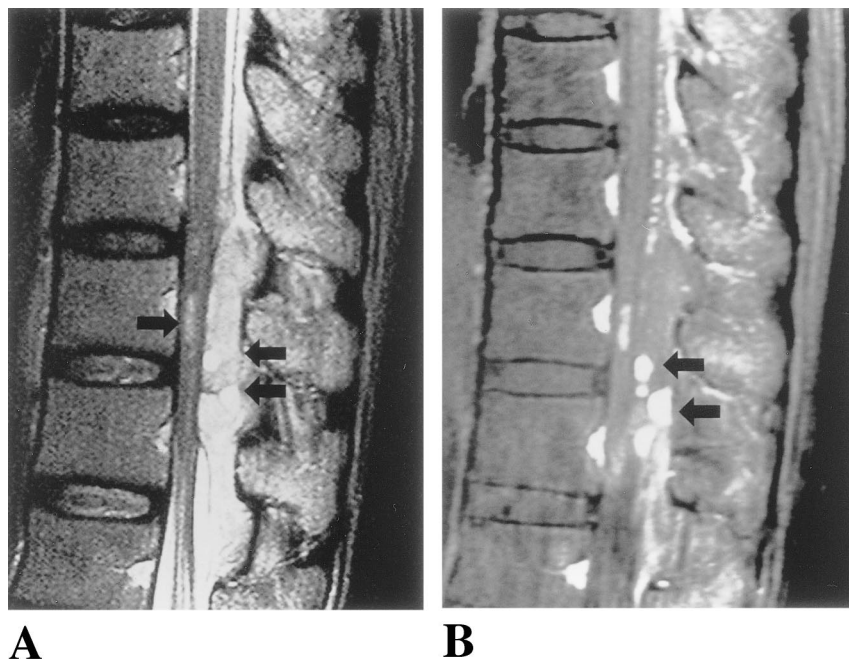


FIG 1. A, Sagittal T2-weighted image, obtained 5 hours after the onset of symptoms, showing an inhomogeneous epidural mass (double arrow) compressing the spinal cord. In the center of the spinal cord, slit-like hyperintensity (arrow) is noted.

B, A sagittal contrast-enhanced T1-weighted image showing a sizeable dotted enhancement (double arrows) in the epidural mass.

Corrections/Clarifications

In the June 2000 issue the name Manzia was misspelled. The correct citation is: Matsubara S, Mandzia JL, ter Brugge K, Willinsky RA, Faughnan ME. **Angiographic and clinical characteristics of patients with cerebral arteriovenous malformations associated with hereditary hemorrhagic telangiectasia.** *AJNR Am Neuroradiol* 21: 1016–1020.

In the April 2001 issue the name incorrectly appeared as Valérie Ickowitz on the article *Prenatal Diagnosis and Postnatal Follow-up of Pericallosal Lipoma: Report of Seven New Cases*. The correct name is Valentine Ickowitz.