



Get Clarity On Generics

Cost-Effective CT & MRI Contrast Agents

**FRESENIUS
KABI**

[WATCH VIDEO](#)

AJNR

Assessment of Silent Embolism from Carotid Endarterectomy by Use of Diffusion-weighted Imaging: Work in Progress

Kirsten P.N. Forbes, Holly A. Shill, Peter M. Britt, Joseph M. Zabramski, Robert F. Spetzler and Joseph E. Heiserman

This information is current as
of August 20, 2025.

AJNR Am J Neuroradiol 2001, 22 (4) 650-653
<http://www.ajnr.org/content/22/4/650>

Assessment of Silent Embolism from Carotid Endarterectomy by Use of Diffusion-weighted Imaging: Work in Progress

Kirsten P.N. Forbes, Holly A. Shill, Peter M. Britt, Joseph M. Zabramski, Robert F. Spetzler, and Joseph E. Heiserman

BACKGROUND AND PURPOSE: Transcranial Doppler studies have suggested that micro-emboli are released into the arterial circulation during the majority of carotid endarterectomy (CEA) procedures. This, together with the observation that neuropsychological performance may decline postoperatively, has led to concern that cerebral infarction may occur unrecognized during CEA. Our objective was to examine this risk with diffusion-weighted imaging, a technique that is highly sensitive to acute cerebral infarction.

METHODS: Eighteen participants (median age, 68 years; age range, 56–87 years) were assessed with diffusion-weighted imaging and the National Institutes of Health Stroke Scale before and after CEA. Imaging was performed using single-shot echo-planar imaging with a maximum diffusion sensitivity of $b = 1000 \text{ s/mm}^2$ applied to three orthogonal planes. Preoperative imaging was performed a median of 2.5 hours before surgery (range, 0.5–12.5 hours) and 15 hours after surgery (range, 1.5–58.5 hours). Two neuroradiologists independently interpreted the diffusion-weighted images, blinded to operative status and clinical findings.

RESULTS: There was no diffusion-weighted imaging evidence of silent embolism in this series of 18 participants (95% confidence interval limits, 0 to 10%). Clinical complications were confined to one case of confusion occurring after CEA; the diffusion-weighted imaging results were normal in this case.

CONCLUSION: There is no evidence from our series that silent cerebral infarction is a common occurrence during CEA. These data provide further support for the safety of CEA.

Although carotid endarterectomy (CEA) is performed to try to decrease the risk of subsequent stroke, the procedure itself may cause neurologic deficit. Multicenter CEA trials have clinically assessed the risk of major stroke or death from surgery and have found it to be low: a risk of 5.8% in symptomatic and 2.3% in asymptomatic carotid stenosis (2.5% and 1.9% when corrected for non-surgical risk) (1, 2). These figures have been used

to determine which subgroups of patients with carotid stenosis might potentially benefit from CEA. Does the clinical detection of a postoperative neurologic deficit provide a sensitive measure of perioperative cerebral ischemia? Transcranial Doppler sonography suggests that cerebral embolism occurs during the majority of CEA procedures (3–5). Although only a minority of emboli cause neurologic deficits detected by routine examination, others may cause subtle declines in neuropsychological performance (6) or clinically silent infarction revealed by imaging of the brain (7, 8).

Diffusion-weighted imaging provides a highly sensitive tool for detecting cerebral infarction (9). We chose to use this technique to assess the risk of asymptomatic infarction from CEA. Since beginning recruitment, a study of similar design has reported its findings (10). We elected to publish our results sooner than planned on the basis of the marked differences between our results and those of that study.

Methods

Participants

After obtaining informed consent from the participants and approval from the institution's review board, we prospectively

This work was presented as an oral presentation at the 38th Annual Meeting of the American Society of Neuroradiologists, Atlanta, April 2000.

This work was supported in part by the Kodak Radiology Fund Bursary, Royal College of Radiologists, England (to K.P.N.F.).

Address reprint requests to Joseph E. Heiserman, MD, PhD, Division of Neuroradiology, Barrow Neurological Institute, St. Joseph's Hospital and Medical Center, 350 West Thomas Road, Phoenix, AZ 85013.

Preoperative carotid artery imaging

	Subjects (No.)
Ipsilateral Carotid Artery	
Severe carotid stenosis (>70%)	16
Moderate carotid stenosis (50–70%)	2
Plaque ulceration	1
Contralateral Carotid Artery	
Carotid stenosis	
Mild	2
Moderate	3
Severe	3
Occlusion	1
Prior CEA	2

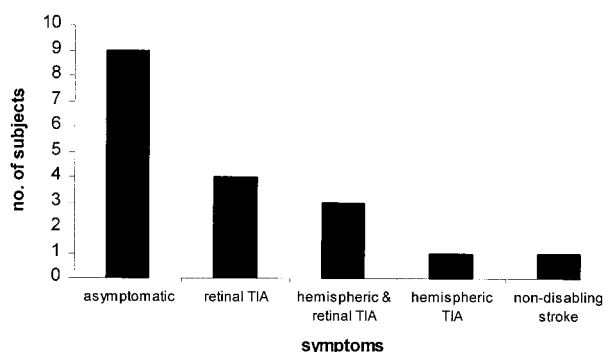


FIG 1. Bar chart depicts the symptomatic presentation of the participants.

studied 18 participants (12 male and six female participants) who were undergoing CEA (median age, 68 years; age range, 56–87 years). Carotid stenosis was diagnosed using North American Symptomatic Carotid Endarterectomy Trial criteria for digital subtraction cerebral angiography in seven participants and concordant Doppler sonography and MR angiography (2D time-of-flight) in the remainder. The imaging findings are detailed in the Table.

In nine participants, carotid stenosis was symptomatic (Fig 1). Participants were excluded from the study if ischemic symptoms occurred during the 14 days before CEA. Multiple atherosclerotic risk factors were reported (hypertension, 14 participants; smoking history, 12 participants; hyperlipidemia, 10 participants; diabetes mellitus, five participants).

Surgical Technique

CEA was performed with the participants under general endotracheal anesthesia, with continuous EEG monitoring, by one of two experienced neurosurgeons (J.M.Z., R.F.S.) (11). After vascular exposure, thiopental barbiturates were IV administered in addition to a heparin bolus. When effective thiopental EEG burst suppression was achieved, carotid vessels were clamped. After arteriotomy, atherosclerotic plaque was removed under operative microscope guidance. Arteries were back bled and flushed with heparinized saline before closure. Vascular shunting was performed in one participant who had a tandem stenosis of the intracranial middle cerebral artery and poor collateral vasculature. No participant showed a major intraoperative EEG change. In one participant with near occlusion of the internal carotid artery, operative appearances prompted an internal carotid stumpectomy.

Clinical Assessment

National Institutes of Health (NIH) Stroke Scale (12) scores were obtained both pre- and postoperatively (within 24 hours) for 14 participants by a neurologist not involved in their routine care. For the remaining four participants, routine pre- and postoperative neurologic assessment was conducted by the operating neurosurgeon.

Diffusion-weighted Imaging

Preoperative diffusion-weighted imaging was performed as close to surgery as possible (median, 2.5 hours; range, 0.5–12.5 hours), with postoperative diffusion-weighted imaging performed a median of 15 hours after surgery (range, 1.5–58.5 hours). Imaging was performed at 1.5 T (General Electric, Milwaukee, WI), using a single-shot echo-planar spin-echo technique. A maximum diffusion sensitivity of $b = 1000 \text{ s/mm}^2$ was applied to three orthogonal planes. Axial images were obtained at 20 levels, both with and without the diffusion gradient (6500/101/1 [TR/TE/excitations]; section thickness, 5 mm; intersection gap, 2.5 mm; field of view, 32 cm; matrix, 128×128). Two radiologists (J.E.H., K.P.N.F.) independently interpreted the images, blinded to operative status and detailed clinical findings. Both isotropic and anisotropic diffusion-weighted images were examined for areas of signal hyperintensity suggesting ischemic damage.

Statistical Analysis

A Bayesian estimate with a noninformative beta was used to establish an upper bound for the incidence of an event with zero occurrences in a study sample (13). Interobserver variability was determined by the kappa statistic (14). Fisher's exact test was used to examine for a difference between our findings and those presented by Muller et al (10). Confidence interval limits were derived using standard statistical methods.

Results*Clinical Assessment*

Preoperatively, 17 participants had normal results of their neurologic examinations (13 were assessed by using the NIH Stroke Scale, and four were assessed by neurosurgical examination). One participant had an NIH Stroke Scale score of 6, reflecting a hemiparesis on the contralateral side.

Only one participant showed a neurologic change after surgery, with an increase in NIH Stroke Scale score from 0 to 1. This was caused by mild postoperative confusion and clinically was attributed to a urinary tract infection causing mild metabolic derangement. Diffusion-weighted imaging results were normal for this participant.

Diffusion-weighted Imaging

Preoperatively, one participant showed middle cerebral artery territory diffusion-weighted imaging hyperintensity in the hemisphere contralateral to the side of surgery. This was compatible with a history of recent hemiparesis and an NIH Stroke Scale score of 6. The hemisphere ipsilateral to the side of CEA was normal. In another participant, one third of the ipsilateral cerebral hemisphere was obscured by susceptibility artifact from an aneurysm clip, limiting interpretation. The remaining 16

preoperative diffusion-weighted images were entirely normal. Postoperatively, no new areas of diffusion hyperintensity were identified in any participant by either of the two observers (kappa value: 1.00).

Discussion

Our findings suggest that CEA is a safe operation carrying a low risk of clinically silent cerebral infarction. Our sample size to date enables us to calculate this risk as <10% in all participants and as <18% in participants with symptomatic carotid stenosis ($P < .05$) (13). Efficacy of CEA in stroke prevention depends on a low rate of perioperative stroke and death (1, 2). We were therefore encouraged by our results, which do not suggest a high incidence of additional unrecognized ischemic complications resulting from CEA.

Our findings are markedly different from those presented by Muller et al (10), who observed multiple diffusion-weighted imaging hyperintensities in one third of their study participants after CEA. Their sample size enabled us to calculate the risk of diffusion-weighted imaging hyperintensity after CEA as being between 23% and 45% ($P < .05$). Comparison by statistical means revealed a significant difference between our findings (0% incidence: 95% confidence interval limits, 0–12%) and the findings presented by Muller et al (33% incidence: 95% confidence interval limits, 23–45%) ($P < .002$, Fisher's exact test).

Can this difference be explained by study design? Both studies contained similar numbers of symptomatic and asymptomatic participants, with similar degrees of carotid stenosis. In both, diffusion-weighted imaging was performed using a single-shot echo-planar spin-echo sequence and similar diffusion gradients. Muller et al (10) did not include preoperative diffusion-weighted imaging in their protocol. This makes it possible that some postoperative diffusion hyperintensities reflected preexisting cerebral infarction. However, none of their participants suffered ischemic symptoms during the 14 days before CEA, making this unlikely to be the sole explanation. Postoperative imaging was performed during the same time window for both studies.

Diffusion-weighted imaging has proved to be far more sensitive to acute cerebral infarction than either CT or conventional MR imaging (15, 16). Ischemic complications associated with CEA include both focal and global cerebral infarction, and diffusion-weighted imaging is well suited to detect both (17, 18). The high signal-to-background contrast seen in cases of cerebral infarction allows us to accurately detect lesions that are $>30 \text{ mm}^3$ with our protocol. Our sensitivity for detecting very small lesions is, however, limited by pixel size and intersection gap. Although diffusion-weighted imaging can detect parenchymal changes in humans within 40 minutes of severe ischemia (19), signal

intensity and lesion size gradually increase during the subsequent 1 to 2 days (20, 21). To maximize diffusion-weighted imaging sensitivity to cerebral infarction, we chose to perform postoperative imaging during this time window. By doing so, it is possible that we missed transient diffusion hyperintensities of uncertain significance during the intervening hours (22).

It is important for us to consider whether the disparity in results between this study and the study conducted by Muller et al (10) can be explained by differences in surgical technique. We used barbiturates during carotid clamping, to limit ischemia, and an operative microscope, to aid in the removal of atherosclerotic debris from the arterial wall before closure. Muller et al did not report use of either of these techniques, preferring vascular shunting to limit cerebral ischemia. If differences in surgical technique are important in determining perioperative ischemic complications, we would expect both the postoperative diffusion findings and the rate of clinically detectable stroke to be affected. Although the report of four persistent neurologic deficits (5.2%) presented by Muller et al falls within the accepted range of perioperative morbidity resulting from CEA (23), it is considerably higher than our own complication rate of 2.5%, derived from a review of 629 CEA procedures (24). Neither figure corrects for the nonsurgical risk of stroke or death.

To achieve the benefits of CEA described by recent multicenter trials (1, 2), low complication rates are paramount. Diffusion-weighted imaging is more sensitive to perioperative cerebral infarction than is clinical assessment (10), and it provides an ideal method for the audit of cerebrovascular procedures.

Conclusion

With this study, we show that diffusion-weighted imaging is a feasible method for detecting perioperative cerebral infarction and that this complication is rare during CEA performed at our center.

References

1. North American Symptomatic Carotid Endarterectomy Trial Collaborators. **Beneficial effect of carotid endarterectomy in symptomatic patients with high-grade carotid stenosis.** *N Engl J Med* 1991;325:445–453
2. Executive Committee for the Asymptomatic Carotid Atherosclerosis Study. **Endarterectomy for asymptomatic carotid artery stenosis.** *JAMA* 1995;273:1421–1428
3. Gaunt ME, Martin PJ, Smith JL, et al. **Clinical relevance of intraoperative embolization detected by transcranial Doppler ultrasonography during carotid endarterectomy: a prospective study of 100 patients.** *Br J Surg* 1994;81:1435–1439
4. Gossetti B, Martinelli O, Guerricchio R, Irace L, Benedetti-Valentini F. **Transcranial Doppler in 178 patients before, during, and after carotid endarterectomy.** *J Neuroimaging* 1997;7:213–216
5. Muller M, Behnke S, Walter P, Omlor G, Schimrigk K. **Microembolic signals and intraoperative stroke in carotid endarterectomy.** *Acta Neurol Scand* 1998;97:110–117
6. Brinkman SD, Braun P, Ganji S, Morrell RM, Jacobs LA. **Neuropsychological performance one week after carotid endarterectomy reflects intra-operative ischemia.** *Stroke* 1984;15:497–503

7. Cantelmo NL, Babikian VL, Samaraweera RN, Gordon JK, Pochay VE, Winter MR. **Cerebral microembolism and ischemic changes associated with carotid endarterectomy.** *J Vasc Surg* 1998;27:1024–1030
8. Jansen C, Ramos LM, van Heesewijk JP, Moll FL, van Gijn J, Akerstaff RG. **Impact of microembolism and hemodynamic changes in the brain during carotid endarterectomy.** *Stroke* 1994;25:992–997
9. Moseley ME, Kucharczyk J, Mintorovitch J, et al. **Diffusion-weighted MR imaging of acute stroke: correlation with T2-weighted and magnetic susceptibility-enhanced MR imaging in cats.** *AJNR Am J Neuroradiol* 1990;11:423–429
10. Muller M, Reiche W, Langenscheidt P, Hassfeld J, Hagen T. **Ischemia after carotid endarterectomy: comparison between transcranial Doppler sonography and diffusion-weighted MR imaging.** *AJNR Am J Neuroradiol* 2000;21:47–54
11. Holland MC, Spetzler RF. **Carotid endarterectomy.** *Neuroimaging Clin N Am* 1996;4:939–956
12. Goldstein LB, Bertels C, Davis JN. **Interrater reliability of the NIH stroke scale.** *Arch Neurol* 1989;46:660–662
13. Basu AP, Gaylor DW, Chen JJ. **Estimating the probability of occurrence of tumor for a rare cancer with zero occurrence in a sample.** *Regul Toxicol Pharmacol* 1996;23:139–144
14. Posner KL, Sampson PD, Caplan RA, Ward RJ, Cheney FW. **Measuring interrater reliability among multiple raters: an example of methods for nominal data.** *Stat Med* 1990;9:1103–1115
15. van Everdingen KJ, van der Grond J, Kappelle LJ, Ramos LM, Mali WP. **Diffusion-weighted magnetic resonance imaging in acute stroke.** *Stroke* 1998;29:1783–1790
16. Bryan RN, Levy LM, Whitlow WD, Killian JM, Preziosi TJ, Rosario JA. **Diagnosis of acute cerebral infarction: comparison of CT and MR imaging.** *AJNR Am J Neuroradiol* 1991;12:611–620
17. Noguchi K, Nagayoshi T, Watanabe N, et al. **Diffusion-weighted echo-planar MRI of lacunar infarcts.** *Neuroradiology* 1998;40:448–451
18. Arbelaez A, Castillo M, Mukherji SK. **Diffusion-weighted MR imaging of global cerebral anoxia.** *AJNR Am J Neuroradiol* 1999;20:999–1007
19. Yoneda Y, Tokui K, Hanihara T, Kitagaki H, Tabuchi M, Mori E. **Diffusion-weighted magnetic resonance imaging: detection of ischemic injury 39 minutes after onset in a stroke patient.** *Ann Neurol* 1999;45:794–797
20. Warach S, Chien D, Li W, Ronthal M, Edelman RR. **Fast magnetic resonance diffusion-weighted imaging of acute human stroke.** *Neurology* 1992;42:1717–1723
21. Baird AE, Benfield A, Schlaug G, et al. **Enlargement of human cerebral ischemic lesion volumes measured by diffusion-weighted magnetic resonance imaging.** *Ann Neurol* 1997;41:581–589
22. Kidwell CS, Alger JR, Di Salle F, et al. **Diffusion MRI in patients with transient ischemic attacks.** *Stroke* 1999;30:1174–1180
23. Rothwell PP, Slattery J, Warlow CP. **A systematic comparison of the risks of stroke and death due to carotid endarterectomy for symptomatic and asymptomatic stenosis.** *Stroke* 1996;27:266–269
24. Han PP, Zabramski JM, Spetzler RF, Porter RW, Detwiler PW, Jahnke H. **Microsurgical carotid endarterectomy in 629 cases: The Barrow Neurological Institute experience from 1988 to 1997.** Presented at the 69th Annual Meeting of the American Association of Neurosurgeons, San Francisco, 2000