



Get Clarity On Generics

Cost-Effective CT & MRI Contrast Agents



FRESENIUS
KABI

WATCH VIDEO

AJNR

Optic Nerve Cysticercosis: Imaging Findings

Satish Chandra, Sushma Vashisht, Vimla Menon, Manorama Berry and Suresh K. Mukherji

AJNR Am J Neuroradiol 2000, 21 (1) 198-200

<http://www.ajnr.org/content/21/1/198>

This information is current as
of August 11, 2025.

Case Report

Optic Nerve Cysticercosis: Imaging Findings

Satish Chandra, Sushma Vashisht, Vimla Menon, Manorama Berry, and Suresh K. Mukherji

Summary: We present the imaging findings of retrobulbar optic nerve cysticercosis in a 50-year-old woman with a 6-month history of vision loss. Contrast-enhanced CT revealed an approximately 7-mm ring-enhancing cyst with a mural nodule located in the anterior portion of the left optic nerve. A contrast-enhanced MR imaging study revealed a cystic lesion with peripheral enhancement of the mural nodule. Sonography showed a cystic mass with a focal area of increased echogenicity corresponding to the mural nodule.

Optic nerve cysticercosis is an unusual entity, with only two reported cases in the literature. We present the CT, MR, and sonographic findings of retrobulbar optic neuritis and show the clinical impact of correctly identifying this appearance.

Case Report

A 50-year-old woman was referred to our hospital with a 6-month history of a dull headache of the left frontal and temporal region and left ocular pain. The ocular pain was exacerbated with eye movement. The patient also noted a gradual loss of vision in the left eye during the previous 4 months. The patient had been treated at an outside hospital with analgesics and steroids for a month but had experienced no improvement in her symptoms.

A physical examination revealed mild proptosis with complete loss of vision in the left eye. Direct ophthalmoscopic and fluorescein angiographic examinations revealed features suggestive of left optic disk edema, congestion, and retinal vein obstruction. The visual evoked potential was abnormal and showed decreased amplitude and increased latency. The results of electroretinography of the left eye were also abnormal. An examination of the right eye revealed only a mild refractive error. The remaining results of the examination of the right eye were normal. The results of the laboratory examination were normal except for mildly elevated blood sugar.

Initial contrast-enhanced CT was performed in the axial and coronal planes with 2-mm contiguous sections. The study revealed an approximately 7-mm ring-enhancing cyst located in the anterior portion of the left optic nerve (Fig 1A). A contrast-enhanced MR imaging study revealed the mass to have high T2 signal and to expand the distal portion of the optic nerve

(Fig 1B). The T1-weighted sequence showed the lesion to be of low signal (Fig 1C). After the administration of contrast material, there was peripheral enhancement along the margin of the cystic lesion that extended to involve the nerve/globe junction. The right orbit and brain were normal. No other intracerebral lesions were identified.

Based on the above investigations, the differential diagnosis included atypical optic nerve glioma, abscess, or optic nerve coloboma. Because of the high prevalence of parasitic disease in our population, we elected to perform repeat contrast-enhanced CT using contiguous 1-mm-thick sections. This study revealed a high-attenuation eccentric mass situated within the periphery of the cyst. These findings were suggestive of a scolex (Fig 1D). Sonography was performed using a 7-MHz linear transducer to evaluate the optic nerve lesion further. This revealed a focal area of increased echogenicity that corresponded to the peripheral nodule identified on the CT scans (Fig 1E). Based on the imaging results and the high prevalence of disease in our region, these findings were thought to represent isolated optic nerve cysticercosis.

Serum and CSF enzyme-linked immunosorbent assay testing were both positive for cysticercosis and confirmed the diagnosis. The patient was treated conservatively without histologic confirmation, thereby avoiding a surgical procedure. The patient was treated with a 2-week course of albendazole and prednisolone. There was a substantial improvement in the retinal congestion and edema. The patient, however, did not regain vision in the left eye. The patient refused to undergo follow-up post-treatment imaging studies.

Discussion

Cysticercosis is the most common parasitic disease involving the CNS. It is caused by infestation of the larval form of *Taenia solium*, with humans being the primary host (1). Intraocular cysticercosis occurs in 3% of the cases. The involvement may be unilateral or bilateral (2). The cysts may be single or multiple (2). Depending on their size and location, orbital cysticercosis may be associated with chemosis, ocular pain, proptosis, periorbital swelling, ptosis, double vision, and ophthalmoplegia (3).

The diagnosis of cysticercosis is based on clinical, serologic, and imaging findings. The clinical findings and serologic results may occasionally be nondiagnostic. Thus, imaging studies are often helpful in establishing the diagnosis of cysticercosis (3). There are four stages of evolution of cysticercosis: vesicular, colloidal vesicular, granular nodular, and the nodular calcified stage. The CT scanning and MR imaging appearances differ with the stage of the disease (4). Identification of the cyst and associated scolex is seen in the vesicular stage. This appearance is strongly suggestive of cysticercosis, especially in endemic regions of the

Received June 21, 1999; accepted after revision August 3.

From the Departments of Radiology (S.C., S.V., M.B.) and Ophthalmology (V.M.), All India Institute of Medical Sciences, New Delhi, India, and the Departments of Radiology (S.K.M.) and Surgery (S.K.M.), University of North Carolina School of Medicine, Chapel Hill, NC.

Address reprint requests to Suresh K. Mukherji, MD, Department of Radiology, 3324 Old Infirmary, CB# 7510, University of North Carolina School of Medicine, Chapel Hill, NC 27599.

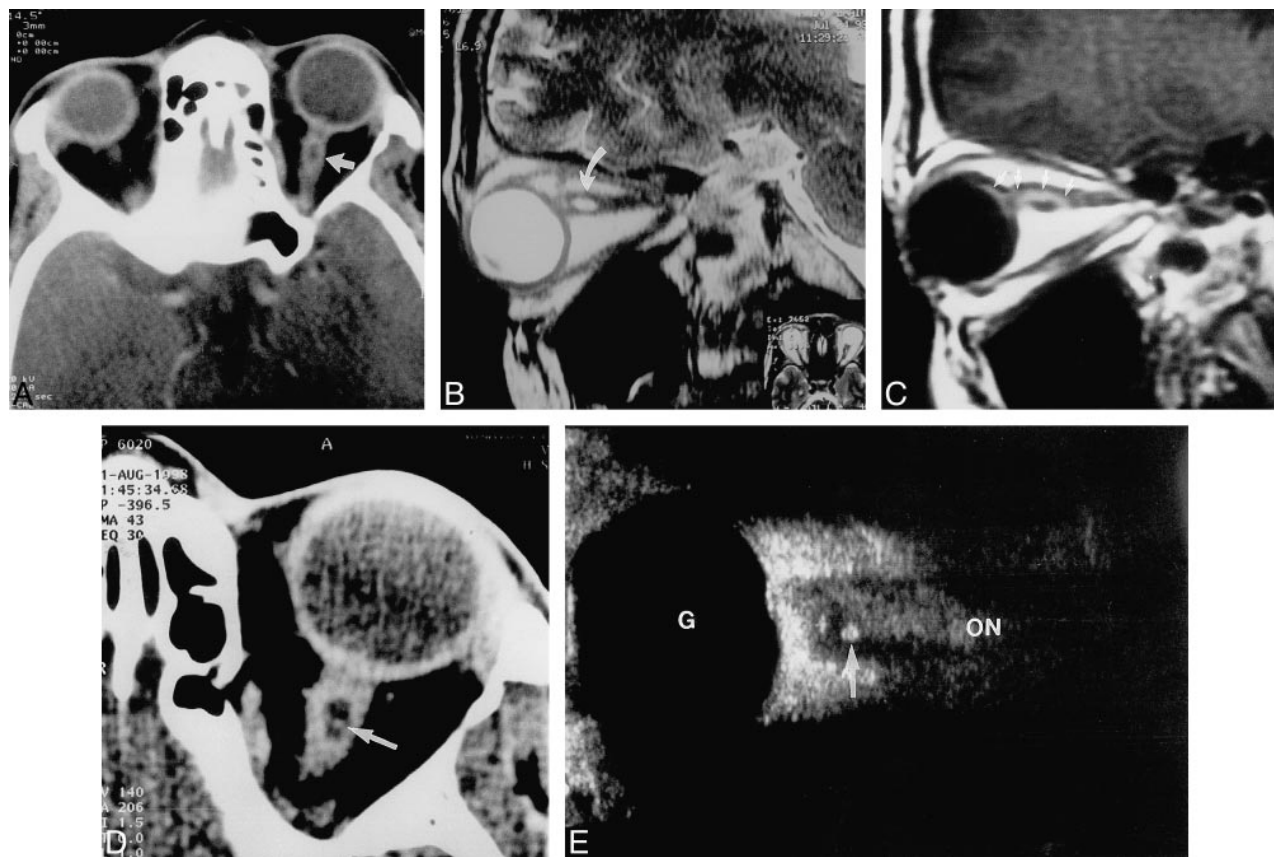


FIG 1. Images from the case of a 50-year-old woman who was referred to our hospital with a 6-month history of a dull headache of the left frontal and temporal region and left ocular pain.

A, Axial contrast-enhanced CT scan (2-mm slice thickness) shows a cystic ring-enhancing lesion in the anterior aspect of the left optic nerve (arrow).

B, Sagittal T2-weighted images confirm that the mass is cystic and is located within the anterior portion of the optic nerve (arrow). There is no associated edema of the adjacent optic nerve.

C, Sagittal T1-weighted images, obtained after the administration of contrast material, show enhancement along the periphery of the cyst involving the adjacent optic nerve (arrows).

D, One-millimeter-thick axial CT scan, obtained through the optic nerve, shows a peripheral soft-tissue mass that is suspicious for a scolex (arrow).

E, Sonogram shows an echogenic mass (arrow) in the distal optic nerve (ON) that corresponds to the soft-tissue mass identified in D (G, globe).

world (5, 6). The vesicular stage was probably present in our case; our imaging studies revealed a cyst with a mural nodule (scolex). As many as 6% of the cysts in the vesicular stage show the peripheral enhancement that was shown in our case (4).

Optic nerve involvement by cysticercosis is extremely rare, with only two reported cases in the literature (1, 2). Our findings were isolated to the optic nerve without other intracerebral lesions. This is similar to what has been identified in the other two reported cases (1, 2). Orbital involvement is thought to arise from hematogenous spread of disease (1, 2). The optic nerve receives its blood supply from a branch of the central retinal artery. Hematogenous spread along the branches of this artery may result in isolated involvement of the optic nerve.

The CT findings in our case are similar to those previously reported; however, the previous studies had not identified the scolex (1, 2). As a result, the diagnosis in those cases had to be confirmed

by surgical resection (1, 2). We found contiguous 1-mm-thick sections to be useful in identifying the scolex. This technique has not been previously reported in the evaluation of the optic nerve cysticercosis. We do not advocate performing this protocol routinely because of the unacceptably high lens dose; nonetheless, this detailed imaging may be helpful in selected cases such as ours.

The MR imaging and sonographic findings of optic nerve cysticercosis have not, to our knowledge, been reported. The MR imaging findings helped confirm the cystic nature of the lesion and showed that the mass was situated within the optic nerve. The lack of surrounding edema in the adjacent optic nerve on T2-weighted sequences helped estimate the stage of the larva. The lack of edema suggested that the larva was alive and in the vesicular stage (5). The presence of the focal area of increased echogenicity located in the optic nerve probably represented the scolex. This sonographic

appearance is typically seen in hepatic and splenic involvement by the vesicular stage of cysticercosis.

A drawback of our report is the lack of histologic confirmation. Surgical exploration of the anterior portion of the optic nerve is associated with significant morbidity. The risks associated with biopsy of the nerve include exacerbation of sight loss of patients with residual vision. Because CSF surrounds the optic nerve, there is a risk of CSF leak. Additionally, there is also the risk of seeding the CSF and causing meningitis in a patient who has no clinical evidence of CNS involvement. As a result, surgical exploration was not performed.

Based on the serologic and imaging findings, the patient was treated with praziquantel, and biopsy was avoided. Serum enzyme-linked immunosorbent assay testing has a high diagnostic accuracy for detecting neurocysticercosis with a sensitivity of 97% and a specificity of 98.3% (7). Despite the lack of pathologic confirmation, the diagnosis was thought to be cysticercosis. Cysticercosis seemed reasonably certain because of the high prevalence of cysticercosis in this endemic region, the positive results of the enzyme-linked immunosorbent assay test, the patient's substantial improvement after the

administration of antimicrobial therapy, the typical findings of the cyst and scolex, and the similarity of these findings to those of other published reports.

In conclusion, we present the imaging findings of retrobulbar optic nerve cysticercosis. This appearance was helpful in initiating appropriate therapy and avoiding the potential morbidity associated with optic nerve biopsy.

References

1. Madan VS, Dhamija RM, Gill IIS, et al. **Optic nerve cysticercosis: a case report.** *J Neurol Neurosurg Psychiatry* 1991;54:470-471
2. Bonsquet CF, Dufour TFL, Derome PCE. **Retrobulbar optic nerve cysticercosis.** *J Neurosurg* 1996;84:293-296
3. Miller NR. **Disease of helminths.** In: Miller NR, ed. *Walsh and Hoyt's Clinical Neuro Ophthalmology*. Baltimore: Wilkins & Wilkins 1995;335-3357
4. Chang KH, Lee JH, Han MH, Han MC. **The role of contrast-enhanced MR imaging in the diagnosis of neurocysticercosis.** *AJR Am J Roentgenol* 1991;157:393-396
5. Teitelbaum GP, Otto RJ, Lin M, et al. **MR imaging of neurocysticercosis.** *AJR Am J Roentgenol* 1989;153:857-866
6. Rajashekar V, Chandy MJ. **Comparative study of CT and MRI in patients with seizures and a solitary cerebral cysticercus granuloma.** *Neuroradiology* 1996;38:542
7. Salinas P, Sandoval L, Rugiero E, Contreras MC. **Diagnosis of human cysticercosis by ELISA-IgG using a purified antigen.** *Bol Chil Parasitol* 1996;51:85-90