



Providing Choice & Value
Generic CT and MRI Contrast Agents

**FRESENIUS
KABI**

CONTACT REP

AJNR

Ramsay Hunt Syndrome Associated with Brain Stem Enhancement

Sabine Sartoretti-Schefer, Spyros Kollias and Anton Valavanis

AJNR Am J Neuroradiol 1999, 20 (2) 278-280

<http://www.ajnr.org/content/20/2/278>

This information is current as
of July 19, 2025.

Case Report

Ramsay Hunt Syndrome Associated with Brain Stem Enhancement

Sabine Sartoretti-Schefer, Spyros Kollias, and Anton Valavanis

Summary: Postcontrast T1-weighted MR images in a patient with Ramsay Hunt syndrome showed an enhancing lesion in the region of the nucleus of the pontine facial nerve and abnormal enhancement of the intrameatal, labyrinthine, and tympanic facial nerve segments and of the geniculate ganglion, as well as enhancement of the vestibulocochlear nerve and parts of the membranous labyrinth. This enhancement most probably resulted from a primary neuritis of the intrameatal nerve trunks of the seventh and eighth cranial nerves.

MR images in patients with Ramsay Hunt syndrome (herpes zoster oticus) usually show intensely enhancing intrameatal nerve segments of the seventh and eighth cranial nerves and enhancement of parts of the membranous labyrinth and of different intratemporal facial nerve segments (1–5). However, only one report has described an abnormal T2-weighted hyperintense signal in the region of the pontine facial nerve nucleus in a patient with herpes zoster oticus (6). We present a case of clinically and laboratory proved Ramsay Hunt syndrome in which MR studies showed not only the typical MR characteristics mentioned above but also an enhancing, ischemic lesion in the pons on postcontrast T1-weighted images, most probably related to inflammation.

Case Report

A 58-year-old previously healthy man had acute and complete peripheral facial nerve palsy, hearing loss, and vertigo, which had ensued over the preceding 28 hours. Physical examination revealed painful cutaneous auricular vesicles within the external auditory canal and on the auricle; laboratory examination of the blood serum showed elevated IgM antibodies against varicella zoster virus. A severe sensorineural hearing loss was determined, and electroneurography revealed a neural degeneration of 85% maximum over the following 7 days. A diagnosis of Ramsay Hunt syndrome (herpes zoster oticus) was established. On the third day after onset of the palsy, an MR examination was performed on a 1.5-T MR unit using a phased-array dual coil with a diameter of 5 inches applied to both ears. Transverse precontrast T1-weighted images were acquired with a section thickness of 3 mm, a gap of 0.5 mm, a field of view (FOV) of 180 mm, a matrix of 256 × 192, and parameters of 500/16/3 (TR/TE/exci-

tations). Transverse and coronal postcontrast images after intravenous injection of 20 mL gadopentetate dimeglumine were obtained with 3-mm-thick overlapped (gap, 1 mm) sections, an FOV of 170 mm, and parameters of 600/16/4.

Postcontrast T2-weighted images of the brain stem with 4-mm-thick sections, a gap 0.5 mm, and parameters of 3500/120,20/2 and an FOV of 200 mm were added. On postcontrast T1-weighted images, the cisternal-subarachnoid segment of the vestibulocochlear nerve, the distal intrameatal segment of the facial nerve, the basal cochlea turn, and the dura covering the internal auditory canal enhanced intensely on the left side (Fig 1A and B). Additionally, focal, patchy, but slight enhancement was visible in the region of the pontine colliculus facialis along the lateral and caudal floor of the fourth ventricle (Fig 1A). T2-weighted images of the brain stem did not show any abnormality (Fig 1C).

After analgesic treatment and intravenous therapy of acyclovir and corticosteroids, the patient reported some improvement in the seventh nerve function and a partial recovery of the hearing loss. He left the hospital on the eighth day after onset of the disease; follow-up MR examinations were refused.

Discussion

Patients with Ramsay Hunt syndrome due to varicella zoster viral infection typically present with a peripheral facial nerve palsy associated with sensorineural hearing loss, tinnitus, vertigo with nystagmus, painful vesicular eruption within the external ear canal and of the auricle and the tympanic membrane, malaise, and fever (1, 5, 6). Several articles describing the MR findings in Ramsay-Hunt syndrome have reported contrast enhancement of the seventh and eighth nerve trunks within the distal internal auditory canal and along the labyrinthine segment (1–4) as well as enhancement of the cochlea, vestibule, and parts of the semicircular canals (1–3, 5). Additionally, intense enhancement of the geniculate ganglion and the tympanic and mastoid facial nerve segments has been observed (2, 4, 5), and the blister lesions of the external auditory canal show enhancement as well (5).

In the first description of this disease (7), a viral infection involving the geniculate ganglion was suspected to be the cause of inflammation of the auricular vesicles and of the seventh and eighth nerves. Internuclear connections (ie, the vestibulofacial anastomosis that connects the superior division of the vestibular nerve and the facial nerve) provide an anatomic explanation as to how the inflammation spreads from the facial nerve to the vestibular and cochlear nerves (8). On histologic examination, inflammatory infiltrates of lympho-

Received February 9, 1998; accepted after revision May 27.

From the Institute of Neuroradiology, University Hospital of Zürich, Frauenklinikstrasse 10, CH-8091 Zürich, Switzerland.

Address reprint requests to Sabine Sartoretti-Schefer, MD.

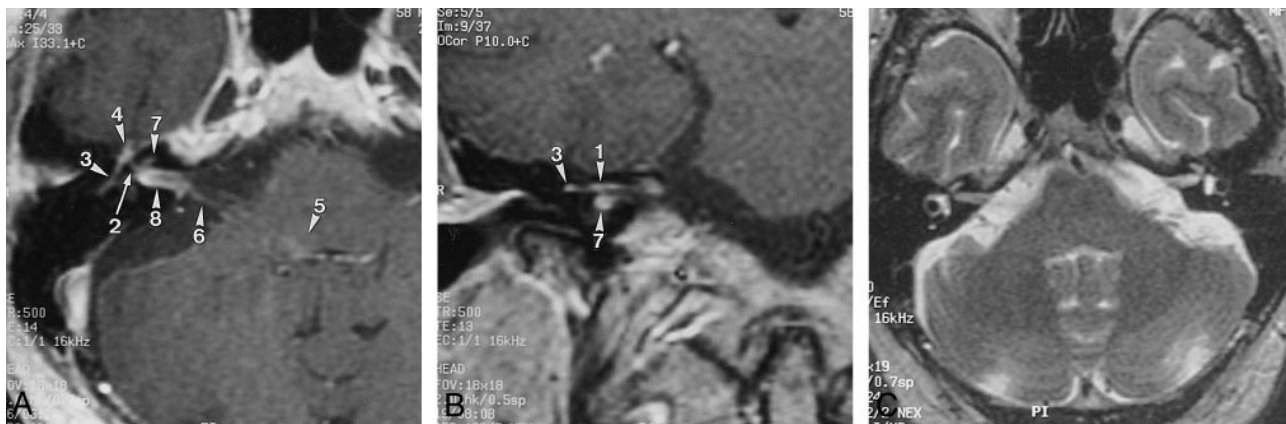


FIG 1. 58-year-old man with acute and complete peripheral facial nerve palsy, hearing loss, and vertigo for 28 hours.

A and B, Postcontrast transverse (A) and coronal (B) T1-weighted images show abnormal enhancement of the right facial nerve in the distal intrameatal (1) and labyrinthine (2) nerve segments with normal enhancement of the tympanic nerve segment (3). There is also abnormal enhancement of the geniculate ganglion (4), the pontine colliculus facialis (5), the vestibulocochlear nerve (6), and the basal turn of the cochlea (7). The dura covering the internal auditory canal (8) is also enhanced.

C, Transverse T2-weighted image through the brain stem shows no hyperintense signal in the pontine lesion, and the signal intensity within the right internal auditory canal is reduced.

cytes and plasma cells in the geniculate ganglion have rarely been reported (9, 10), whereas neuritis of the trunks of the seventh and eighth nerves within the internal auditory canal and of the intratemporal facial nerve segments has been described several times (10–12). Moreover, because cases of histologically proved herpetic inflammation of the facial nerve have been reported in which no inflammatory infiltrates were found within the geniculate ganglion (7, 11, 12), it has been concluded that geniculate ganglionitis does not exist as a specific pathologic entity (9) but occurs only in conjunction with simultaneous infection of the trunks of the seventh and eighth nerves within the internal auditory canal and secondarily spreads to the geniculate ganglion in some patients (10–12). Infection of the vestibulocochlear nerve as well as of the vestibular ganglion and the spiral ganglion has been demonstrated histologically as well (10). The infection presumably spreads to the membranous labyrinth via the vestibulocochlear nerve (5, 6) and via interneural connections that form anastomoses between the vestibular and cochlear nerves and the labyrinth (8).

Scattered inflammatory infiltrates along the intrapontine facial nerve from its nuclear origin within the caudal and lateral pons to its nerve root exit zone at the lateral pons have been described histologically (12). However, to date, involvement of the pontine nucleus and the intrapontine nerve course has not been demonstrated on postcontrast T1-weighted images. A single report has described an abnormal T2 hyperintensity in the region of the intrapontine seventh nerve nucleus in a patient with Ramsay Hunt syndrome (6), consistent with inflammatory involvement.

Cerebral angiitis has been reported in patients with herpes zoster ophthalmicus (13, 14). In these cases, retrograde spread of the virus along the intracranial branches of the trigeminal nerve to the

arterial wall with secondary vascular wall inflammation (necrotizing angiitis) and vessel thrombosis was suspected, since the trigeminal nerve (especially the branches of the ophthalmic division) provides the sensory innervation of the intracranial portion of the internal carotid artery and of segments of the middle and anterior cerebral artery (13). This hypothesis is supported by electron microscopic findings showing viral particles in vascular smooth muscle cells and giant cells within the vessel wall, suggesting a direct viral infection of the vessel wall (13, 15). Hematogenous or contiguous dissemination via CSF pathways may cause cerebral angiitis as well (14).

In our patient with varicella zoster viral infection, a contrast-enhancing lesion in the region of the intrapontine facial nerve nucleus without elevated signal on T2-weighted images was seen on postcontrast T1-weighted images together with abnormal enhancement of the peripheral facial nerve along the distal intrameatal, labyrinthine, and tympanic nerve segments and of the geniculate ganglion, consistent with inflammation of the facial nerve nucleus within the pons; of the peripheral facial nerve itself; and of the geniculate ganglion. The primary site of infection was located within the nerve trunks within the internal auditory canal, from where the virus spread in a retrograde fashion along the subarachnoid nerve segment through the parapontine cistern to the pons and in an antero-grade fashion along the peripheral nerves to the geniculate ganglion (16).

But why didn't the T2-weighted images show any abnormality at the site of focal enhancement in the pons, similar to that seen in patients with rhombencephalitis (16)? In accordance with pathologic observations, intrapontine inflammation due to viral spread of varicella zoster viral infection to the brain stem may lead to a local angiitic vessel involvement and to vessel occlusion, with secondary

local ischemic infarction and breakdown of the blood-brain barrier. Therefore, the slight enhancement seen within the pons without associated hyperintensity on the T2-weighted images could have been caused by the presence of a small focus of subacute local ischemia.

Conclusion

Postcontrast T1-weighted MR images in a patient with Ramsay Hunt syndrome showed an enhancing lesion in the region of the pontine facial nerve nucleus and abnormal enhancement of the intrameatal and intratemporal nerve trunks, including the labyrinthine and tympanic nerve segments, the geniculate ganglion, the vestibulocochlear nerve, and parts of the membranous labyrinth. This resulted most probably from a primary neuritis of the intrameatal nerve trunks of the seventh and eighth cranial nerves with secondary anterograde and retrograde spread of the inflammation to the intratemporal nerve segments and to the brain stem.

References

1. Downie AC, Howlett DC, Koefman RJ, Banerjee AK, Tonge KA. **Case report: prolonged contrast enhancement of the inner ear on magnetic resonance imaging in Ramsay Hunt syndrome.** *Br J Radiol* 1994;67:819-821
2. Sartoretti-Schefer S, Wichmann W, Valavanis A. **Gadolinium-enhanced MR in patients with idiopathic, herpetic, and HIV-associated facial nerve palsies: abnormal enhancement patterns compared with normal individuals.** *AJNR Am J Neuroradiol* 1994;15:479-485
3. Kuo MJ, Drago PC, Proops DW, Chavda SV. **Early diagnosis and treatment of Ramsay Hunt syndrome: the role of magnetic resonance imaging.** *J Laryngol Otol* 1995;109:777-780
4. Tada Y, Aoyagi M, Tojima H, et al. **Gd-DTPA enhanced MRI in Ramsay Hunt syndrome.** *Acta Otolaryngol Suppl (Stockh)* 1994;511:170-174
5. Osumi A, Tien RD. **MR findings in a patient with Ramsay-Hunt syndrome: case report.** *J Comput Assist Tomogr* 1990;14:991-993
6. LaBagnara J, Jahn AF, Habif DV, Solomon EM. **MRI findings in two cases of acute facial paralysis.** *Otolaryngol Head Neck Surg* 1989;101:562-565
7. Hunt JR. **On herpetic inflammations of the geniculate ganglion and its complications.** *J Neurol Ment Dis* 1907;34:73-96
8. Gulya AJ, Schuknecht HF. **The vestibular nerves.** In: Gulya AJ, Schuknecht, eds. *Anatomy of the Temporal Bone*. New York: Parthenon; 1995:181-182
9. Aleksic SN, Budzilovich GN, Liebermann AN. **Herpes zoster oticus and facial paralysis (Ramsay Hunt syndrome): clinico-pathologic study and review of the literature.** *J Neurol Sci* 1973;20:149-159
10. Blackley B, Friedmann I, Wright I. **Herpes zoster auris associated with facial nerve palsy and auditory nerve symptoms: a case report with histopathological findings.** *Acta Otolaryngol* 1967;63:533-550
11. Etholm B, Schuknecht HF. **Pathological findings and surgical implication in herpes zoster oticus.** *Adv Otorhinolaryngol* 1983;31:184-190
12. Denney-Brown MB, Adams RD, Fitzgerald PJ. **Pathologic features of herpes zoster: note on "geniculate herpes."** *Arch Neurol Psych* 1944;51:216-231
13. Doyle PW, Gibson G, Dolman CL. **Herpes zoster ophthalmicus with contralateral hemiplegia: identification of cause.** *Ann Neurol* 1983;14:84-85
14. Hilt DC, Buchholz A, Krumholz A, et al. **Herpes zoster ophthalmicus and delayed contralateral hemiparesis caused by cerebral angiitis: diagnosis and management approaches.** *Ann Neurol* 1983;14:543-553
15. Linnemann CC, Alvira MM. **Pathogenesis of varicella-zoster angiitis in the CNS.** *Arch Neurol* 1980;37:239-240
16. Tien RD, Dillon WP. **Herpes trigeminal neuritis and rhombencephalitis on Gd-DTPA-enhanced MR imaging.** *AJNR Am J Neuroradiol* 1990;11:413-414