



Providing Choice & Value

Generic CT and MRI Contrast Agents

**FRESENIUS
KABI**

CONTACT REP

AJNR

A Quantitative MR Study of the Hippocampal Formation, the Amygdala, and the Temporal Horn of the Lateral Ventricle in Healthy Subjects 40 to 90 Years of Age

Qiwen Mu, Jingxia Xie, Zongyao Wen, Yaqin Weng and Zhang Shuyun

This information is current as of July 20, 2025.

AJNR Am J Neuroradiol 1999, 20 (2) 207-211
<http://www.ajnr.org/content/20/2/207>

A Quantitative MR Study of the Hippocampal Formation, the Amygdala, and the Temporal Horn of the Lateral Ventricle in Healthy Subjects 40 to 90 Years of Age

Qiwen Mu, Jingxia Xie, Zongyao Wen, Yaqin Weng, and Zhang Shuyun

BACKGROUND AND PURPOSE: Several investigators have defined normal age-specific values for the medial temporal lobe structures in neurologically normal elderly subjects, but, to our knowledge, no one has reported those values for a large sample of healthy volunteers. The purpose of our study was to define normal age-specific values for the hippocampal formation, the amygdala, and the temporal horn of the lateral ventricle by age group, ranging from 40 to 90 years, in order to generate a guideline for the quantitative MR diagnosis and differential diagnosis for early Alzheimer disease.

METHODS: MR-based volumetric measurements of the hippocampal formation, the amygdala, and the temporal horn, standardized by total intracranial volume, were obtained from oblique coronal and sagittal T1-weighted MR images in 619 healthy volunteers and two cadaveric specimens.

RESULTS: Differences in standardized volumes of the hippocampal formation, the amygdala, and the temporal horn were significant among the 61- to 70-year-old, 71- to 80-year-old, and 81- to 90-year-old groups, and were not significant between the 40- to 50-year-old and 51- to 60-year-old groups. We found no significant differences in side or sex among the age groups for any of the structures.

CONCLUSION: Differences in the mean value and in the 95% normal range of standardized volumes of the hippocampal formation, the amygdala, and the temporal horn correspond to differences in age among healthy subjects; therefore, age should be considered a factor in correlative research, especially in that involving patients in the early stages of Alzheimer disease.

The diagnosis of Alzheimer disease (AD), or primary degenerative dementia, rests on neuropathologic evidence of senile plaques, neurofibrillary tangles, and cell loss, which predominate in the hippocampal formation, the amygdala, and the entorhinal cortex (1–3). The clinical diagnosis is not as accurate for the early stages of AD, in which

cognitive and memory deficits may be difficult to distinguish from age-related cognitive dysfunction (4). The difficulty in diagnosing this disorder may have some important implications for prognosis, therapy, and research. Because of the limitations of performing pathologic examination *in vivo*, MR imaging may be useful in the diagnosis of AD. In fact, MR-based volumetric measurements of the hippocampal formation and the amygdala have proved to be an important *in vivo* method for diagnosing AD (4–8).

Normal age-specific values of the medial temporal lobe structures have been defined in neurologically normal elderly subjects (9), but, to our knowledge, no study has defined those values for the medial temporal lobe structures in a large sample of healthy volunteers. Recent MR-based volumetric studies have focused on whether significant differences in volume exist between AD patients and control subjects (4–8), but ascertaining whether the volume of those structures, as measured on

Received May 28, 1998; accepted after revision October 26.

Supported in part by grants 39770203 and 39640004 from the Assistance of the Foundation of National Natural Science (China).

From the Department of Radiology, the Third School of Clinical Medicine (Q.M., J.X.), the Hemorheology Research Center (Z.W.), the Mental Health Institute (Y.W.), and the Department of Anatomy (S.Z.), Beijing Medical University, China.

Address reprint requests to Qiwen Mu, MD, PhD, P.O. Box 93, Beijing Medical University, Beijing 100083, Xue Yuan Rd 38, Hai Dian District, Beijing City, People's Republic of China.

MR images, is normal or abnormal for a specific individual is difficult (4, 5). The aim of the present study was to define the range of normal volume for the hippocampal formation, the amygdala, the temporal horn of the lateral ventricle in different age groups in order to generate a guideline for the MR diagnosis and differential diagnosis of early AD.

Methods

Study Population

Two cadavers without known neurologic or psychological disorders, both formerly healthy volunteers of the dementia study project of the Mental Health Institute of Beijing Medical University, and 619 healthy volunteers (63 men and 61 women in the 40- to 50-year-old group, 77 men and 78 women in the 51- to 60-year-old group, 63 men and 55 women in the 61- to 70-year-old group, 55 men and 57 women in the 71- to 80-year-old group, and 55 men and 55 women in the 81- to 90-year-old) were entered in the study. Participants met the following criteria: 1) no history of neurologic or psychological illness; 2) no history of cardiovascular or cerebrovascular disease; 3) no abnormal findings on neurologic or neuropsychological examinations; 4) no cerebral ischemic score greater than 4 (10); 5) no significant abnormal signal on spin-echo transverse or sagittal T1- or T2-weighted MR images; 6) no abnormal results of serum analysis, including thyroid hormones, vitamin B₁₂, folates, and syphilis serology, and 7) a Global Deterioration Scale Rating score of 1 (11). All volunteers gave informed consent.

MR Examination

The two cadaveric heads and all the volunteers were studied on a 1.5-T MR unit. After a scout sequence was obtained to ensure symmetric position of the subject's head, three series of images were taken during each examination: 1) transverse T1-weighted (500/15 [TR/TE]) and T2-weighted (3000/90) sequences with 5-mm-thick sections and no gap; 2) a sagittal T1-weighted sequence (500/15) with 5-mm-thick sections and no gap; and 3) an oblique coronal T1-weighted spin-echo sequence (500/15/2) with 2-mm-thick sections and no gap. The third sequence was acquired perpendicular to the long axis of the hippocampal formation. Volumes of the hippocampal formation, the amygdala, and the temporal horn were measured blinded five times by five radiologists. The mean volumetric values were then obtained to ensure accuracy of the measurements.

Volumetric Measurements and Volume Standardization

The margins of the hippocampal formation, the amygdala, and the temporal horn were outlined manually on the oblique coronal MR sections for each side. The volumes for these structures were then added together separately to arrive at a whole volume for each structure per side (the right, the left, and the average, which is half the volume of the right and the left). The total intracranial volume was obtained on sagittal sections, and the volumes of the hippocampal formation, the amygdala, and the temporal horn were standardized according to the method used by Lehericy and colleagues (4); that is, the whole volume of each structure was divided by the total intracranial volume times 1000, respectively, for each subject.

Comparison of Oblique Coronal MR Images and Corresponding Anatomic and Histologic Sections

After MR examination, the two cadaveric brains were fixed in paraformaldehyde for 3 months, hemisected, and cut into 0.5-cm slabs. Blocks of tissues containing the hippocampal

formation, the amygdala, and the temporal horn were frozen and cut into serial oblique coronal sections (10 μ m) on a freezing microtome. The plane of the sections was perpendicular to the long axis of the hippocampal formation so as to determine accurate and reproducible boundaries. The oblique coronal MR images of the three structures were compared with the anatomic histologic sections obtained from the two cadavers.

Statistical Analysis

The data of the standardized volumes of the hippocampal formation, the amygdala, and the temporal horn were processed by SPSS (Chicago, IL) statistical software package, including a normal distribution test (K-S Lilliefors); a homogeneity-of-variance test (one-way ANOVA, Levene test); an analysis of variance (one-way ANOVA, least-significant difference); a definition of the mean and the 95% normal range of values for the hippocampal formation, the amygdala, and the temporal horn by age group (one-way ANOVA, least-significant difference); and a correlation of volume with age (Pearson two-tailed).

Results

Normal Distribution Test

The K-S Lilliefors test to plot standardized volumes of the hippocampal formation, the amygdala, and the temporal horn revealed normal distributions ($P > .05$) for each side and each sex in all age groups.

Homogeneity-of-Variance Test

The Levene test for homogeneity of variance among the standardized volumes of the hippocampal formation, the amygdala, and the temporal horn revealed homogeneity of variance ($P > .05$) for three sides in each age group and for both sexes in all age groups.

Analysis of Variance

One-way ANOVA revealed significant differences in the standardized volumes of the hippocampal formation, the amygdala, and the temporal horn among the 61- to 70-year-old, 71- to 80-year-old, and 81- to 90-year-old groups, and no significant differences between the 41- to 50-year old and 51- to 60-year-old groups. There were no significant differences in standardized volumes between sides or sexes in any age group.

Definition of Mean Values and 95% Normal Range by Age Group

The mean values and the 95% normal range for the standardization volumes of the hippocampal formation, the amygdala, and the temporal horn are given in the Table. Histograms and linear graphs depicting the standardization volumes of the hippocampal formation, the amygdala, and the temporal horn with respect to different age groups appear in Figs 1 and 2, respectively.

Mean volume and 95% normal range for standardized volumes of the hippocampal formation (HF), amygdala (AM), and temporal horn (TH) (in cm³)

Structure	Age Group (y)	Right Side		Left Side		Average	
		Mean \pm SD	95% Normal Range	Mean \pm SD	95% Normal Range	Mean \pm SD	95% Normal Range
HF	40–60	2.76 \pm 0.08	2.60–2.92	2.76 \pm 0.08	2.60–2.92	2.76 \pm 0.08	2.60–2.92
HF	61–70	2.41 \pm 0.07	2.27–2.54	2.40 \pm 0.08	2.25–2.55	2.40 \pm 0.08	2.26–2.54
HF	71–80	2.25 \pm 0.08	2.10–2.39	2.24 \pm 0.08	2.10–2.37	2.24 \pm 0.08	2.10–2.38
HF	81–90	2.10 \pm 0.08	1.94–2.26	2.08 \pm 0.08	1.91–2.25	2.09 \pm 0.08	1.93–2.25
AM	40–60	1.92 \pm 0.07	1.78–2.06	1.92 \pm 0.07	1.78–2.06	1.92 \pm 0.07	1.78–2.06
AM	61–70	1.59 \pm 0.06	1.46–1.72	1.58 \pm 0.07	1.45–1.72	1.59 \pm 0.07	1.45–1.73
AM	71–80	1.44 \pm 0.07	1.31–1.58	1.43 \pm 0.07	1.31–1.56	1.44 \pm 0.07	1.30–1.58
AM	81–90	1.31 \pm 0.07	1.17–1.46	1.29 \pm 0.08	1.14–1.45	1.30 \pm 0.07	1.16–1.45
TH	40–60	0.11 \pm 0.04	0.03–0.19	0.10 \pm 0.04	0.02–0.18	0.10 \pm 0.04	0.02–0.18
TH	61–70	0.20 \pm 0.04	0.12–0.27	0.20 \pm 0.04	0.12–0.27	0.20 \pm 0.04	0.12–0.28
TH	71–80	0.30 \pm 0.04	0.23–0.38	0.31 \pm 0.04	0.23–0.39	0.31 \pm 0.04	0.22–0.38
TH	81–90	0.41 \pm 0.04	0.33–0.49	0.40 \pm 0.04	0.32–0.48	0.41 \pm 0.04	0.32–0.48

Note.—Significant differences in standardized volumes were found among the 40- to 60-year-old, 61- to 70-year-old, 71- to 80-year-old, and 81- to 90-year-old age groups ($P < .05$). Standardized volumes were not significantly different for side or sex in any age group ($P > .05$).

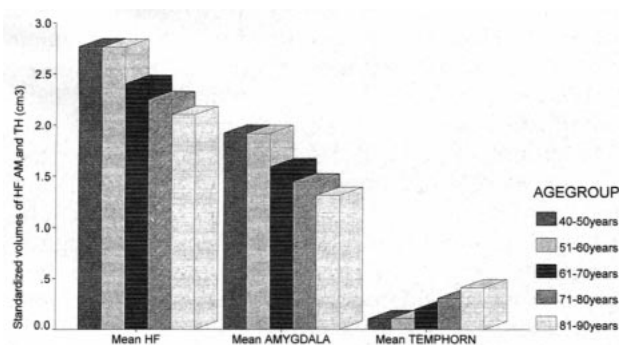


FIG 1. Histograms of standardized volumes of the hippocampal formation, the amygdala, and the temporal horn by age group.

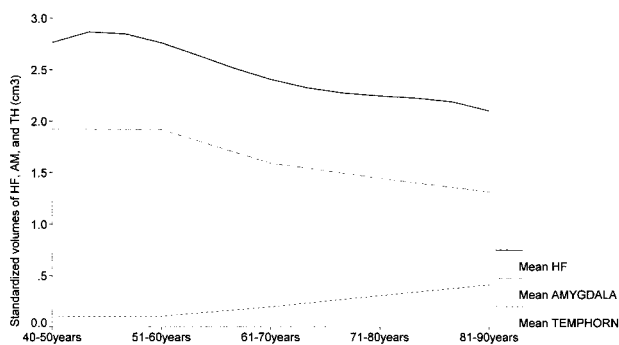


FIG 2. Graphs showing standardized volumes of the hippocampal formation, the amygdala, and the temporal horn by age group.

Correlation Test

An inverse correlation was found between the standardized volume of the hippocampal formation and age (Pearson correlation coefficient, -0.93 ; $P = .001$) and between the standardized volume of the amygdala and age (Pearson correlation coefficient, -0.92 ; $P = .001$). A positive correlation was found between the standardized volume of the tem-

poral horn and age (Pearson correlation coefficient, 0.89 ; $P = .001$).

Discussion

Necessity of MR-Based Volumetric Measurements

Previous studies have investigated the utility of volumetric measurements of the medial temporal lobe system in distinguishing patients with AD from control subjects (4–8, 12–14). Findings in quantitative volumetric studies designed to separate patients in the early stages of AD from control subjects have suggested that significant atrophy occurs in the medial temporal memory system (4). The neuropathologic process may begin in the hippocampal formation, the amygdala, and the entorhinal cortex, and then extend toward other cortical or subcortical areas (15). Although some studies have established normal age-specific values for the medial temporal lobe structures in neurologically normal elderly subjects, no such values have been reported for a large sample of healthy volunteers. Moreover, the criteria used were obtained by means of cadaveric research and did not reflect the volume of the hippocampal formation, the amygdala, and the temporal horn in vivo, since many factors affect the results of volumetric measurements in cadavers, and it is difficult to ensure that the cadaveric structures were normal in life. In addition, the age factor was not considered. In recent years, the volume of the hippocampal formation, the amygdala, and the temporal horn has typically been measured on MR images, with comparisons made between patients with AD and control subjects. The results of these studies revealed significant volumetric differences in these structures between AD and control groups; however, it has been difficult to judge whether these differences were due to pathologic processes or to physiological atrophy. Thus, it is important to

define a range of normal values for the hippocampal formation, the amygdala, and the temporal horn in healthy subjects in different age groups.

MR Anatomic Boundaries

Anatomic boundaries of the hippocampal formation, the amygdala, and the temporal horn can be easily defined on MR images, owing to the high-resolution, multiview, and multiparameter capability of this imaging technique (4, 15–19).

The hippocampal formation is divided into three parts: the head, the body, and the tail. There are no definite boundaries between these parts, but this has nothing to do with the results of volumetric measurements. Rostrally, the head of the hippocampal formation within the posterior part of the uncus was delineated from the amygdala and the parahippocampal gyrus by visualizing either the characteristic shape of hippocampal digitations and the uncus recess of the temporal horn or the band of high signal intensity generated by the alveus, which demarcates the hippocampal head from the overlying the amygdala. In the body of the hippocampal formation, the measurements included Ammon's horn, the subiculum, the dentate gyrus, and the white matter tracts of the alveus and the fimbria (4). The boundary between the subiculum and the parahippocampal gyrus was arbitrarily defined by a line in continuation with the inferior border of the subiculum. At the tail level of the hippocampal formation, caudally, the posterior boundary was chosen as the last section containing Ammon's horn, which corresponded to the section in which the crus of the fornix was visible. Measurement at this level included the subiculum, the hippocampus, the dentate gyrus, the alveus, and the fimbria, and excluded the parahippocampal gyrus and the isthmus of the cingulate gyrus (4, 16–19).

The volumetric measurements of the amygdala included the corticomedial, central, and basolateral subgroups and the gyrus semilunaris, which covers the cortical nucleus (18), and the medial border of the amygdala that is partly covered by the entorhinal cortex, which forms the surface of the gyrus ambiens. The entorhinal cortex corresponds to area 28 of Brodmann and constitutes a major part of the anterior parahippocampal gyrus (19). The gyrus ambiens was separated from the parahippocampal gyrus by the uncus notch. Measurements included the cortex of the gyrus ambiens, which could not be accurately separated from the amygdala, and excluded the entorhinal cortex inferior to the uncus notch. When the uncus notch was poorly or not at all visible in the anterior amygdala area, the demarcation between the amygdala and the entorhinal cortex was defined by a line in continuation with the inferior border of the amygdala, thus probably including a small part of the entorhinal cortex. The inferior and lateral borders of the amygdala were formed by the lateral ventricle or the white matter of the temporal lobe and were easily demarcated.

The superior border of the amygdala was not clear-cut. At its posterior end, the optic tract delineated the medial and the superior borders of the amygdala. At this level, the superior border was defined by a horizontal line at the superolateral aspect of the optic tract.

The borders of the temporal horn were easily determined because of the specific low signal intensity on T1-weighted images.

Statistical Results of Standardized Volumes

AD may be divided into two types according to the criteria established by Goate et al (1) and Scott (2): the later-attack type, when symptoms first appear at age 60 or older, and the earlier-attack type, when symptoms appear before the age of 60, usually at the age of 40. In the study undertaken by the National Institute of Neurological and Communicative Disorders and Stroke and the Alzheimer Disease and Related Disorders Association (20), the youngest age was defined as 40 years and the oldest as 90 years. The results of our study revealed that standardized volumes of the hippocampal formation, the amygdala, and the temporal horn were significantly different among the 61- to 70-year-old age group, the 71- to 80-year-old group, and the 81- to 90-year-old group, and were not significant between the 41- to 50-year-old and the 51- to 60-year-old groups. Because we also found no significant differences in side or sex among the age groups, we considered the 40- to 50-year-olds and 51- to 60-year-olds as one age group, the 61- to 70-year-olds as one age group, the 71- to 80-year-olds as one age group, and the 81- to 90-year-olds as one age group. The volume of the hippocampal formation and the amygdala reduced gradually with increasing age, owing to physiological atrophy, but the volume of the temporal horn increased gradually. Significant differences in the standardized volumes of the hippocampal formation, the amygdala, and the temporal horn were found among the age groups over 61 years, suggesting that the degree of atrophy is not the same for different age groups. The volume of the hippocampal formation and the amygdala correlated inversely with age for each side, and the volume of the temporal horn correlated positively with age for each side.

Conclusion

Significant differences in standardized volumes for the hippocampal formation, the amygdala, and the temporal horn were found among healthy subjects in the 40- to 60-year-old, 61- to 70-year-old, 71- to 80-year-old, and 81- to 90-year-old age groups, but no significant differences in side or sex were found among these groups, indicating that age rather than sex or side should be considered in correlative MR-based volumetric research and in clinical practice, especially in relation to patients in the early stages of AD.

References

- Goate A, Chartier-Harlin MC, Mullan ME, et al. **Segregation of a missense mutation in the amygdala precursor protein gene with familial Alzheimer's disease.** *Nature* 1991;349:704-706
- Scott J. **Apolipoprotein E and Alzheimer's disease.** *Lancet* 1993;342:696-699
- Hauw JJ, Duyckaerts C, Delaere P. **Neuropathology of aging and SDAT: how can age related changes be distinguished from those due to disease process?** In: Henderson AS, Henderson JH, Bernhard S, eds. *Dahlem konferenzen, Etiology of dementia of Alzheimer type*. Chichester: Wiley; 1988;195-211
- Lehericy S, Baulac M, Chiras J, et al. **Amygdalahippocampal MR volume measurements in the early stages of Alzheimer disease.** *AJNR Am J Neuroradiol* 1994;15:929-937
- Deleon MJ, George AE, Golomb J, et al. **Frequency of hippocampal formation atrophy in normal aging and Alzheimer disease.** *Neurobiol Aging* 1997;18:1-11
- Freeborough PA, Fox NC, Kitney RI. **Interactive algorithms for the segmentation and quantitation of 3-D MRI brain scans.** *Comput Methods Programs Biomed* 1997;53:15-25
- Kaye JA, Swihaart T, Howieson D, et al. **Volume loss of the hippocampus and temporal lobe in healthy persons destined to develop dementia.** *Neurology* 1997;40:1297-1304
- Fox NC, Warrington EK, Freeborough PA, et al. **Presymptomatic hippocampal atrophy in Alzheimer disease: a longitudinal MRI study.** *Brain* 1996;119:2001-2004
- Jack CR Jr, Petersen RC, Xu YC, et al. **Medial temporal atrophy on MRI in normal aging and very mild Alzheimer's disease.** *Neurology* 1997;49:786-794
- Hachinski VC, Iliff LD, Kihika, et al. **Cerebral flow in dementia.** *Arch Neurol* 1975;32:632-637
- Reisberg B, Ferris SH, Deleon MJ, Crook T. **The Global Deterioration Scale (GDS): an instrument for the assessment of primary degenerative dementia (PDD).** *Am J Psychiatry* 1982;139:1136-1139
- Kesslack JP, Nalcioglu O, Cotman CW. **Quantification of magnetic resonance scans for hippocampal and parahippocampal atrophy in Alzheimer's disease.** *Neurology* 1991;41:51-54
- Jack CR Jr, Petersen RC, O'Brien PC, et al. **MR-based hippocampal volumetry in the diagnosis of Alzheimer's disease.** *Neurology* 1992;42:183-188
- Seab JP, Jagust WJ, Wong STS, et al. **Quantitative MR measurements of hippocampal atrophy in Alzheimer's disease.** *Magn Reson Med* 1988;8:200-208
- Pearson RCA, Esiri MM, Hiorns RW, et al. **Anatomical correlates of the distribution of the pathology changes in the neocortex in AD.** *Proc Natl Acad Sci U S A* 1985;82:4531-4534
- Naidich TP, Daniels DL, Houghton VM, et al. **Hippocampal formation and related structures of the limbic lobe: anatomic-MR correlation, 1: surface features and coronal sections.** *Radiology* 1987;162:747-754
- Watson C, Andermann F, Gloor P, et al. **Anatomic basis of amygdaloid and hippocampal volume measurement by magnetic resonance imaging.** *Neurology* 1992;42:1743-1750
- Nieuwenhuys R, Voogd J, Van Huijzen Chr. **The Human Central Nervous System, a Synopsis and Atlas.** 3rd ed. Berlin: Springer; 1988
- Duvernoy HM. **The Human Hippocampus: An Atlas of Applied Anatomy.** Munich: Bergmann; 1988
- Mckhann G, Drachman D, Folstein M, et al. **Clinical diagnosis of AD disease: report of the NINCDS-ADRDA work group under the auspices of the Department of Health and Human Services Task Force on AD Disease.** *Neurology* 1984;34:939-944