



Get Clarity On Generics

Cost-Effective CT & MRI Contrast Agents

 FRESENIUS
KABI

[WATCH VIDEO](#)

AJNR

Myelography of sacral agenesis.

B S Brooks, T El Gammal, P Hartlage and W Beveridge

AJNR Am J Neuroradiol 1981, 2 (4) 319-323

<http://www.ajnr.org/content/2/4/319>

This information is current as
of August 12, 2025.

Myelography of Sacral Agenesis

Betty Sue Brooks¹
 Taher El Gammal¹
 Patricia Hartlage²
 Wayne Beveridge³

In the past, neurologic deficits found in association with sacral agenesis were thought to be unamenable to surgical therapy. Recent experience and a careful review of autopsy and case reports from the literature have demonstrated that this assumption is unwarranted. Four cases of sacral agenesis are reported with description of the myelographic findings of each case. Surgical confirmation was obtained in three of these patients. Dural sac stenosis treated with duraplasty resulted in striking improvement in the neurologic status of two patients, while in the third, a 2-month-old infant, adhesive arachnoidal bands in the distal thecal sac were found at surgery and a taut and thickened filum terminale was transected. The fourth patient had a low-lying spinal cord and a posterior meningocele. The myelographic findings appear to be divisible into two categories. One group of patients may have high termination of the subarachnoid space with a dural sac stenosis and will benefit from duraplasty, while in the other, findings may include a widened or normal subarachnoid space and low-lying tethered spinal cord. It is emphasized that treatment of dural sac stenosis, tethered cord, and intrathecal or extrathecal masses that occur in some of these patients may afford significant improvement in their neurologic condition. These children deserve careful baseline neurologic evaluation and follow-up and a more aggressive approach toward adequate myelographic assessment.

Myelograms have been obtained infrequently in children with sacral agenesis. In the past, emphasis has been on management of the more clinically apparent orthopedic and genitourinary tract problems that usually accompany this condition [1-8]. Accompanying neurologic deficits have received less attention, and surgical exploration has been infrequently attempted.

Recently, Pang and Hoffman [9] reported surgical improvement in the neurologic status of two patients with sacral agenesis. Their review of the literature revealed a number of cases in which surgery or autopsy had disclosed potentially treatable lesions associated with sacral agenesis including intrathecal and extrathecal masses such as lipomas and dermoid cysts, vertebral canal stenosis, diastematomyelia, and tethered cord. To their two cases, we offer myelographic and surgical observations on three patients at this institution and myelographic evaluation of a fourth patient at the University of North Carolina. It is hoped this report will further illustrate the need for careful baseline neurologic examination and close follow-up in these children as well as a more aggressive approach toward early myelography.

Case Reports

Case 1

A 17-month-old girl was initially seen in the Pediatric Clinic at the Medical College of Georgia for evaluation of constipation and a soft "mass" over the lower back present since birth. She had been slow in her motor development and did not start to walk until age 16 months. The mother was mentally retarded and diabetic.

Received October 31, 1980; accepted after revision February 23, 1981.

¹Department of Radiology, Section of Neuro-radiology, Medical College of Georgia, Augusta, GA 30912. Address reprint requests to B. S. Brooks.

²Department of Pediatric Neurology, Medical College of Georgia, Augusta, GA 30912.

³Department of Neurosurgery, Medical College of Georgia, Augusta, GA 30912.

AJNR 2:319-323, July/August 1981
 0195-6108/81/0204-0319 \$00.00
 © American Roentgen Ray Society

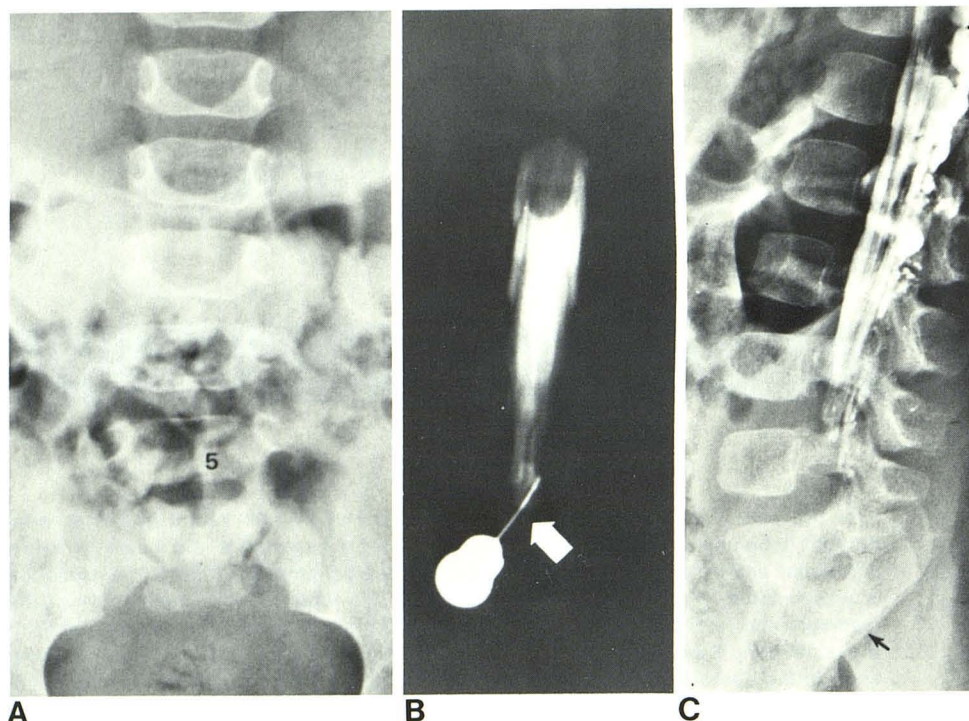


Fig. 1.—Case 1. **A**, Lumbar spine, anteroposterior view. Transitional vertebra at lumbosacral junction with agenesis of sacrum below dysplastic S2 segment. **B**, Overpenetrated anteroposterior Pantopaque myelogram. Unusual rounded lower border of conus at upper border of L1. Tapered termination of subarachnoid space ended at L4 (arrow). **C**, Lateral view, Amipaque lumbar myelogram. Agenesis of sacrum (arrow) and tapered lower border of subarachnoid space at L4 level.

Neurologic examination revealed an abnormal broad-based gait with "stumping" of the feet. There was bilateral atrophy of gluteal, thigh, and gastrocnemius muscles. Patellar reflexes were hyperactive, ankle reflexes were absent, and there was a Babinski reflex bilaterally. The anal sphincter was patulous and urinary dribbling was noted.

Radiographs of the spine demonstrated agenesis of the sacrum distal to a hypoplastic second sacral segment. Excretory urography disclosed duplication of the right renal collecting system; a voiding cystourethrogram was normal. An electromyogram was obtained and showed evidence of anal sphincter denervation of S2 and S3.

Pantopaque and Amipaque myelograms (fig. 1) demonstrated a tapered narrowing of the distal subarachnoid space that terminated at the L4 level. A prominent thickened filum terminale was noted and the conus appeared enlarged but in normal position at T12–L1. The Amipaque myelogram was followed by a computed tomography (CT) scan, which showed no lipoma or other intrathecal mass. A CT head scan showed moderate dilatation of the lateral ventricles and mild cortical atrophy.

Lumbar laminectomy from L1 to L5 was performed. The dura was stenosed distal to L2 and ended at L5 in a small lipoma. When the dura was opened, the roots of the cauda equina appeared to follow a normal direction without tension. However, the conus appeared more rounded than usual and blunted, as had been shown on the myelogram preoperatively. A fascia lata duraplasty was performed, and the postoperative course was uneventful.

Follow-up of this child for 2 years has demonstrated significant improvement both in gait and bowel and bladder incontinence. On physical examination, bilateral ankle reflexes were present. The electromyogram also demonstrated evidence of postoperative improvement with an increased number of anal sphincter motor unit potentials compared with the preoperative study.

Case 2

A 17-month-old girl was initially referred for failure to thrive and constipation. Laboratory data indicated early renal failure, and

urologic evaluation revealed a neurogenic bladder with bilateral vesicoureteral reflux and hydronephrosis. Agenesis of the sacrum distal to S1 was noted and she was placed on indwelling urethral Foley catheter drainage.

On neurologic examination, atrophy of the gluteal muscles was noted with slight tapering of the lower extremities and the anal sphincter tone was diminished. Motor strength was normal except for mild weak plantar flexion bilaterally. Reflexes and sensation were intact and there was no Babinski reflex. The gait was somewhat broad-based and unsteady. An electromyogram disclosed only slight peroneal nerve slowing and no evidence of lower extremity or anal sphincter denervation.

Pantopaque myelography (fig. 2) demonstrated a high termination of the subarachnoid space at the L5 level with narrowing of the distal segment. No intrathecal mass was seen and the conus appeared normal.

Following myelography, the patient underwent a L3–L5 laminectomy and fascia lata duraplasty. At surgery, the termination of the dura at L5 appeared extremely tight and constricted. The filum terminale was not sectioned since it did not appear to be under tension. The patient tolerated the procedure well without any postoperative complication.

At a follow-up visit 7 weeks postsurgery, the parents reported a rapid improvement in the child's gait. She was able to run for the first time without any evidence of unsteadiness or incoordination. Further treatment subsequently included bilateral ureteronephrostomies and suprapubic cystostomy. At the last follow-up visit 6 months postsurgery, the gait was nearly normal. Lower extremity muscle strength and tone were within normal limits and the deep tendon reflexes were normal. Bladder catheterization was only occasionally needed.

Case 3

A 19-day-old boy was referred to the Medical College of Georgia for workup of a possible myelomeningocele. The infant was the product of a normal, uncomplicated pregnancy and delivery. Family

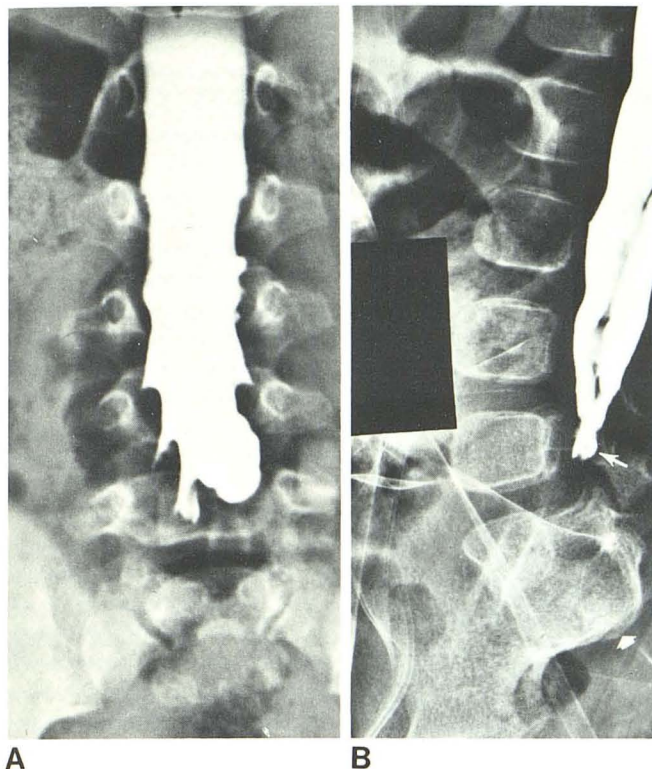


Fig. 2.—Case 2. **A**, Anteroposterior view. Tapered narrowing of subarachnoid space at middle of L5. Lumbar puncture needle hub superimposed on Pantopaque column. **B**, Lateral view. Sacral agenesis (*short arrow*) tapered subarachnoid space terminates behind L5 vertebral body (*long arrow*). Some leakage of Pantopaque around needle into posterior subdural space. Linear filling defect represents separation of subarachnoid Pantopaque anteriorly from subdural collection.

history was negative for diabetes mellitus or birth defects. At birth, a soft, slightly protuberant mass over the lumbosacral region was noted with an overlying dimple. Neonatal neurologic examination was otherwise within normal limits. Radiographs of the spine demonstrated absence of the right hemisacrum. Excretory urography and CT of the head were normal.

The patient was readmitted at age 2 months for myelography, spinal exploration, and excision of the sacrodermal sinus. Physical examination remained within normal limits except for the presence of the sacral soft tissue mass and dimple, and the neurologic examination was normal.

Pantopaque myelography (fig. 3) demonstrated normal termination of the subarachnoid space at the S2 level. However, at the inferior aspect the subarachnoid space appeared irregular, suggestive of an intraarachnoid mass. The conus ended at the upper border of L4 and the filum terminale appeared somewhat thickened.

At surgery, the sacrodermal sinus was explored and noted to extend medially and superiorly through the center of a lipoma to end extradurally at the L5–hemi-S1 interspace level. Superiorly the lipoma and sinus tract blended intimately with thickened tissue overlying the bony defect. The sinus was excised and subtotal excision of the lipoma was performed. On opening the dura, adhesive arachnoidal bands were found and a large filum terminale identified that appeared taut and was transected. The intrathecal contents otherwise appeared normal.

At a 2 month follow-up, the infant was doing well and appeared neurologically intact.

Case 4

A 6-year-old girl was admitted to the North Carolina Memorial Hospital of the University of North Carolina for evaluation of urinary incontinence. The patient had a mild gait disturbance and marked pronation of both feet. An excretory urogram demonstrated agenesis of the sacrum below S3 and normal upper collecting structures. Cystometrography showed a very small capacity spastic neurogenic bladder. Air myelography was subsequently performed (fig. 4) and a posterior meningocele was found at the S3 level. In addition, the spinal cord extended distally to the S2 level. Surgery was not performed.

Discussion

The clinical features of sacral agenesis have been well described [10–19]. The association with maternal diabetes mellitus has been a subject of interest for some time [20–22], and was present in one of our four cases. It appears that sacral agenesis results from a combination of teratogenic insult plus underlying genetic susceptibility of the developing fetus [8].

In the human embryo, somite formation occurs in a cephalad to caudad progression with sacral and coccygeal elements being the last to appear at about 31 days gestation [23]. The neural tube and notocord have been shown to exert inductive influences on the developing axial skeleton, and the mesodermal substratum similarly has a major influence on the process of neurulation [23]. Although the relation between sacral agenesis and spinal dysraphism is not entirely clear, embryologic data support the hypothesis that agenesis represents one aspect of the spectrum of congenital abnormalities related to defects in closure of the dorsal midline. In view of the known mutual inductive influence of the developing axial skeleton and the central nervous system, it is not surprising that bony agenesis might be found in association with failure of development of the dural sac, resulting in an abrupt high termination of the dura at or near the level of the last normally formed vertebral segment. This general correspondence between the point at which the nervous system ends and the level of bony aplasia, for varying degrees of lumbosacral agenesis, has been recognized for some time [21, 24, 25].

Reports of myelography or of abnormal termination of the dural sac have been very infrequent in the previous literature of sacral agenesis. Four reports have described the myelograms in a total of six patients, with illustration given for four of these. In the two patients from the recent report of Pang and Hoffman [9], preoperative myelography demonstrated a dural sac stenosis in one patient, and the other patient was found to have a tethered cord and a cauda equina cyst. One of eight cases reported by Koontz and Prout [26] was stated to have had several normal myelograms although illustration was not given. Lourie [27] reported two patients and illustrated the myelograms in one. In both cases, a high termination of the subarachnoid space at the L5 level was found. It was stated that the conus could not be identified, and neither patient had surgery. The only other illustration of a myelogram was given by Tanden and Lall [24]. Their case had absence of the sacrum below the S1 level and the myelogram showed the subarachnoid space to end at L4.

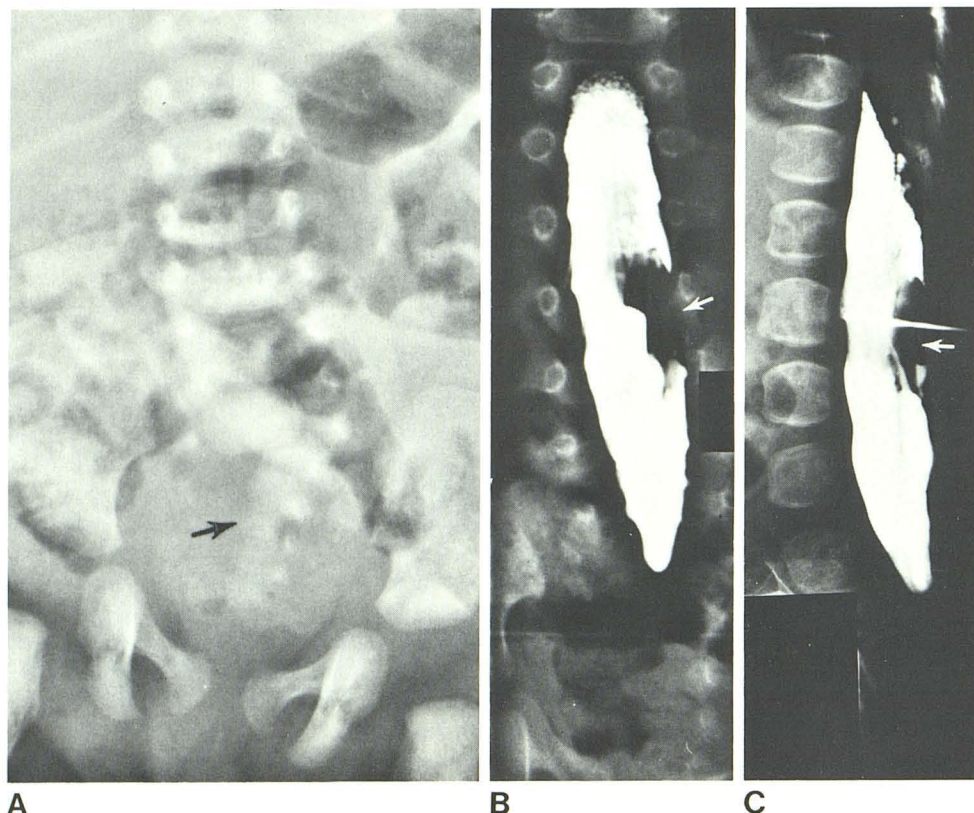


Fig. 3.—Case 3. **A**, Anteroposterior view of lumbosacral spine. Right hemiactomy of sacrum (arrow). **B**, Overpenetrated posteroanterior lumbar myelogram. Low position of spinal cord termination in intradural filling defect at L4–L5 (arrow). **C**, Lateral Pantopaque myelogram. Termination of subarachnoid space at S2. Posterior filling defect (arrow), thought to represent intradural lipoma, was actually extradural at surgery.

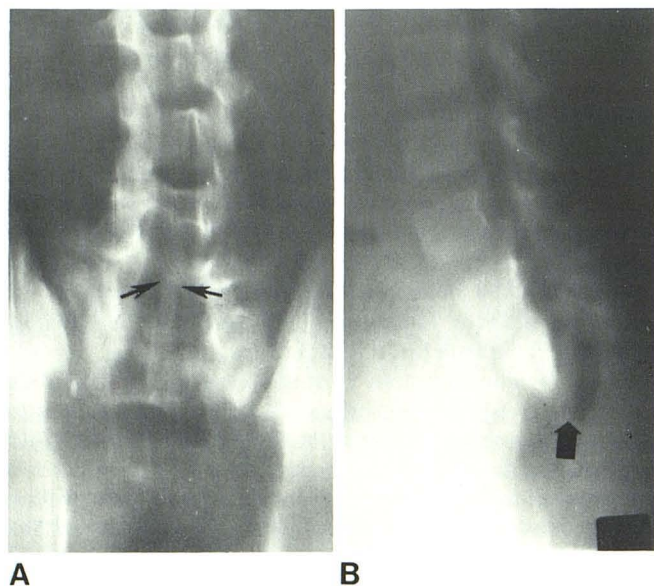


Fig. 4.—Case 4. **A**, Anteroposterior tomogram. Low spinal cord in wide subarachnoid space (arrows). **B**, Lateral tomogram. Agenesis of sacrum and air within sacral meningocele (arrow).

At surgery, the spinal cord was also noted to be low in position at L4 and the filum terminale was described as being "well-developed." No other extradural or intradural abnormality was found and there was no change postoperatively in the neurologic status of the patient.

One surgical and two autopsy reports have also described high termination of the subarachnoid space in sacral agenesis, although pre and postoperative myelography was not performed in any of these patients. Alexander and Hashold [28] gave an operative report of a case with five lumbar vertebrae and an absent sacrum in which termination of the thecal sac at L2–L3 level was noted at surgery; however, a stenosis of the sac at its termination was not specifically described. No intrathecal abnormality was seen. The nerve roots below the termination were embedded in fat and no change in the neurologic status of the patient was noted postoperatively. An autopsy report by Price et al. [29] described abrupt termination of the spinal cord at L2 without the normal tapering to the conus medullaris. Pathologically, it was noted that the degree of spinal cord dysplasia increased as the termination of the cord was approached. The appearance of the thecal sac was not described. An essentially identical appearance at autopsy was also reported by Abraham [30] in a 7-day-old infant with complete agenesis below a hypoplastic L3 vertebra. The conus medullaris ended abruptly at T11 and the dural sac had an abrupt termination at L2. The appearance of the conus in the first patient of this report is similar to these two autopsy descriptions, and was surgically confirmed. To our knowledge, case 1 represents the first time this myelographic finding has been described in sacral agenesis.

The myelographic findings in these cases can be divided into two categories. The first two patients had myelographically demonstrated dural sac stenosis that was surgically

confirmed, and both benefited from a duraplasty. These cases are similar to case 1 of Pang and Hoffman [9]. There was remarkable improvement in the degree of neurologic deficit after the surgery in all of these cases. The second category is represented by cases 3 and 4, similar to case 2 of Pang and Hoffman. Such cases have radiologic features of spinal dysraphism, with a tethered spinal cord, but are without a dural sac stenosis, and would probably benefit from surgical release of the tethered cord. In case 3, a thickened filum that appeared to be under tension was transected and adhesive arachnoidal bands in the distal thecal sac were released. No other significant intrathecal abnormality was found in this patient. Case 4 similarly had termination of the thecal sac at a normal level but with a low lying tethered spinal cord and a posterior meningocele. Case 2 of Pang and Hoffman also had a markedly thickened filum tethering the conus.

Although used in only one of our four patients and one of the two cases reported by Pang and Hoffman, Amipaque is believed to be the superior contrast medium for myelography in these children. This is due to both the better delineation of intradural contents and the easier identification of the conus it affords. Additional information in transaxial projection may also be obtained by following the Amipaque myelogram with a CT scan, as was done in case 1.

Our cases and review of the literature of sacral agenesis appear to indicate that the myelographic findings could be divided into two categories. One group has high termination of the subarachnoid space with a stenosis of the dural sac, while in the other the subarachnoid space may be normal or widened, and features classically associated with spinal dysraphism, including tethered cord, meningocele, and congenital tumors, are present.

ACKNOWLEDGMENTS

We thank James Scatliff, University of North Carolina, for case 4 and Joanne Aitken for assistance in manuscript preparation.

REFERENCES

- Blumel J, Evares EB, Eggers GWN. Partial and complete agenesis or malformation of the sacrum with associated anomalies. *J Bone Joint Surg [Am]* **1959**;41:497-518
- Lichter A. Sacral agenesis: report of a case. *Arch Surg* **1947**;54:430-433
- Banta JV, Nichols O. Sacral agenesis. *J Bone Joint Surg [Am]* **1969**;51:693-703
- White RI, Klauber GT. Sacral agenesis. *Urology* **1976**;8:521-525
- Renshaw TS. Sacral agenesis: a classification and review of twenty-three cases. *J Bone Joint Surg [Am]* **1978**;60:373-383
- Braren V, Jones WB. Sacral agenesis: diagnosis, treatment and follow up of urological complications. *J Urol* **1978**;121:543-544
- Mariani AJ, Stern J, Khan AU, Cass AS. Sacral agenesis: an analysis of 11 cases and review of the literature. *J Urol* **1978**;122:684-686
- Andrish J, Kalarnci A, MacEwen GD. Sacral agenesis: a clinical evaluation of its management, heredity and associated anomalies. *Clin Orthop* **1979**;139:52-57
- Pang D, Hoffman HJ. Sacral agenesis with progressive neurological deficit. *Neurosurgery* **1980**;7:118-126
- Duhamel B. From the mermaid to anal imperforation: the syndrome of caudal regression. *Arch Dis Child* **1961**;36:152-155
- Zeligs IM. Congenital absence of the sacrum. *Arch Surg* **1940**;41:1220-1228
- Williams DI, Nixon HH. Agenesis of the sacrum. *Surg Gynecol Obstet* **1957**;105:84-88
- Pirkey EL, Purcell JH. Agenesis of lumbosacral vertebrae: a report of two cases in living infants. *Radiology* **1957**;69:726-729
- Smith ED. Congenital sacral anomalies in children. *Aust NZJ Surg* **1959**;29:165-176
- Korobkin M, Novick P, Palubinskas AJ. Asymptomatic sacral agenesis with neurogenic bladder in a 42-year-old man. *AJR* **1972**;115:611-613
- Thompson IM, Kirk RM, Dale M. Sacral agenesis. *Pediatrics* **1974**;54:236-238
- Sarnat HB, Case ME, Graviss R. Sacral agenesis: neurologic and neuropathologic features. *Neurology (NY)* **1976**;26:1124-1129
- Barnes JC, Smith WL. The Vater association. *Radiology* **1978**;126:445-449
- Stanley JK, Owen R, Koff S. Congenital sacral anomalies. *J Bone Joint Surg [Br]* **1979**;61:401-409
- Rusnak SL, Driscoll SG. Congenital spinal anomalies in infants of diabetic mothers. *Pediatrics* **1965**;35:989-995
- Russell HE, Aitken GT. Congenital absence of the sacrum and lumbar vertebral with prosthetic management. *J Bone Joint Surg [Am]* **1963**;45:501-508
- Passarge E, Lenz W. Syndrome of caudal regression in infants of diabetic mothers: observations of further cases. *Pediatrics* **1966**;37:672-675
- Kallen B. Early embryogenesis of the central nervous system with special reference to closure defects. *Dev Med Child Neurol [Suppl]* **1968**;16:44-53
- Tandon PN, Lall BN. Agenesis of the sacrum and coccyx. *Indian Pediatr* **1968**;5:274-276
- Ignelzi RJ, Lehman RAW. Lumbosacral agenesis: management and embryological implications. *J Neurol Neurosurg Psychiatry* **1974**;37:1273-1276
- Koontz WW, Prout GR. Agenesis of the sacrum and the neurogenic bladder. *JAMA* **1968**;203:481-486
- Lourie H. Sacral agenesis: case report. *J Neurosurg* **1973**;38:92-95
- Alexander E, Nashold BS. Agenesis of the sacrococcygeal region. *J Neurosurg* **1956**;13:507-513
- Price, DL, Dooling EC, Richardson EP. Caudal dysplasia (caudal regression syndrome). *Arch Neurol* **1970**;212-220
- Abraham E. Lumbosacral coccygeal agenesis: autopsy case report. *J Bone Joint Surg [Am]* **1976**;58:1169-1171