



Get Clarity On Generics

Cost-Effective CT & MRI Contrast Agents



FRESENIUS
KABI

WATCH VIDEO

AJNR

Hemangioblastoma of the optic nerve: radiographic and pathologic features.

G J Lauten, J B Eatherly and A Ramirez

AJNR Am J Neuroradiol 1981, 2 (1) 96-99

<http://www.ajnr.org/content/2/1/96.citation>

This information is current as
of August 8, 2025.

Hemangioblastoma of the Optic Nerve: Radiographic and Pathologic Features

Gregory J. Lauten,¹ Joseph B. Eatherly,² and Archimedes Ramirez³

Hemangioblastomas are well described neoplasms of the central nervous system usually involving the cerebellum. These tumors occur less frequently in other locations such as the spinal cord, medulla, and cerebral hemisphere. A hemangioblastoma arising in the optic nerve is distinctly unusual; only three have been reported [1-3]. None of these reports includes radiographic findings.

Case Report

A 15-year-old black boy had decreasing visual acuity and progressive proptosis in the left eye for 6 months. Physical examination showed a mildly proptotic left eye with light perception only, a Marcus Gunn pupil, and a pale disc on funduscopy. The right eye was entirely normal. There was no history or physical stigmata of neurofibromatosis or von Hippel-Lindau disease.

Optic canal tomograms (fig. 1) revealed marked concentric enlargement of the left optic canal throughout its length. The left canal measured 12-13 mm, and the right canal measured 5-6 mm with correction for polytome magnification. Computed tomography (EMI 5005) in the axial and coronal planes (fig. 2) showed a tumor mass extending intracranially from the left optic canal toward the optic chiasm.

A diagnosis of optic nerve glioma was entertained. Because excisional biopsy of this lesion was contemplated, cerebral angiography was performed. Selective injections of Conray 60 (Mallinckrodt) were done in the left internal carotid, left external carotid, right common carotid, and left vertebral arteries, with serial filming in frontal and lateral projections (fig. 3). Films revealed a part of the tumor (intracanalicular and intracranial) to be highly vascular with a dense, homogenous stain and an early draining deep vein.

At craniotomy a highly vascular tumor was found occupying the apex of the orbit, the optic canal, and bulging intracranially toward the optic chiasm. The optic nerve was resected from the globe to just in front of the chiasm. On gross examination, the "optic nerve" tissue consisted of a reddish-brown hemorrhagic fragment measuring 1.5 × 1.0 × 0.5 cm. The entire specimen was submitted for

microscopic study. A fragment of brown "dura" tissue measured 1.5 × 0.5 × 0.3 cm. Microscopic studies revealed a well circumscribed, unencapsulated tumor entirely within the optic nerve, compressing the surrounding nerve fibers. The tumor consisted of several blood-filled channels, most of which were of capillary size. Larger vessels with thin, muscular coats were also observed. Reticulin, silver, and paraaminosalicylic acid stains showed these channels, both large and small, to be lined by endothelium and supported by a reticulin framework, verifying them as blood vessels. There was no involvement of the leptomeninges, and examination of the dural fragment showed no pathologic changes. Postoperatively the patient has done well; his left eye is cosmetically normal with no proptosis, and his right eye remains normal.

Discussion

Hemangioblastoma, an uncommon primary tumor of the central nervous system, represents 1%-2% of intracranial neoplasms. With a peak incidence in the 20-50 year age group, it constitutes perhaps 7%-10% of primary posterior fossa tumors [4].

The most common location of hemangioblastoma is in the cerebellum, usually in a hemisphere. Less common sites are the spinal cord and medulla where a hemangioblastoma of the cord may be associated with an adjacent syringomyelic cavity [5]. Supratentorial hemangioblastomas are rare, with only seven well documented cases in the literature [6, 7]. About 60%-80% of hemangioblastomas are cystic, the tumor nodule lying in the wall of the cyst.

Only 15%-20% of patients with a solitary cerebellar hemangioblastoma are found to have family history or physical stigmata of von Hippel-Lindau disease. However, if the tumors are multiple (about 10% of the time), the patient's chances of having von Hippel-Lindau disease are greater.

Three cases of hemangioblastoma of the optic nerve have

Received March 25, 1980; accepted after revision June 24, 1980.

The opinions or assertions contained herein are the private views of the authors and are not to be construed as official or as reflecting the views of the Department of the Army or the Department of Defense.

¹Department of Radiology, Letterman Army Medical Center, Presidio of San Francisco, CA 94129. Present address: Department of Radiology, Chico Community Memorial Hospital, Chico, CA 95926. Address reprint requests to Technical Publications Editor, Letterman Army Medical Center.

²Department of Pathology, Letterman Army Medical Center, Presidio of San Francisco, CA 94129.

³Department of Surgery, Neurosurgery Service, Letterman Army Medical Center, Presidio of San Francisco, CA 94129.

Fig. 1.—Optic canal tomograms. **A**, Normal right optic canal 5 mm in diameter. **B**, Concentrically enlarged left optic canal 12 mm in diameter. Cortical thinning.

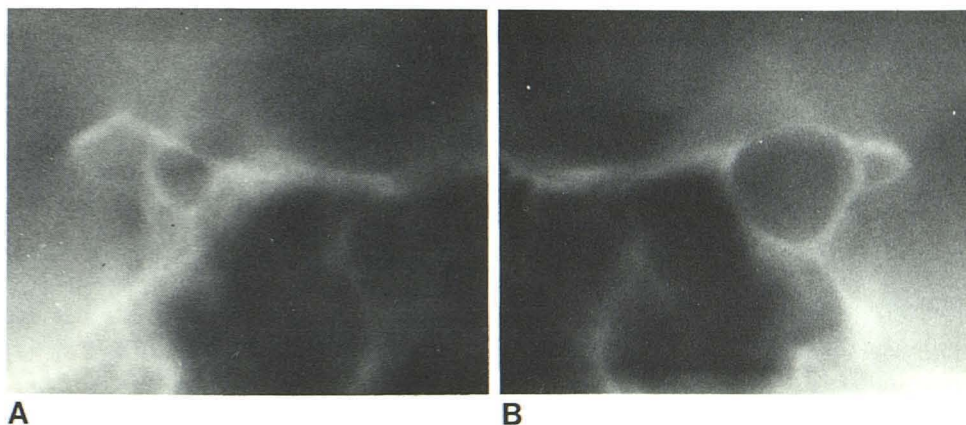
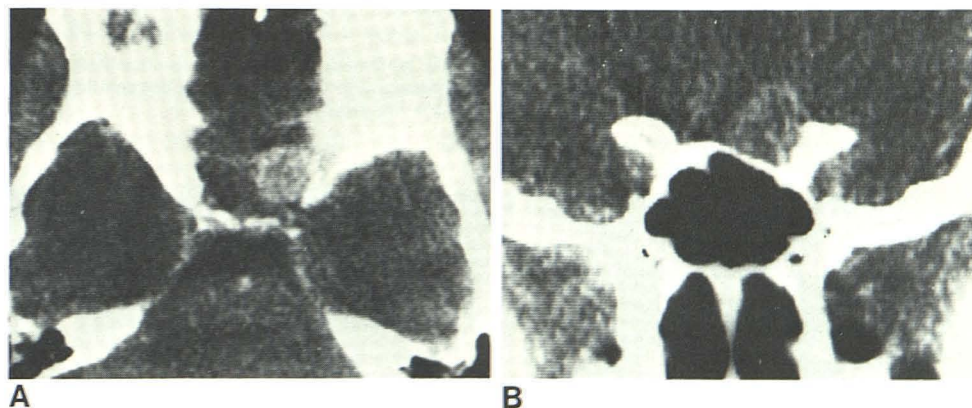


Fig. 2.—**A**, Axial section through sellar area. Mass extends intracranially and suprasellarly toward optic chiasm. **B**, Direct coronal section. Mass projects upward from optic canal intracranially, eroding planum sphenoidale and medial aspect of anterior clinoid.



been reported, all in the European literature [1–3]. Two involved only the intracranial prechiasmal part of the optic nerve and were discovered at necropsy. The third involved the intraorbital part of the optic nerve and was surgically resected. Two of the three cases were associated with von Hippel–Lindau stigmata and family history.

Radiology

Concentric enlargement of an optic canal may be seen in many conditions [8], the most common of which is optic glioma. This tumor may or may not be associated with neurofibromatosis. Intracanalicular meningiomas in older patients or primary orbital tumors extending posteriorly may enlarge the canal. Vascular abnormalities such as ophthalmic artery aneurysm or arteriovenous malformation of the optic nerve can also produce this change.

The CT scan in our patient showed a mass, inseparable from the optic nerve, extending from within the orbit to the optic chiasm throughout the optic canal. The CT narrowed the differential diagnosis to optic nerve tumor, with optic glioma the most likely possibility in this young patient.

Angiographic findings of a densely staining tumor mass with early draining veins would be quite remarkable for an optic glioma. Optic gliomas tend to be hypovascular on

angiography and do not have early draining veins, the only angiographic findings being displacement and stretching of the ophthalmic artery. The angiographic appearance in our patient is compatible with an angioblastic meningioma of the optic nerve or a hemangioblastoma (although the latter has no published angiographic documentation). Conceivably, a hypervascular lesion metastatic to the optic nerve (e.g., melanoma or renal cell carcinoma) could produce this angiographic appearance; however, our patient had no such primary tumor.

Pathology

The lesion described here is a neoplasm composed of blood vessels, which justifies the name hemangioblastoma [9]. Substantiating this term are the large numbers of minute capillaries and larger vessels, all of which are lined by endothelium and supported by a reticulin framework. Hemangioblastoma, however, requires differentiation from angioblastic meningioma and microcystic glioma [10, 11].

Hemangioblastomas and angioblastic meningiomas are often quite similar histologically, and macroscopic features must be used to help differentiate them [10]. Regardless of their location in the brain, hemangioblastomas are usually completely encased by nervous tissue; figure 4A shows the

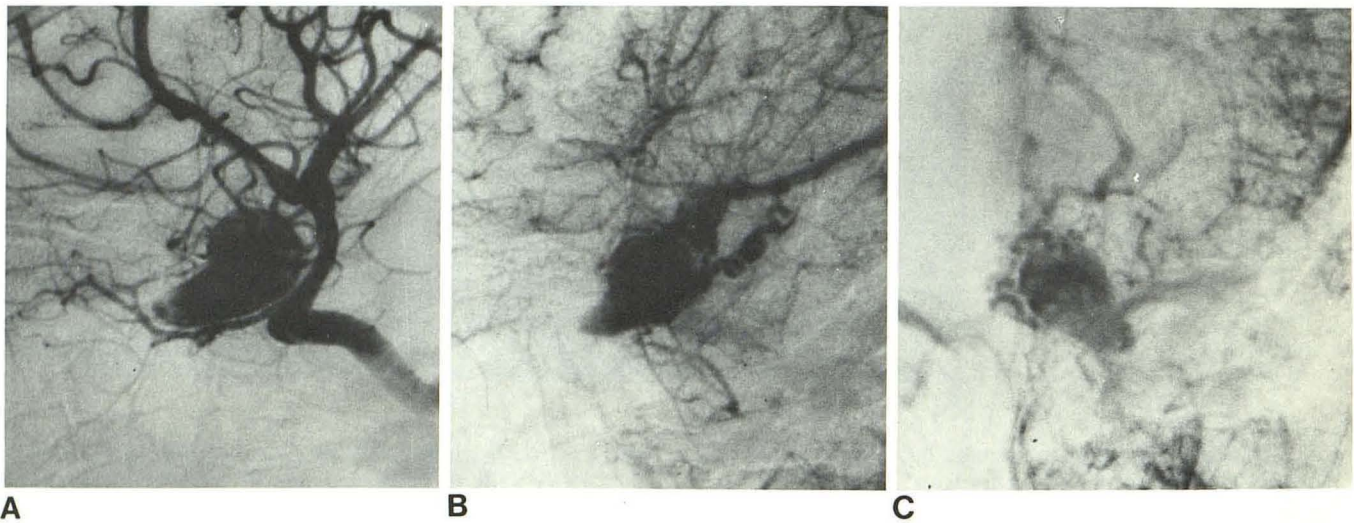


Fig. 3.—Cerebral angiogram, left internal carotid injections. **A**, Lateral, arterial phase. Densely vascular tumor supplied by ophthalmic artery branches. **B**, Lateral, late arterial phase. Early venous drainage into basal

vein of Rosenthal (deep supratentorial system). **C**, Frontal, capillary phase. Tumor in optic canal bulges superiorly and posteriorly intracranially with early vein.

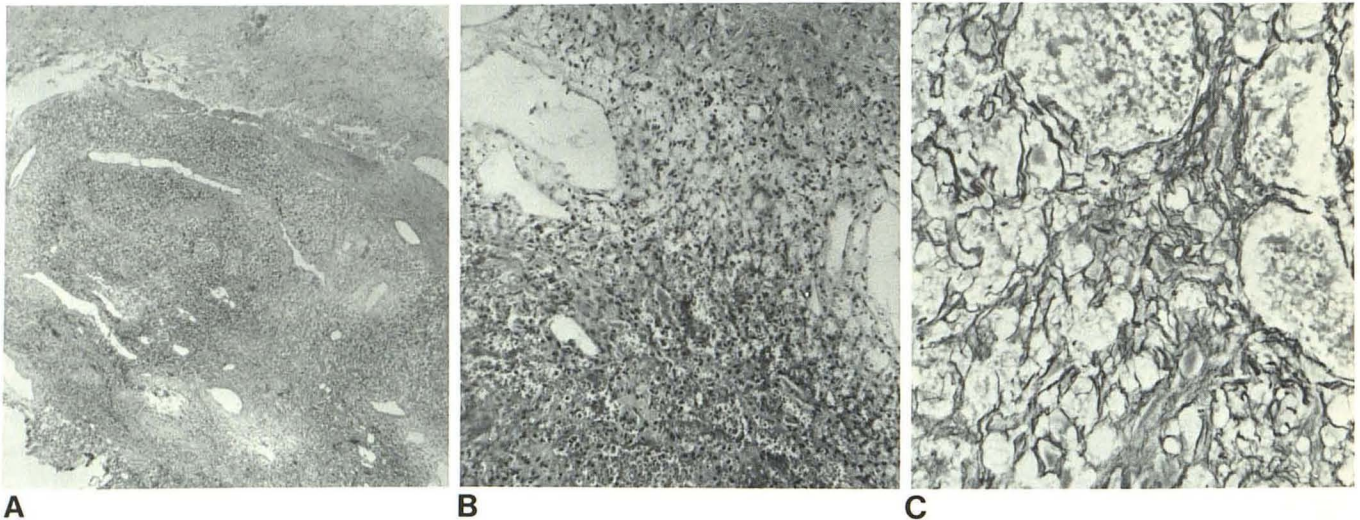


Fig. 4.—**A**, Low power view. Well demarcated tumor bordered entirely by nerve. Large vascular channels easily seen. H and E $\times 35$. **B**, Higher power. Tumor composed mostly of capillary-size vessels which contain red blood

cells. $\times 400$. **C**, Reticulin stain. Loose connective tissue interspaced between prominent vascular channels.

tumor to lie completely within the optic nerve. Conversely, angioblastic meningiomas usually do not lie entirely within neural tissue and are easily separated by blunt dissection [10]. Definite attachment of the hemangioblastoma to the meninges is rarely demonstrated, whereas the angioblastic meningioma is often found to be broadly attached to the arachnoid and usually to the dura mater [10]. In our patient, the meninges around the specimen of optic nerve and a second dural fragment were uninvolved with the tumor. The margin of a hemangioblastoma is defined by surrounding compressed neural tissue without a capsule [12, 13]. An angioblastic meningioma, however, has an obvious capsule made of dense fibrous tissue which clearly separates it from

neural tissue [10]. In figure 4B, the neoplasm is shown to lack a capsule and is defined only by the compressed nerve.

Gliomas occur in three basic histologic patterns: solid acellular tissue without any vascularity; a highly cellular pattern with some vascular proliferation; and an open honeycombed pattern made of microcysts. The latter may be confused with an hemangioblastoma. The microcysts, however, are not supported by a reticulin framework (fig. 4C), are not lined by endothelium, and do not contain red blood cells (fig. 4C). Gliomas have been described as solitary tumors within the optic nerve alone [11]. But no glioma, regardless of location, has been described with the degree of vascular proliferation found in the lesion here.

Generalized angiomatosis of the central nervous system occurs in the familial von Hippel-Lindau syndrome. This name is usually applied to a combination of angiomas of the retinae, hemangioblastomas of the cerebellum or spinal cord, pancreatic and renal cysts, cellular skin nevi, and optionally renal cell carcinoma [14, 15]. Lindau hemangioblastoma occurs as a solitary lesion in the cerebellum or spinal cord [15].

This is a rare case of a solitary hemangioblastoma occurring in the optic nerve without other associated diseases. The tumor is completely localized within the nerve, is unencapsulated, and has no attachment to the arachnoid or dura. It is a neoplasm made of endothelial-lined blood vessels.

REFERENCES

1. Verga P. Angio-reticolo-glioma cistico del nervo ottico. *Rev Otoneuroophthalmol* **1930**;7:101-133
2. Schneider R. Angioretikulum des Schnerven. *Graefes Arch Ophthalmol* **1942**;145:163-178
3. Stefani FH, Rothmund E. Intracranial optic nerve angioblastoma. *Br J Ophthalmol* **1974**;58:823-827
4. Melmon KL, Rosen SW. Lindau's disease: review of the literature and study of a large kindred. *Am J Med* **1964**;36:595-617
5. Rubinstein LF. *Tumors of the central nervous system*, fasc 6, series 2. Washington DC: Armed Forces Institute of Pathology, **1972**:235-241
6. Morello G, Bianchi M. Cerebral hemangioblastomas. Review of literature and report of two personal cases. *J Neurosurg* **1963**;20:254-264
7. Hoff JT, Ray BS. Cerebral hemangioblastoma occurring in a patient with von Hippel-Lindau disease. Case report. *J Neurosurg* **1968**;28:365-368
8. Potter GD, Trokel SL. Optic canal. In: Newton TH, Potts DG, eds. *Radiology of the skull and brain*, vol 1, book 2. St. Louis: Mosby, **1971**:492-496
9. Baily OT, Ford R. Sclerosing hemangiomas of the central nervous system. Progressive tissue changes in hemangioblastomas of the brain and in so-called angioblastic meningiomas. *Am J Pathol* **1942**;25:1-26
10. Corrandini EW, Browder J. Angioblastic meningiomas of the brain. *J Neuropathol* **1948**;7:299-308
11. Desousa AL, Kalsbeck JE, Mealey J, Ellis ED, Muller J. Optic chiasmatic glioma in children. *Am J Ophthalmol* **1979**;87:376-381
12. Stefani FH, Rothmund E. Intracranial optic nerve angioblastoma. *Br J Ophthalmol* **1974**;58:823-827
13. Darr JL, Hughes RP, McNail JN. Bilateral peripapillary retinal hemangiomas. A case report. *Arch Ophthalmol* **1966**;75:77-81
14. Zülch KG, Mennel HD. von Hippel-Lindau syndrome. In: Vinken PG, Bruyn GW, eds. *Handbook of clinical neurology*, vol 16. Amsterdam: North Holland, **1974**:31
15. Lichenstein BW. Hamartomas and phacomatoses. In: Minckler J, ed. *Pathology of the nervous system*, vol 3. New York: McGraw-Hill, **1974**:1899-1901