



## Get Clarity On Generics

Cost-Effective CT & MRI Contrast Agents

 FRESENIUS  
KABI

[WATCH VIDEO](#)

# AJNR

## Small isolated paraspinal arteriovenous fistula.

C J Chen, C C Huang, Y Y Hsu and W C Hsu

*AJNR Am J Neuroradiol* 1997, 18 (2) 359-361

<http://www.ajnr.org/content/18/2/359>

This information is current as  
of August 18, 2025.

# Small Isolated Paraspinal Arteriovenous Fistula

Chi-Jen Chen, Chin-Chang Huang, Yuan-Yu Hsu, and Wen-Ching Hsu

**Summary:** We report a case of a small, isolated, paraspinal arteriovenous fistula (AVF) that arose in an adult without obvious trauma. The fistula, despite its extraspinal location and small size, caused hypertension of the intrathecal venous system and produced symptoms that were similar to those of spinal dural AVF. Detecting such a small lesion is difficult, but contrast-enhanced MR imaging can prove helpful in this regard.

**Index terms:** Arteriovenous malformation, spinal; Fistula, arteriovenous

Vascular malformations in the spine and spinal cord are classified by type according to topographic criteria; they include canalicular, vertebral, paraspinal, and complex types (1). Among them, the spinal canal is the best-documented site, and arteriovenous fistulas (AVFs) in this location have been further classified, with various prognoses (2, 3). However, paraspinal lesions, especially the isolated type, are much less common and less well documented (4–6). They may be congenital (4, 5) or posttraumatic (6). We describe a small, isolated, adult-onset paraspinal AVF in a patient with no obvious history of trauma. The pathophysiology of the fistula and the mechanism of its symptoms are discussed.

## Case Report

A 39-year-old man entered our emergency department with numbness of his palms and soles and weakness of his right limbs. He had been experiencing numbness of his distal extremities off and on for 1 month with an increase of these symptoms over the preceding 10 days. His history was unremarkable except for hypertension, for which he had been receiving regular treatment for 3 years. There was no obvious history of trauma.

Physical and neurologic examinations revealed normal cranial nerve, motor, and sensory functions. Tendon and other reflexes were normal; however, subjective numbness of the distal extremities was noted. Sphincter function was

normal. Myelography, performed for possible cervical radiculomyelopathy, revealed no obvious indentation at the cervical thecal sac, but some serpentine filling defects at the posterior aspect of the lower thoracic subarachnoid space was noted (Fig 1A).

Unenhanced magnetic resonance (MR) imaging of the spine at 1.5 T showed neither obvious cord edema nor serpentine flow void signals, but a herniated disk at the T12-L1 disk level was seen. After administration of contrast material, some dotlike enhancement was noted along the dorsal surface of the lower thoracic cord on sagittal T1-weighted images (400/22/2 [repetition time/echo time/excitations]) (Fig 1B). Prominent paravertebral and internal anterior venous plexuses were noted at the T-12 level on sagittal and axial contrast-enhanced T1-weighted images (400–450/22–30/2) (Fig 1C and D). Spinal angiography, performed for a suspected spinal vascular malformation, showed an arteriovenous shunt on the left T-12 intercostal artery injection (Fig 1E). Moreover, superselective catheterization with a microcatheter proved the existence of a paraspinal AVF that originated from a proximal ventral branch of the left T-12 intercostal artery and drained into the external epidural venous plexuses (Fig 1F and G). Embolization was performed with *N*-butyl cyanoacrylate, resulting in successful obliteration of the fistula.

On the second day after embolization, distal numbness was improved; 1 month later, the patient was completely free of symptoms.

## Discussion

Paraspinal vascular malformations (arteriovenous malformations or fistulas) may involve the paravertebral musculature, nerve root foramina, prevertebral region, and even the spinal canal (1, 4–7). Clinically, they may present as a subcutaneous pulsating mass in the region of the paravertebral musculature (7), a bruit discovered on physical examination (1), heart failure (5), swallowing difficulty due to a lump in the neck (5), or progressive myelopathy (5). These malformations may be isolated AVFs or

Received January 8, 1996; accepted after revision April 23.

From the Departments of Radiology (C.-J.C., Y.-Y.H., W.-C.H.) and Neurology (C.-C.H.), Chang Gung Memorial Hospital and Medical College, Taipei, Taiwan.

Address reprint requests to Chi-Jen Chen, MD, Department of Radiology, Chang Gung Memorial Hospital, 199 Tung Hwa North Road Taipei, Taiwan.

AJNR 18:359–361, Feb 1997 0195-6108/97/1802-0359 © American Society of Neuroradiology

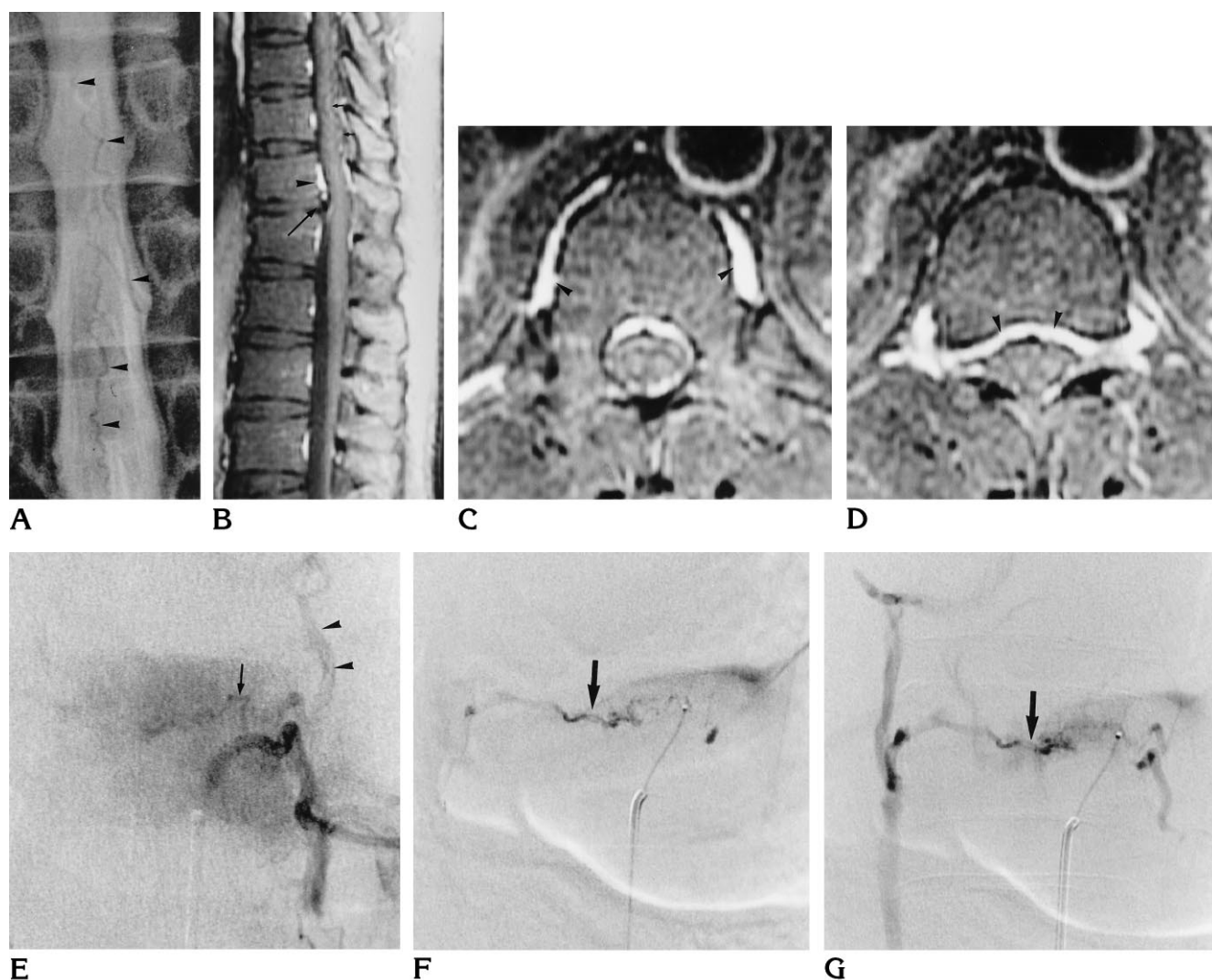


Fig 1. A 39-year-old man with 1-month history of numbness of the extremities.

A, Supine myelogram shows serpentine filling defects (*arrowheads*) at dorsal aspect of the cord, suggesting the possibility of spinal arteriovenous malformation.

B–D, Contrast-enhanced T1-weighted MR images (400–450/22–30/2) show dotlike or linear enhancement at the posterior surface of the spinal cord from T-9 to T-12 (*small arrows* in B). Prominent paravertebral and internal anterior venous plexuses are noted at the T-12 level (*arrowheads* in B, C, and D). A herniated disk is noted at the T12–L1 disk level (*long arrow* in B).

E, Spinal angiogram of the left T-12 intercostal artery shows a small tortuous vessel (*arrow*) originating from the early course of the T-12 intercostal artery. Note opacification of the epidural venous plexuses (*arrowheads*) due to the existence of an arteriovenous shunt.

F and G, Anteroposterior views of superselective spinal angiograms with microcatheter at the small tortuous vessel show the arteriovenous fistula (*arrows*).

part of the metameric angiomatosis (1, 4–7). An isolated AVF, whether congenital or post-traumatic, usually has a large shunt (5, 6); however, in our patient, it was very small. The AVF had its onset in adulthood and was unrelated to trauma, different from the common AVF. Thus, a different pathogenesis, other than congenital or traumatic, is possible. Was this fistula, similar to intracranial dural AVFs, caused by a preexisting restriction of the venous drainage and a

pathologic recanalization (8, 9)? A herniated disk at the T12–L1 level, which could possibly restrict the venous drainage, may support this assumption; however, more cases are needed to confirm this possibility.

Regarding the mechanism of the myelopathy induced by the paraspinal AVF, Hui et al (5) suggested that AVFs in the paravertebral region may communicate with the veins of the spinal cord via the epidural venous plexus. High pres-

sure in the paraspinal veins can then be transmitted to the veins of the spinal cord and produce congestion of the cord. This hypothesis is counter to the protective valvular mechanism that is suggested by the many epidural venograms performed in the late 1970s. These venograms showed that the spinal medullary veins are not normally opacified by epidural venous injection. However, reflux into the spinal medullary veins from extraspinal injections has been shown by Tadie et al (10) in cases of spinal dural AVFs. That is to say, this venous protective system can be impaired under anomalous conditions. Therefore, while unusual, it is possible that the paraspinal fistula in our case drained into the epidural venous plexus, causing medullary venous hypertension.

Paraspinal arteriovenous shunts are uncommon, and there is no classical presentation (1, 4–7), which makes the diagnosis difficult, especially when the shunt is small. In our patient, the symptoms were so vague that neurosis was even considered. However, correct identification of these lesions can be facilitated by the use of such diagnostic techniques as myelography, MR imaging, and angiography. Among these methods, contrast-enhanced MR imaging is a valuable tool, because it is noninvasive and can show not only the abnormally engorged intrathecal veins but also the engorged paraspinal venous system.

Embolization of an isolated paraspinal AVF via percutaneous catheterization is an accepted and effective treatment method (1, 2, 4, 5, 7, 11). In our patient, it was also a safe method, because the possibility of accidental occlusion of the spinal perimedullary vein was very un-

likely. Liquid agents are highly recommended because they can reduce the likelihood of collateral recruitment (11).

## References

1. Merland JJ, Reizine D, Laurent A, et al. Embolization of the spinal cord vascular lesions. In: Viñuela F, Halbach VV, Dion JE, eds. *Interventional Neuroradiology: Endovascular Therapy of the Central Nervous System*. New York, NY: Raven Press; 1992:153–167
2. Djindjian R. Clinical symptomatology and natural history of arteriovenous malformation of the spinal cord: a study of the clinical aspects and prognosis, based on 150 cases. In: Pia HW, Djindjian R, eds. *Spinal Angiomas: Advances in Diagnosis and Therapy*. New York, NY: Springer-Verlag; 1978:48–83
3. Roseblum B, Oldfield EH, Doppman JL, Di Chiro G. Spinal arteriovenous malformations: a comparison of dural arteriovenous fistula and intradural AVMs in 81 patients. *J Neurosurg* 1987;67:795–802
4. Casasco A, Houdart E, Gobin Y, Aymard A, Guichard J, Rufenacht D. Embolization of spinal vascular malformations. *Neuroimaging Clin N Am* 1992;2:337–358
5. Hui F, Trosselo MP, Meisel HJ, Alvarez H, Sequeira E, Lasjaunias P. Paraspinal arteriovenous shunts in children. *Neuroradiology* 1994;36:69–73
6. Cognard C, Semaan H, Bakchine S, et al. Paraspinal arteriovenous fistula with perimedullary venous drainage. *AJNR Am J Neuroradiol* 1995;16:2044–2048
7. Berenstein A, Lasjaunias P. *Surgical Neuroangiography: Endovascular Treatment of the Spine and Spinal Cord Lesions*. New York, NY: Springer-Verlag; 1992;5:56–60
8. Chaudhary MY, Sachdev VP, Cho SH, et al. Dural arteriovenous malformation of the major venous sinuses: an acquired lesion. *AJNR Am J Neuroradiol* 1982;3:13–19
9. Houser OW, Campbell JK, Campbell RJ, et al. Arteriovenous malformation affecting the transverse dural venous sinus: an acquired lesion. *Mayo Clinic Proc* 1979;54:651–661
10. Tadie M, Hemet J, Freger P, et al. Morphological and functional anatomy of spinal cord veins. *J Neuroradiol* 1985;12:3–10
11. Rosen JR, Riles TS, Berenstein A. Congenital vascular malformations. In: Rutherford RB, ed. *Vascular Surgery*. Philadelphia, Pa: Saunders; 1049–1106