



Get Clarity On Generics

Cost-Effective CT & MRI Contrast Agents



FRESENIUS
KABI

WATCH VIDEO

AJNR

Spontaneous decrease of a pilocytic astrocytoma in neurofibromatosis type 1.

E L Leisti, J Pyhtinen and M Poyhonen

AJNR Am J Neuroradiol 1996, 17 (9) 1691-1694

<http://www.ajnr.org/content/17/9/1691>

This information is current as
of August 22, 2025.

Spontaneous Decrease of a Pilocytic Astrocytoma in Neurofibromatosis Type 1

Eeva-Liisa Leisti, Juhani Pyhtinen, and Minna Poyhonen

Summary: A patient with type I neurofibromatosis was followed up with neuroimaging over a period of 12 years. A spontaneous decrease in the size of a histologically verified pilocytic astrocytoma was documented on serial CT and MR examinations. Subsequent studies showed the development of a lesion in the contralateral hemisphere with mass effect and contrast enhancement. Results of a biopsy disclosed normal brain tissue; follow-up imaging showed a spontaneous decrease in the size of this abnormality.

Index terms: Astrocytoma; Neurofibromatosis

A patient with type 1 neurofibromatosis (NF-1) had brain lesions that on computed tomographic (CT) and magnetic resonance (MR) studies at first decreased, then increased, and finally resolved over the course of 12 years. A brain biopsy was performed twice.

Case Report

A 21-year old man had been suffering from migraine-type headache since the age of 5 years. He was found to have café au lait spots of variable size, bilateral axillary freckling, several histopathologically verified neurofibromas, and Lisch nodules of the iris. The diagnosis was NF-1. The family history was negative.

At the age of 8 years 3 months the patient showed signs of clumsiness, poor concentration, and cephalalgia. (The head circumference was at the upper normal levels, 97.5%.) Psychological tests revealed mild mental retardation. Cerebral CT studies (Fig 1A and B) showed a tumor of the left temporal-hypothalamic region that was thought to be a glioma. Stereotactic brain biopsy confirmed a low-grade pilocytic astrocytoma. A small lesion was also seen in the right temporal-hypothalamic region. The chiasm was enlarged throughout the follow-up period. The patient was overactive and did not do well in school. At the age of 8 years 10 months, the brain lesions had decreased in size (Fig 1C), but they increased again until the age of 9 years 8 months (Fig 1D). A biopsy of the right-sided lesion performed at this time revealed normal brain tissue (Fig 1D). Precocious puberty was diagnosed at this age.

At the age of 11 years 3 months, CT scans showed nearly complete disappearance of the brain lesions (Fig 1E), and at the age of 16 years they were almost invisible. MR images of the brain at the age of 20 years showed traces of the brain biopsy, a very small area of abnormal signal in the right globus pallidus, and an enlarged chiasm (Fig 1F). Findings on spinal MR images were normal. At the age of 6 years, the neuroophthalmologic state was normal; but from the age of 8 years neuroophthalmologic findings were positive for mild atrophy of the papillae, temporal visual field defects on both sides, esophoria, and Lisch nodules. Currently, at age 21, the patient is asymptomatic, his vision is normal, and he has passed regular army service. He has many café au lait spots and some small cutaneous neurofibromas and freckling.

Discussion

NF-1 is a genetic disorder inherited in an autosomal dominant fashion, but about 50% of the cases are spontaneous mutations. The gene defect occurs in the pericentromeric region of chromosome 17q11.2 (1). Brain lesions, such as gliomas and optic nerve gliomas, are common in this condition, and there are other brain lesions that show a hyperintense signal on T2-weighted MR images and are thought to be hamartomas or areas of heterotopia, vascular alterations, or local abnormalities of myelination, although their nature is not known exactly (2–8). There is some evidence to suggest that at least a portion of these lesions found in childhood may resolve over time (9–11). Our patient showed signs that satisfied the diagnostic criteria for NF-1 established by the National Institutes of Health (12).

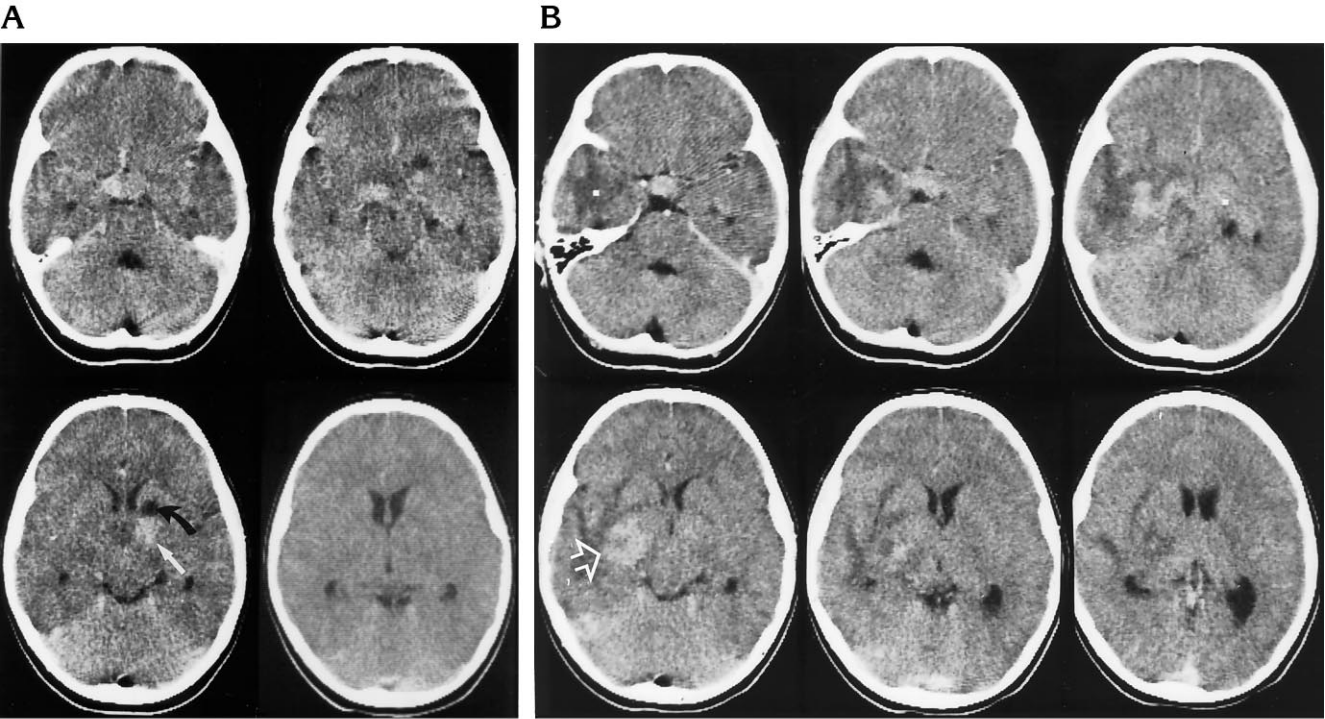
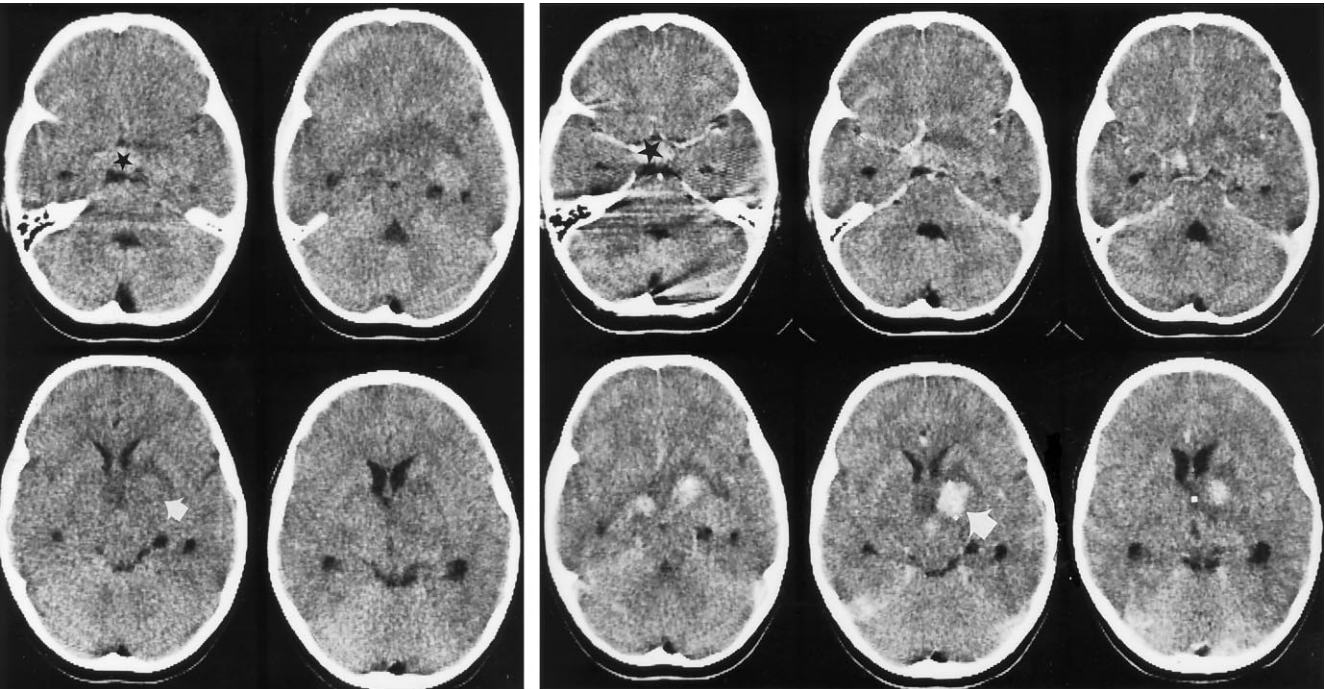
Our patient was followed up with brain CT from the age of 8 to 16 and with MR imaging at the age of 20 years. The brain lesions, one of them confirmed by biopsy findings to be a pilocytic astrocytoma, decreased in size from the

Received October 11, 1995; accepted after revision January 18, 1996.

From the Departments of Diagnostic Radiology (E.-L.L., J.P.) and Clinical Genetics (M.P.), University of Oulu (Finland).

Address reprint requests to Eeva-Liisa Leisti, MD, Department of Diagnostic Radiology, University of Oulu, Kajaanintie 50, FIN 90220, Oulu, Finland.

AJNR 17:1691–1694, Oct 1996 0195-6108/96/1709–1691 © American Society of Neuroradiology



C D

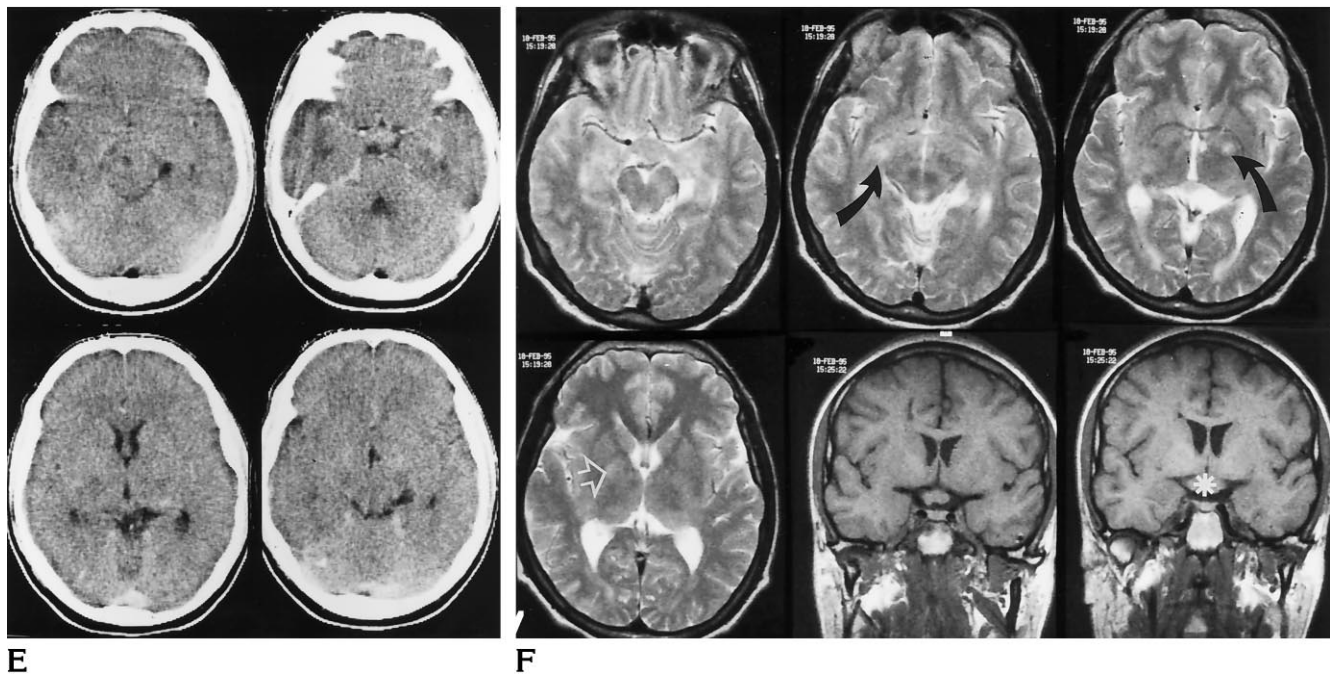


Fig 1. Patient with type 1 neurofibromatosis.

A and B, CT scans obtained at the age of 8 years 3 months without (**A**) and with (**B**) contrast material (50 mL, intravenous bolus, 60% iodine). Enhancing brain lesions are surrounded by edema, suggesting a blood-brain barrier defect. Mass effect (*arrow*) defaces the posterior aspect of the left frontal horn. The chiasm is thick and is also enhanced (*star*).

C, Contrast-enhanced CT scan 7 months after biopsy (age 8 years 10 months) shows the enhanced brain lesions have decreased in size and the mass effect has resolved (*white arrow*). There is a hypodense trace of brain biopsy on the left (*black arrow*).

D, Contrast-enhanced CT scan 17 months after biopsy (age 9 years 8 months) shows the left-sided brain lesion is nearly invisible (compared with Fig 1B). There is a new mass effect with enhancement near the temporal horn of the right lateral ventricle (*arrow*) and mild compression of the body of the right lateral ventricle.

E, Contrast-enhanced CT scan 36 months after biopsy (age 11 years 3 months) shows the brain lesions have decreased in size, and the edema and mass effect have resolved.

F, MR images 12 years after biopsy (age 20 years). Axial T2-weighted (3500/95) spin-echo images at 1 T with 5-mm-thick sections (first four images) show a small hyperintense area in the region of the right globus pallidus (*white arrow*) and hyperintense areas on both sides, consistent with brain biopsy sites (*black arrows*). Coronal T1-weighted (500/15) spin-echo images (4-mm-thick sections) (last two images) show an enlarged chiasm (*star*).

age of 8 years 3 months to 8 years 10 months (Fig 1A–C). After that, they increased in size until the age of 9 years 8 months. At that time, the patient showed signs of precocious puberty, which may have been caused by the hypothalamic brain lesion. The hormonal changes might have influenced the brain lesions, but there is no confirmation of this. Precocious puberty has been described previously in patients with NF-1 (13), but it is not known whether there are any hormone receptors in these brain lesions. After that age, however, our patient's lesions decreased and nearly disappeared spontaneously (Fig 1E and F).

The other brain lesions were not confirmed by biopsy, but they also resolved. Results of the second brain biopsy revealed only normal brain tissue from the right-sided brain lesion (Fig 1D), which was unexpected. It is possible that the

biopsy sample was not taken directly from the lesion, but this is improbable, because the stereotactic surgical technique is very accurate. There was, however, no visible cell disease in the lesion. Previous investigators have described normal brain biopsy findings of unidentified neurofibromatous objects (UNOs) seen on T2-weighted MR images in patients with NF-1 (14). The UNOs have been reported to contain spongiform myelin or vacuoles at autopsy. No stainable material has been evident in histologic sections, suggesting that they are actually filled with water. The intramyelin edema may be an intermittent or transient phenomenon (9).

No other disease apart from NF-1 was found in our patient. The size of the enlarged chiasm remained unchanged throughout the follow-up period. The visual field defects were temporary, disappearing over the course of follow up, and

the patient's vision is normal at the age of 21 years.

The CT findings in our case were unusual, because they enhanced after administration of contrast medium in the first examinations and showed surrounding edema suggestive of a disturbed blood-brain barrier and mass effect (Fig A–D). It has been generally accepted that small UNOs, which do not enhance and have no mass effect, are probably benign (4). On the basis of our observations, we believe that even UNOs with mass effect or enhancement may have a benign natural course in some patients with NF-1. On the other hand, there are no thorough follow-up studies available to suggest how these lesions behave with age. The enhancement and edema were temporary phenomena that occurred at about 8 to 9 years of age.

In patients with NF-1, T2-weighted MR images may reveal hyperintense brain lesions, especially in the optic pathway, that are invisible on CT scans (15). Follow-up examinations with MR imaging would provide more information on the behavior of these brain lesions.

How can a pilocytic astrocytoma disappear? Is this phenomenon connected to the myelination process or to hormones? In our case, the patient improved clinically with increasing age. Is the clinical state also connected to the disturbances of myelination and its improvement? Are there cell repair processes at work? The blood-brain barrier defect of the lesion also disappeared. Can these changes recur? Why do some NF-1 lesions increase in size over time?

If involution of the brain tumor has really occurred, we do not know the mechanism behind it. The NF-1 gene product, neurofibromin, is mainly expressed in the nervous system in adults. One region of neurofibromin is also thought to show a structural and functional homology to the family of GTPase (guanosine triphosphatase-activating proteins), so the NF-1 gene is thought to be a tumor-suppressor gene. In malignant tumors in patients with NF-1, the neurofibromin levels are significantly reduced. Tumor samples from NF-1-related tumors have shown mutations in the NF-1 gene. NF-1 patients inherit one mutant allele of the

NF-1 gene, which gives rise to the tumor. In our case, the tumor was presumably a new mutation and, contrary to the tumor-suppressor hypothesis, resolved spontaneously (16, 17).

References

1. Barker D, Wright E, Nguyen K, et al. Gene for von Recklinghausen neurofibromatosis is in the pericentromeric region of chromosome 17. *Science* 1987;236:1100–1102
2. Albert A, Lee BCP, Saint-Louis L, Deck MDF. MRI of optic chiasm and optic pathways. *AJNR Am J Neuroradiol* 1986;7:255–2558
3. Braffman BH, Bilaniuk LT, Zimmerman RA. MR of central nervous system neoplasia of the phakomatoses. *Semin Roentgenol* 1990;2:198–217
4. Di Mario F Jr, Ramsby G, Greenstein R, Langshur S, Dunham B. Neurofibromatosis type I: magnetic resonance imaging findings. *J Child Neurol* 1993;8:32–39
5. Duffner PK, Cohen ME, Seidel FG, Shucard WS. The significance of MRI abnormalities in children with neurofibromatosis. *Neurology* 1989;39:373–378
6. Elster AD. Radiologic screening in the neurocutaneous syndromes: strategies and controversies. *AJNR Am J Neuroradiol* 1992;13:1078–1082
7. Pont MS, Elster AD. Lesions of skin and brain: modern imaging of the neurocutaneous syndromes. *AJR Am J Roentgenol* 1992;158:1193–1203
8. Shu HH, Mirowitz SA, Wippold FJ II. Neurofibromatosis: MR imaging findings involving the head and spine. *AJR Am J Roentgenol* 1993;160:159–164
9. Di Paolo DD, Zimmerman RA, Rorke LB, et al. Neurofibromatosis type 1: pathologic substrate of high-signal-intensity foci in the brain. *Radiology* 1995;195:721–724
10. Seveck RJ, Barkovich AJ, Edwards MSB, Koch T, Berg B, Lambert T. Evolution of white matter lesions in neurofibromatosis type 1: MR findings. *AJR Am J Roentgenol* 1992;159:171–175
11. Itoh T, Magnaldi S, White RM, et al. Neurofibromatosis type 1: the evolution of deep gray and white matter MR abnormalities. *AJNR Am J Neuroradiol* 1994;15:1513–1519
12. National Institutes of Health Consensus Development. Neurofibromatosis. *Arch Neurol* 1988;45:575
13. Saxena KM. Endocrine manifestations of neurofibromatosis in children. *Am J Dis Child* 1970;120:265–271
14. Braffman B, Naidich P. The phakomatoses, I: neurofibromatosis and tuberous sclerosis. *Neuroimaging Clin N Am* 1994;4:2:299–310
15. Menor F, Marti-Bonmati L. CT-detection of basal ganglion lesions in neurofibromatosis type 1: correlation with MRI. *Neuroradiology* 1992;34:305–307
16. Danglot G, Régnier V, Fauvet D, Vassal G, Kujas M, Bernheim A. Neurofibromatosis 1 (NF1) mRNAs expressed in the central nervous system are differentially spliced in the 5 parts of the gene. *Hum Mol Genet* 1995;4:915–920
17. Von Deimling A, Krone W, Menon AG. Neurofibromatosis type 1: pathology, clinical features and molecular genetics. *Brain Pathol* 1995;5:153–162