



Providing Choice & Value

Generic CT and MRI Contrast Agents



**FRESENIUS
KABI**

CONTACT REP

AJNR

Repermeation of partially embolized cerebral arteriovenous malformations: a clinical, radiologic, and histologic study.

A Gruber, P R Mazal, G Bavinzski, M Killer, H Budka and B Richling

This information is current as of July 18, 2025.

AJNR Am J Neuroradiol 1996, 17 (7) 1323-1331
<http://www.ajnr.org/content/17/7/1323>

Repermeation of Partially Embolized Cerebral Arteriovenous Malformations: A Clinical, Radiologic, and Histologic Study

Andreas Gruber, Peter R. Mazal, Gerhard Bavinzski, Monika Killer, Herbert Budka, and Bernd Richling

PURPOSE: To describe the pattern and time course of embolization-related tissue lesions and repermeation of the intranidal cast after endovascular embolization of cerebral arteriovenous malformations (AVMs) with *N*-butyl cyanoacrylate (NBCA). **METHODS:** We retrospectively reviewed the records of 26 patients who were treated by endovascular embolization with NBCA and subsequent surgical extirpation to look for embolization-related tissue lesions and repermeation of the cast. A residual flow through the malformation was identified on preoperative angiograms in every case. **RESULTS:** Pattern and time course of embolization-related tissue lesions were typical. Until 3 months after embolization, repermeation of embolized structures did not occur. In contrast, repermeation was found in every patient who had surgery later than 3 months after the first embolization ($n = 13$; 50%). In these cases, histologic examination of the resected nidus disclosed capillary structures inside the lumen of embolized vessels. Capillaries were traced immunohistochemically with antibodies against membrane-bound factor VIII. No parameter other than the interval between the first embolization and surgery was found to relate to the repermeation of the cast. **CONCLUSION:** Intranidal recapillarization can occur later than 3 months after the first embolization with NBCA if total and solid casting of the nidus was not accomplished.

Index terms: Arteriovenous malformations, cerebral; Arteriovenous malformations, embolization

AJNR Am J Neuroradiol 17:1323–1331, August 1996

Endovascular embolization has become a valuable tool in the treatment of cerebral arteriovenous malformations (AVMs) as a result of improvements in endovascular techniques. Embolization of AVMs can be performed as definitive treatment (1) or as one step in a combined treatment with surgery (2–4) or radiosurgery (5). The decision as to which therapeutic tool should be used is guided by a comparison of the risks represented by the natural course of the malformation against the risks of treatment (6). For small malformations in highly functional areas of the brain, radiosurgery may be offered. However, at our clinic, endovascular embolization is the first-line treatment for most

patients with cerebral AVMs. It is our therapeutic strategy to attain a total and solid casting of the nidus, and hence a definitive treatment of the malformation, by endovascular embolization. However, definitive cure was accomplished in only 15% of our patients by embolization alone. In the remaining cases, further therapy (ie, radiosurgery or surgery) was necessary to obtain a definitive cure. Neurologically intact patients with lesions located in highly functional areas of the brain, however, may represent an exception, as subtotal results of embolization can be acceptable (1). Residual hemodynamic stress, generated by remaining arteriovenous shunts, may trigger the repermeation of the nidus.

A residual flow through the malformation was identified on preoperative angiograms in every case in the present study. Our intention was therefore to describe the pattern and time course of embolization-related tissue lesions and repermeation of the intranidal cast after incomplete endovascular embolization with *N*-butyl cyanoacrylate (NBCA).

Received July 26, 1995; accepted after revision February 2, 1996.

From the Department of Neurosurgery (A.G., G.B., M.K., B.R.) and the Institute of Neurology (P.R.M., H.B.), University of Vienna (Austria).

Address reprint requests to Andreas Gruber, MD, Department of Neurosurgery, University of Vienna Medical School, Währinger Gürtel 18–20, A-1090 Vienna, Austria.

AJNR 17:1323–1331, Aug 1996 0195-6108/96/1707-1323

© American Society of Neuroradiology

Materials and Methods

Over a period of 9 years, 186 patients were treated for cerebral AVMs in our department. Of these, 96 patients were scheduled for further treatment, as nidus obliteration was still incomplete, and 90 were definitively cured by surgery, embolization, radiosurgery, or a combination of these tools. These patients remained stable at angiographic follow-up. Fifty-three of the cured patients had treatment consisting of endovascular embolization followed by surgical extirpation of the nidus. Of these, 27 cases were excluded from the study because either embolization was performed with materials other than NBCA or the whole surgical specimen was not available for histologic processing. Twenty-six cases in which a single or staged embolization with NBCA was done before surgery were thus available for analysis.

Microsurgical extirpation of the nidus after embolization was necessary because of the technical impossibility of achieving total endovascular cure in 15 patients (58%) with a history of bleeding; because of reperfusion of the AVM detected on follow-up angiograms after an initial total occlusion of the nidus in three patients (11.5%); because of the angiographic appearance (7, 8) and/or the easy surgical accessibility of the malformation in five cases (19%); and because of severe intracerebral bleeding during or after embolization (necessitating emergency surgery) in three patients (11.5%).

The location of the AVMs treated, the arterial supply, the expected risk of surgical morbidity according to the Spetzler-Martin grading system, and the clinical presentation are given in Table 1. According to the Spetzler-Martin grading system (9), one AVM was grade 1, six were grade 2, 11 were grade 3, six were grade 4, and two were grade 5.

TABLE 1: Clinical and neuroradiologic presentation of 26 patients with arteriovenous malformations

Case	Sex/Age, y	Location	Feeding Vessels	Spetzler-Martin Grade	Bleeding
1	M/67	R par occ	R MCA	1	ICH
2	F/40	Callosal	R + L ACA; R + L PChA	3	ICH*
3	F/57	L par	L ACA; MCA (M1 perf)	3	None
4	F/12	R rolandic	R MCA	2	ICH
5	F/15	L par occ	R MCA	2	ICH
6	F/8	R rolandic	R MCA; R ACA	3	ICH
7	M/46	L par occ	L MCA; L PCA	3	ICH†
8	F/30	R frontal	R ACA	2	None
9	F/27	R par occ	R MCA; R PCA	3	ICH
10	M/37	R trigonal	R ACA; R MCA; R PCA; R + L PChA	4	ICH, IVH
11	M/15	Callosal	R ACA; R AChA; R + L PCA; R + L PChA	5	4x ICH
12	F/51	R cerebellar	R PICA; R SCA	2	ICH*
13	M/59	L rolandic	L ACA	3	ICH
14	M/44	L rolandic	L MCA; L ACA; L AChA	4	ICH*
15	F/23	R rolandic	R ACA; R MCA	3	None
16	M/24	R par occ	R MCA; R PCA; VA	3	ICH*
17	F/32	L temporal	L MCA; L PCA	3	ICH
18	M/48	L rolandic	L ACA	3	ICH
19	F/18	L rolandic	L MCA; L AChA; L PChA	4	ICH
20	F/59	R rolandic	R ACA; R MCA	4	None
21	M/36	Callosal	R + L ACA; R + L MCA; R + L PCA	5	ICH, IVH
22	M/26	L par occ	L MCA; L ECA	2	SAH, ICH
23	M/14	R temporal	R MCA; R ECA	2	None
24	F/27	L par occ	L ACA; L MCA	4	SAH
25	M/24	R par occ	R ACA; R MCA; R PCA; R + L ECA	4	None
26	M/46	R temporal	R MCA; R PCA; R ECA	3	None

Note.—SAH indicates subarachnoid hemorrhage; ICH, intracerebral hemorrhage; IVH, intraventricular hemorrhage; par, parietal; occ, occipital; ACA, anterior cerebral artery; MCA, middle cerebral artery; PCA, posterior cerebral artery; AChA, anterior choroidal artery; PChA, posterior choroidal artery; ECA, external carotid artery; VA, vertebral artery; PICA, posterior inferior cerebellar artery; SCA, superior cerebellar artery; and perf, perforating artery.

* Bleeding occurred after endovascular embolization.

† Bleeding was caused by an associated aneurysm.

The embolizing substance used in all cases was a mixture of NBCA (Histoacryl Blue; Braun, Melsungen, Germany) and a nonionic contrast agent (iodized oil; Lipiodol ultrafluide; Guerbet, Aulnay-sous-Bois, France). In five cases, glacial acetic acid was added to the embolizing agent to decrease the velocity of polymerization without altering the viscosity (10).

Diagnostic angiography was performed when the patients were medically stable unless angiograms were obtained at another center before the patient was transferred. Examination of the feeding vessels was performed with superselective digital subtraction angiography in conjunction with embolization. The extent of angiographic nidus reduction after embolization was estimated from the final angiograms. The endovascular interventions were usually performed under local anesthesia. General anesthesia was required only in critically ill or uncooperative patients. In every case, the partially embolized AVM nidus was resected in one session under microsurgical conditions. In 25 cases (96%), a total extirpation of the AVM was possible. Total extirpation was confirmed by intraoperative digital subtraction angiography (11) in each case. In one instance of a giant callosal AVM (case 25), a small residual nidus was subsequently treated with gamma knife radiosurgery. Angiographic follow-up was obtained in every patient. The clinical outcome of the patients was stratified according to the Glasgow Outcome Scale, in which 1 indicates no deficit; 2, mild deficit; 3, severe deficit; 4, vegetative state; and 5, death.

The resected surgical specimens were routinely fixed in buffered formaldehyde and embedded in paraffin. Serial sections were cut to a thickness of approximately 5 μ m and stained with hematoxylin-eosin and Gieson's Elastica stains. Additionally, a staining technique designed to depict the intranidal cast was performed, as proposed by Lundie et al in 1985 (12), which allowed clear differentiation between the embolizing agent and the surrounding tissue (Fig 1). Representative sections were examined by means of immunohistochemistry with antibodies against membrane-bound factor VIII to show the endothelium of the capillaries sprouting into the intranidal cast.

Results

Clinical Findings

Fifty-four endovascular embolizations were performed in 26 patients. The time of tissue exposure to NBCA ranged from less than 24 hours to 52 months. The extent of angiographic nidus reduction after the final embolization is shown in Table 2. A residual flow through the malformation was present on preoperative angiograms in every case. In no case was a solid casting of the entire nidus achieved. However, in three cases, a transient angiographic occlusion was followed by reperfusion of the malfor-

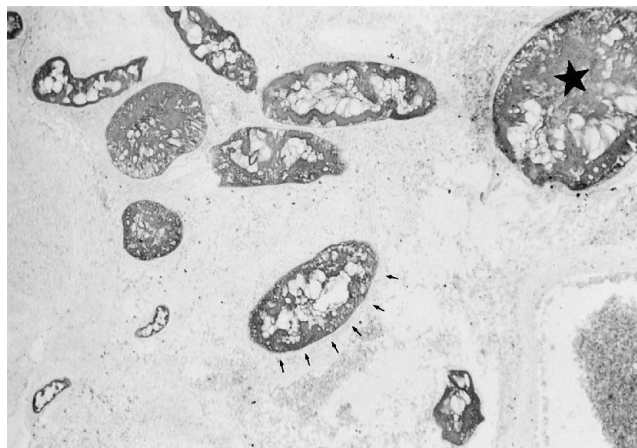


Fig 1. Photomicrograph of a previously embolized arteriovenous malformation. Multiple vascular channels with intraluminal NBCA (star) and intact vessel walls (arrows) are clearly identified. Note the absence of extravasation of embolic material (modified oil red-O stain, original magnification $\times 40$).

mation via branches of the external carotid artery 12 to 52 months after the first embolization.

Total extirpation of the malformation was accomplished in 25 cases. In one instance of a giant callosal AVM (case 25), a small residual nidus was subsequently treated with gamma knife radiosurgery. Clinical outcomes on the Glasgow Outcome Scale were as follows: 17 cases (65%) were scored 1, six cases (23%) were scored 2, and one case (4%) each was scored 3, 4, and 5. Endovascular morbidity and mortality were due to severe intracerebral hemorrhage in three patients during or after embolization. Surgical morbidity (ie, focal neurologic deficits following resection of the AVM) occurred in six cases. The higher the surgical dignity of the lesion, stratified according to the Spetzler-Martin grading system, the more frequently surgical morbidity was encountered. In contradistinction, endovascular morbidity was not related to the Spetzler-Martin grades of the lesions. Additionally, there was no correlation between outcome and degree of preoperative endovascular nidus reduction.

Preoperative embolization with NBCA facilitated extirpation of the malformation in most cases. However, embolized feeding arteries were sometimes rigid and therefore difficult to cut. In addition, retraction of solidly casted compartments of the AVM during dissection was more difficult. In four cases, in which sur-

gery was performed later than 3 months after the first embolization, surgical extirpation was complicated by a diffuse perinidal capillary network, providing collateral blood supply to the nidus. However, these setbacks could not outweigh the overall advantages of significantly reduced blood loss and reduced operating time provided by sufficient preoperative embolization.

Embolization-Related Tissue Lesions and Repermeation of Intranidal Cast

The time course of mural angioneclerosis, inflammation, and repermeation of the casted intranidal structures is summarized in Table 2. The cases are listed according to the time of exposure to NBCA. In the case of a single embolization, exposure was defined as the interval between embolization and surgery. If a patient had staged embolizations, the time between the

first embolization and surgery was recorded. Each specimen was examined histologically for the degree of inflammation, mural angioneclerosis, extravasation of NBCA, and recanalization of embolized structures in relation to the time elapsed between the first embolization and surgery.

Among embolization-related tissue lesions, inflammation (Fig 2) was seen in 25 cases (96%). Acute inflammation, comprising predominantly polymorphonuclear cells, was seen as soon as 24 hours after embolization. Chronic inflammation, marked by the appearance of transmural lymphocytic infiltration and foreign body giant cells within the casted areas, was detected in 23 cases (88%). Lymphocytic infiltration occurred 1 week after the intervention. Foreign body giant cells were not seen before 1 month after embolization, but they were detectable for as long as 52 months. Mural angioneclerosis (Fig 3) was seen as soon as 2 days after

TABLE 2: Embolization-related tissue lesions and recanalization of cast

Case	Interval between First Embolization and surgery	No. of Preoperative Embolizations	Histoacryl/Iodized Oil Ratio	Degree of Preoperative Nidus Reduction, %	Angioneclerosis	Granulocytes	Lymphocytes	Foreign Body Giant Cells	Repermeation?
1	<24 h	1	1:3	90	—	—	—	—	No
2	<24 h	1	1:2	85	—	+-	—	—	No
3	2 d	1	1:2	95	+	+	—	—	No
4	1 wk	1	1:2	70	++	+-	++	—	No
5	1 wk	1	1:2,1:3	70	++	—	++	—	No
6	1 wk	1	1:3	60	++	—	++	—	No
7	1 wk	1	1:2	70	++	—	++	—	No
8	1 wk	1	1:2 +GA	90	++	+-	+	—	No
9	3 wk	1	1:1 +GA	80	+	+-	+	++	No
10	4 wk	2	1:2	50	+	—	++	++	No
11	4 wk	2	1:2,1:3	70	+	+-	+	++	No
12	4 wk	1	1:2	90	—	—	++	++	No
13	2 mo	1	1:3	90	+-	—	+	++	No
14	3 mo	2	1:2	80	—	—	++	++	Yes
15	4 mo	2	1:2,1:3	85	++*	+	++	++	Yes
16	4 mo	2	1:2	90	—	—	++	++	Yes
17	6 mo	3	1:2,1:1 +GA	85	++*	++*	+	++	Yes
18	6 mo	1	1:2	40	—	—	++	++	Yes
19	8 mo	2	1:2	80	+	—	+	+	Yes
20	9 mo	3	1:2	80	+	+-	++	++	Yes
21	11 mo	6	1:1,1:2 +GA	80	—	+-	+	++	Yes
22	12 mo	1	1:2	95†	—	—	++	++	Yes
23	12 mo	2	1:2	95†	—	+-	++	++	Yes
24	18 mo	5	1:2,1:1	90	—	—	++	++	Yes
25	26 mo	7	1:2,1:1 +GA	80	—	—	+	++	Yes
26	52 mo	3	1:2	95†	—	—	++	++	Yes

Note.—GA indicates glacial acetic acid; —, no tissue reaction was observed; +-, slight tissue reaction; +, moderate tissue reaction; and ++, severe tissue reaction.

* Final embolization procedure was performed within 4 weeks before surgery.

† Repermeation of malformation after initial angiographic obliteration.

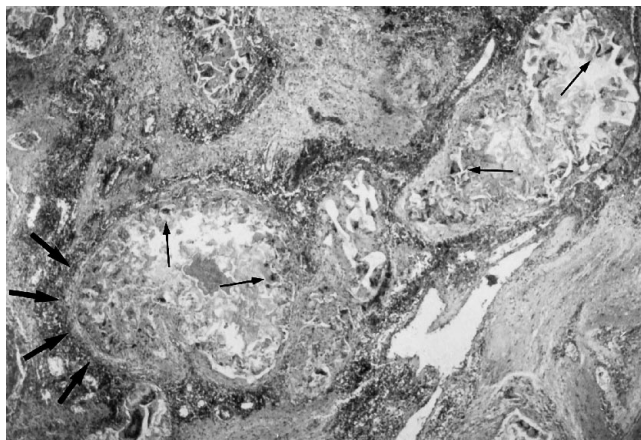


Fig 2. Photomicrograph of vascular channel containing embolic material. Intraluminal NBCA is surrounded by foreign body giant cells (*thin arrows*) and a transmural inflammatory infiltration of the vessel wall (*wide arrows*) (hematoxylin-eosin, original magnification $\times 40$).

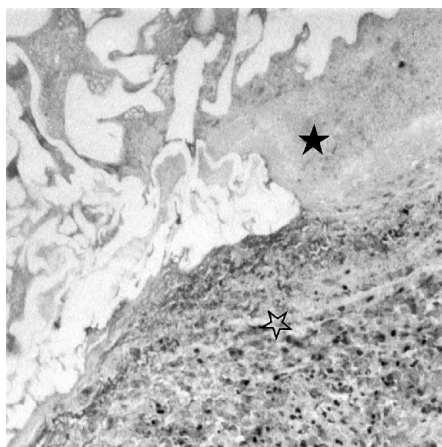
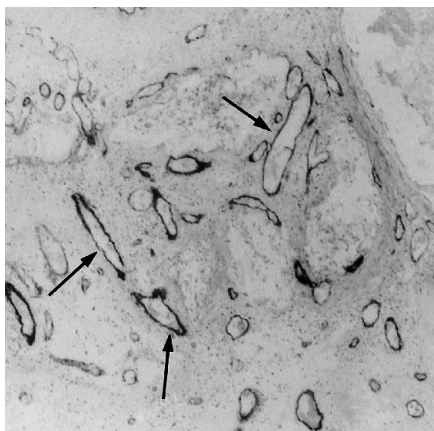
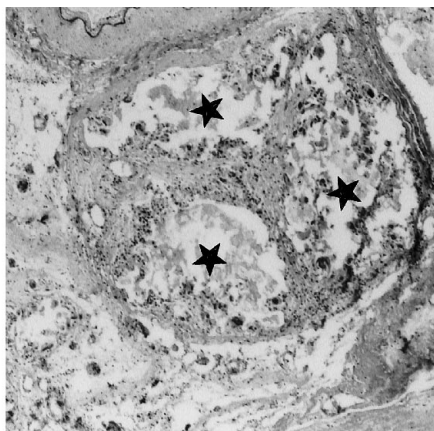


Fig 3. Photomicrograph shows an area of marked mural angionecrosis (*open star*) in proximity to intraluminal cast (*solid star*) (hematoxylin-eosin, original magnification $\times 20$).



A



B

embolization, reaching a maximum after 1 week. Owing to fibrosis of the vessel wall, angionecrosis was not seen later than 2 months after embolization. In four cases, signs of necrosis were detectable as long as 9 months after the first embolization. These patients underwent staged embolizations and had surgery within 4 weeks after the final intervention. No clear-cut extravasation of cyanoacrylate was observed in any specimen in our series.

Histologic examination of the resected nidus disclosed a repermeation of embolized vessels in 13 cases (50%). Trabeculae of connective tissue were seen bridging the lumen of initially obliterated malformed vessels (Fig 4). Inside these trabeculae, capillaries with endothelial cell lining were identified by immunohistochemistry with antibodies against membrane-bound factor VIII (Fig 4A). Repermeation did not occur until 3 months after embolization. In contrast, intranidal recapillarization was seen in every case in which surgery was performed later than 3 months after the initial embolization. Recapillarization of previously embolized malformed vessels was seen as long as 52 months after the first embolization (case 26). The location of the AVM did not influence the onset of repermeation, nor were the pattern and time course of intranidal recapillarization influenced by the Histoacryl/iodized oil ratio of the embolizing substance, the addition of glacial acetic acid to the compound (Table 3), the degree of preoperative nidus reduction (Table 4, Fig 5), or the Spetzler-Martin grade of the malformation. In addition, lacunae without endothelial lining were identified inside the cast, representing either areas of dissolved intranidal thrombus or

Fig 4. Photomicrographs of an NBCA-occluded malformed vessel 26 months after embolization. Angiogenic repermeation of the casted lumen is clearly demonstrated with immunohistochemistry for factor VIII (A) and Gieson's Elastica stain (B). Trabeculae of connective tissue and embedded vascular channels (*arrows*), bridging the original vessel lumen (*stars*), are identified (original magnification $\times 40$).

artifacts caused by processing of the surgical specimens.

Discussion

Endovascular embolization of cerebral AVMs will lead to definitive cure if complete obliteration of the nidus is achieved and patients remain stable at follow-up angiography. Repermeation of a previously embolized malformation there-

fore represents a major threat to the quality of the treatment. Recanalization after embolization with NBCA was previously demonstrated by Brothers et al (13) in domestic swine. In their series, repermeation of casted rete mirabile was encountered as early as 21 days after embolization. The surgical specimens of 10 human cerebral AVMs were investigated by Klara et al (14), with both light and scanning electron microscopy. In their series, surgery was not performed earlier than 3 weeks after embolization with isobutyl 2-cyanoacrylate (IBCA). Endothelial proliferation was documented immunohistochemically by Schweitzer et al (15) in 18 human cerebral AVMs embolized with either IBCA, polyvinyl alcohol (PVA) particles, or Avitene. Our study provides a long-term histologic follow-up of human cerebral AVMs embolized with NBCA.

Embolization-Related Tissue Lesions

The ideal embolizing agent ought to meet the criteria postulated by Clarisse et al in 1976 (16): (a) controllable viscosity, (b) elasticity of the substance after setting, (c) in vivo stability, (d) biocompatibility, (e) sterilizability, and (f) radiopacity. Currently, cyanoacrylates allow a maximum stability of the cast and simultaneously a relatively deep penetration into the nidus. Additionally, materials such as PVA particle mixtures (17, 18), ethylene vinyl alcohol copolymer (19), estrogen (20), homologous fibrin (21), and others have been proposed. The tissue responses induced by the embolizing

TABLE 3: Influence of embolic material on angiogenic repermeation

	Embolic Material		
	Histoacryl/ Iodized Oil Ratio of 1:2	Histoacryl/ Iodized Oil Ratio Other than 1:2	Histoacryl/ Iodized Oil Plus Glacial Acetic Acid
Angiogenic repermeation	8	2	3
No angiogenic repermeation	6	5	2

TABLE 4: Influence of preoperative nidus reduction on angiogenic repermeation

	Preoperative Nidus Reduction, %			
	100	>90	>70	<70
Intranidal angiogenesis	0	5	7	1
No intranidal angiogenesis	0	5	6	2

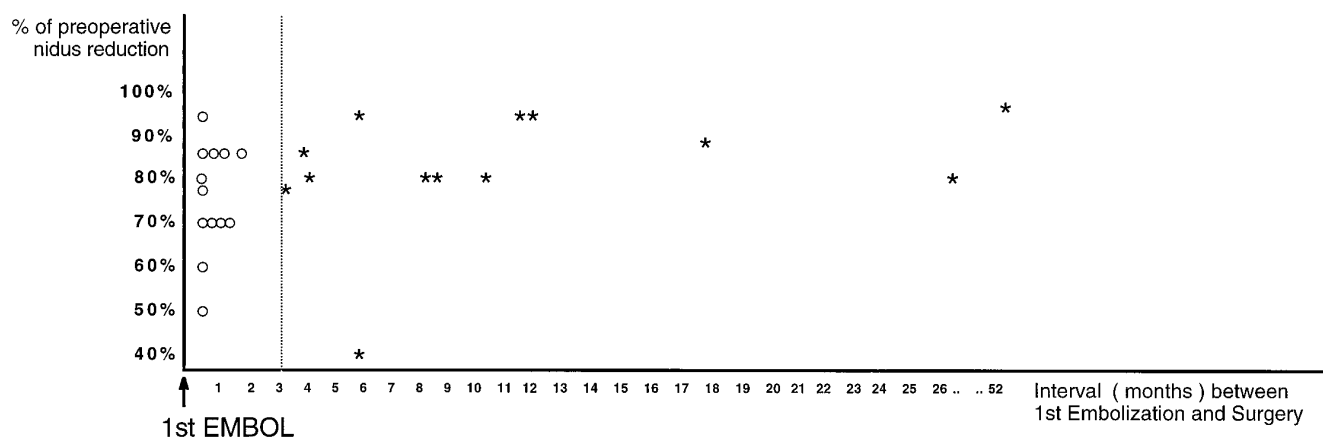


Fig 5. Angiogenic repermeation of intranidal NBCA. Specimens are plotted according to their interval between first embolization and surgery (months) and according to the extent of preoperative endovascular nidus reduction (percent). The graph demonstrates the *positive* correlation between repermeation and interval between first embolization and surgery and the *negative* correlation between repermeation and extent of preoperative endovascular nidus reduction. Repermeation did not occur earlier than 3 months after the first embolization. Asterisks indicate specimens with histologically proved repermeation of NBCA; circles, specimens without repermeation.

substance need to be relatively mild, as the cast is intended to remain in vivo for a lifetime. Heat production in the initial exothermic polymerization and release of formaldehyde during the breakdown process of cyanoacrylates have been described as causative factors for the embolization-related tissue lesions encountered (22, 23). Some degree of mural inflammation, however, seems to act in synergy with the embolizing substance to render permanent occlusion of the nidus through the formation of scars and fibrosis. This study emphasizes that the tissue responses to NBCA can be considered relatively benign, as angioneclerosis was replaced by fibrosis of the vessel wall within 2 months and acute inflammation developed into a chronic lesion within 1 month after embolization. The observation of a typical pattern and time course of angioneclerosis and inflammation after embolization (Table 2) unites our results with those of previous studies (13, 24). In contrast, such previously reported lesions as intima loss, shrinking and calcification of the media, intramural hemorrhage, extravasation of glue, and inflammation of neuronal tissue after embolization with cyanoacrylates other than NBCA (13, 24–32) were not encountered in our series.

Repermeation of Embolized Malformed Vessels

Collateralization—that is, the dilatation of preexistent collateral vessels, reconstituting the blood flow to the AVM nidus (33)—is an important mechanism for repermeation of embolized malformations. This phenomenon usually occurs in the perilesional tissue, where the number of preexisting vessels relates to the anatomic location of the nidus. Maximum angiographic reperfusion after embolization has been described for occipital AVMs, even after total occlusion (33). Our study indicates that recanalization of the embolized nidus is not influenced by the anatomic location of the AVM. In addition, resorption of intranidal cyanoacrylate has been reported (34). Although resistance to biodegradation may be altered by a change in the Histoacryl/iodized oil ratio of the compound, our study produced no evidence that either this ratio or the addition of glacial acetic acid influences the onset of angiogenic repermeation (Table 3).

Previous reports (31, 35) emphasize that polymerized glue occludes only a part of the in-

jected lumen while the remainder is filled with thrombus. In the absence of solid casting of the entire nidus with glue, repermeation of embolized vessels can occur by recanalization of intraluminal thrombus. The release of angiogenic cytokines, promoting the recanalization of thrombus, is triggered by ischemia, inflammation, and changes in shear stress to the vascular endothelium. Because endovascular embolization with permanent materials like NBCA induces intranidal ischemia, the question arises whether ischemia is causally related to the recanalization of partially embolized malformations. The same may be true for embolization-related inflammation, as vasoactive factors such as vascular endothelial growth factor (36–38), fibroblast growth factor (39, 40), transforming growth factor (41, 42), platelet-derived growth factor (43, 44), granulocyte-macrophage colony-stimulating factor (45, 46), interleukin 6 (47), and tumor-necrosis factor (48) were shown to be produced by leukocytes, predominantly activated macrophages and T lymphocytes (49). In addition, vascular endothelial shear stress, the rheological force shearing the luminal surface of the blood vessel when a viscous fluid such as blood flows over it, is altered but not abolished in partially embolized malformations.

Endothelial genetic expression of vasoactive cytokines is reportedly altered in response to changes of shear stress (50–53), suggesting an additional, blood flow-dependent mechanism. Hence, it may reasonably be anticipated that angiogenic repermeation of intranidal thrombus is partially triggered by the enhanced release of cytokines in the presence of ischemia, inflammation, and alteration of shear stress. The fact that tissue levels of angiogenic factors were not measured in the present study should not invalidate our findings. It was not the scope of this report to demonstrate the biochemical mechanism of intranidal angiogenesis; rather, this work emphasizes that repermeation of an embolized nidus is not generated by the mechanical dissolution of the glue alone. It is reasonable to believe that the mechanical stress of residual blood flow through the malformation acts in synergy with the enhanced release of angiogenic factors and with changes in endothelial cell function in response to altered shear stress (50–53).

Clinical Implications

The most important finding of the present study was that angiogenic repermeation of intranidal NBCA is possible as soon as 3 months after the first embolization. This finding may have implications for the timing of subsequent surgery. Physicians involved in the treatment of AVMs should be aware of a potential for angiogenic repermeation of the nidus later than 3 months after the first embolization. As histologic repermeation had no prominent angiographic correlate, the definitive clinical significance of this finding, however, needs to be clarified.

The question of whether angiogenic repermeation occurs only in subtotally embolized lesions or also in totally casted malformations is still unclear. We had no patients with permanent total nidus obliteration who went on to surgery, as these subjects were considered definitively cured if stable at angiographic follow-up. In contradistinction, the patients reported in the present study all went on to surgery, as solid casting of the entire nidus was not accomplished. In this group, 23 patients had preoperative nidus reductions of 40% to 95% after the last embolization. As pointed out previously, residual hemodynamic stress induced angiogenic repermeation of the cast in 10 of these cases. In the remaining three patients, total angiographic obliteration of the malformation was obtained immediately after treatment. Reperfusion of the nidus via branches of the external carotid artery was, however, seen 12 to 52 months later at follow-up angiography. The density of the intranidal cast was erroneously overestimated in these cases and dilatation of collateral vessels (32) redirected blood through the incompletely casted nidus. There was considerable time for recapillarization, as none of these particular three lesions was resected earlier than 12 months after the first embolization. This finding is in agreement with reliable angiographic follow-up studies (54), demonstrating stable angiographic results only in cases with total and solid casting of the nidus. The clinical significance of our findings could be clarified if human cerebral AVMs, totally casted with NBCA, were examined histologically for signs of angiogenic recapillarization.

Conclusion

Twenty-six surgical specimens of human cerebral AVMs resected less than 24 hours to 52 months after embolization were examined histologically. Pattern and time course of embolization-related tissue lesions were typical. Recapillarization of previously embolized malformed vessels was demonstrated in every case in which surgery was performed later than 3 months after the first embolization. It is suggested that nidus repermeation may act in synergy with recruitment of collateral vessels in the reperfusion of embolized malformations.

Acknowledgment

We thank H. Flicker for her excellent technical assistance.

References

1. Picard L, Moret J, Lepoivre J. Endovascular treatment of intracerebral arteriovenous malformations. *J Neuroradiol* 1984;11:9-28
2. Deruty R, Lapras C, Pierluca P, Patet JD, Pialat J, Garcia C. Embolisation preoperative des malformations arterio-veineuses cerebrales par le butyl-cyanoacrylate. *Neurochirurgie* 1985;31:21-29
3. Spetzler RF, Martin N, Carter LP, Flom R, Raudzens P, Wilkinson E. Surgical management of large AVMs by staged embolization and operative excision. *J Neurosurg* 1987;67:17-28
4. Vinuela F, Dion J, Duckwiler G, et al. Combined endovascular embolization and surgery in the management of cerebral arteriovenous malformations: experience in 101 cases. *J Neurosurg* 1991;75:856-864
5. Lunsford LD, Kondziolka D, Flickinger J, Bissonette D. Stereotactic radiosurgery for arteriovenous malformations of the brain. *J Neurosurg* 1991;75:512-524
6. Hamilton MG, Spetzler RF. The prospective application of a grading system for arteriovenous malformations. *Neurosurgery* 1994;34:2-7
7. Marks M, Lane B, Steinberg G, Chang P. Hemorrhage in intracerebral arteriovenous malformations: angiographic determinants. *Radiology* 1990;176:807-813
8. Vinuela F, Nombela L, Roach M, Fox A, Pelz D. Stenotic and occlusive disease of the venous drainage system of deep brain AVMs. *J Neurosurg* 1985;63:180-184
9. Spetzler RF, Martin N. A proposed grading system for arteriovenous malformations. *J Neurosurg* 1986;65:476-483
10. Spiegel SM, Vinuela F, Goldwasser JM, Fox AJ. Adjusting the polymerization time of isobutyl-2-cyanoacrylate. *AJNR Am J Neuroradiol* 1986;7:109-112
11. Hieshima GB, Reicher MA, Higashida RT, Halbach VV. Intraoperative digital subtraction neuroangiography: a diagnostic and therapeutic tool. *AJNR Am J Neuroradiol* 1987;8:759-767
12. Lundie MJ, Ellyatt D, Kaufmann JCE, Vinters HV. Staining procedure to aid in assessment of bucrylate histotoxicity in tissue sections. *Arch Pathol Lab Med* 1985;109:779-781

13. Brothers MF, Kaufmann JC, Fox AJ, Deveikis JP. *n*-Butyl 2-cyanoacrylate: substitute for IBCA in interventional neuroradiology: topographic and polymerization time study. *AJNR Am J Neuroradiol* 1989;10:777-786
14. Klara PM, Eugene DJ, McDonnell DE, Pevsner PH. Morphological studies of human arteriovenous malformations: effects of isobutyl 2-cyanoacrylate embolization. *J Neurosurg* 1985;63:421-425
15. Schweitzer JS, Chang BS, Madsen P, Vinuela F, Martin NA, Vinters HV. The pathology of arteriovenous malformations of the brain treated by embolotherapy, II: results of embolization with multiple agents. *Neuroradiology* 1993;35:468-474
16. Clarisse J, Gozet G, Cornil J, Jomin P, Delandsheer J, Laines E. Les embolés plastiques fluides: étude expérimentale et rapport de deux cas cliniques de fistules artério-veineuses traitées. *J Neuroradiol* 1975;2:29-38
17. Germano LM, Davis RL, Wilson CB, Hieshima GB. Histopathological follow up study of 66 cerebral arteriovenous malformations after therapeutic embolization with polyvinyl alcohol. *J Neurosurg* 1992;76:607-614
18. Lylyk P, Vinuela F, Vinters HV, Dion J, Duckwiler C, Lin T. Use of a new mixture for embolization of intracranial vascular malformations. *Neuroradiology* 1990;32:304-310
19. Taki W, Kikuchi H, Iwata H, Nishi S. Embolization of arteriovenous malformations using EVAL mixture (a new liquid embolization material). *Neuroradiology* 1991;33(Suppl):195-196
20. Suzuki J, Komatsu S. New embolization method using estrogen for dural arteriovenous malformations and meningiomas. *Surg Neurol* 1981;16:438-442
21. Richling B. Homologous controlled viscosity fibrin for endovascular embolization. *Acta Neurochir (Wien)* 1982;62:159-170
22. Mickey BE, Samson D. Neurosurgical applications of the cyanoacrylate adhesives. *Clin Neurosurg* 1981;28:429-444
23. Pevsner PH, George ED, Doppmann JL. Interventional radiology polymeric update: acrylic. *Neurosurgery* 1982;10:314-316
24. Vinters H, Lundie MJ, Kaufmann J. Long term pathological follow up of cerebral arteriovenous malformations treated by embolization with bucrylate. *N Engl J Med* 1986;314:477-483
25. Diaz FG, Matri AR, Chou SN. Neural and vascular tissue reactions to aneurysm coating adhesive (ethyl-2-cyanoacrylate). *Neurosurgery* 1978;3:45-49
26. Green AR, Milling MA. Butyl cyanoacrylate adhesives in microvascular surgery: an experimental pilot study. *J Reconstr Microsurg* 1986;2:103-105
27. Hood T, Matri A, Chou S. Neural and vascular tissue reactions to cyanoacrylate adhesives: a further report. *Neurosurgery* 1982;11:363-366
28. Lanman TH, Martin NA, Vinters HV. The pathology of encephalic arteriovenous malformations treated by prior embolotherapy. *Neuroradiology* 1988;30:1-10
29. Vinters H, Galil K, Lundie M, Kaufmann JCE. The histotoxicity of cyanoacrylates, a selective review. *Neuroradiology* 1985;27:279-291
30. Vinters H, Debrun G, Kaufmann J, Drake C. Pathology of arteriovenous malformations embolized with isobutyl-2-cyanoacrylate (bucrylate). *J Neurosurg* 1981;55:819-825
31. Zanetti P, Sherman F. Experimental evaluation of a tissue adhesive as an agent for the treatment of aneurysms and arteriovenous abnormalities. *J Neurosurg* 1972;36:72-76
32. Zumpano J, Jacobs L, Hall J, Margolis G, Sachs E Jr. Bioadhesive and histotoxic properties of ethyl-2-cyanoacrylate. *Surg Neurol* 1982;18:452-457
33. Fournier D, Terbrugge K, Rodesch G, Lasjaunias P. Revascularization of brain arteriovenous malformations after embolization with bucrylate. *Neuroradiology* 1990;32:497-501
34. Rao VRK, Mandalam KR, Gupta AK, Kumar S. Dissolution of isobutyl 2-cyanoacrylate on long-term follow-up. *AJNR Am J Neuroradiol* 1989;10:135-141
35. Vinuela F, Fox AJ, Pelz D, Debrun G. Angiographic follow up of large cerebral AVMs incompletely embolized with isobutyl-2-cyanoacrylate. *AJNR Am J Neuroradiol* 1986;7:919-925
36. Neufeld G, Tessler S, Gitay-Goren H, Levi BZ. Vascular endothelial growth factor and its receptors. *Prog Growth Factor Res* 1994;5:89-97
37. Shweiki D, Itin A, Soffer D, Keshet E. Vascular endothelial growth factor induced by hypoxia may mediate hypoxia induced angiogenesis. *Nature* 1992;29:843-845
38. Brogi E, Wu T, Namiki A, Isner JM. Indirect angiogenic cytokines upregulate VEGF and bFGF gene expression in vascular smooth muscle cells, whereas hypoxia upregulates VEGF expression only. *Circulation* 1994;90:649-652
39. Weich HA, Iberg N, Klagsbrunn M, Folkman J. Transcriptional regulation of basic fibroblast growth factor gene expression in capillary endothelial cells. *J Cell Biochem* 1991;47:158-164
40. Villaschi S, Nicosia RF. Angiogenic role of endogenous basic fibroblast growth factor released by rat aorta after injury. *Am J Pathol* 1993;143:181-190
41. Raychaudhury A, D'Amore PA. Endothelial cell regulation by transforming growth factor-beta. *J Cell Biochem* 1991;47:224-229
42. Iruela-Arispe ML, Sage EH. Endothelial cells exhibiting angiogenesis in vitro proliferate in response to TGF beta-1. *J Cell Biochem* 1993;52:414-430
43. Risau W, Drexler H, Mironov V, Heldin CH. Platelet derived growth factor is angiogenic in vivo. *Growth Factors* 1992;7:261-266
44. Sato N, Beitz JG, Kato J, Raymond A, Frackelton AR Jr. Platelet derived growth factor stimulates angiogenesis in vitro. *Am J Pathol* 1993;142:1119-1130
45. Sunderkotter C, Steinbrink K, Goebeler M, Bhardwaj R, Sorg C. Macrophages and angiogenesis. *J Leukoc Biol* 1994;55:410-422
46. Sunderkotter C, Goebeler M, Schulze-Osthoff K, Bhardwaj R, Sorg C. Macrophage-derived angiogenesis factors. *Pharmacol Ther* 1991;51:195-216
47. Rosen EM, Liu D, Setter E, Bhargava M, Goldberg ID. Interleukin-6 stimulates motility of vascular endothelium. *EXS* 1991;59:194-205
48. Fajardo LF, Kwan HH, Kowalski J, Prionas SD, Allison AC. Dual role of tumor necrosis factor-alpha in angiogenesis. *Am J Pathol* 1992;140:539-544
49. Ribatti D, Loria MP, Tursi A. Lymphocyte induced angiogenesis: a morphometric study in the chicken embryo chorioallantoic membrane. *Acta Anat (Basel)* 1991;142:334-338
50. Risau W. Angiogenesis and endothelial cell function. *Arzneimittelforschung* 1994;44:416-417
51. Ando J, Kamiya A. Blood flow and vascular endothelial cell function. *Front Med Biol Eng* 1993;5:245-264
52. Gimbrone MA Jr. Platelet-derived growth factor beta chain promoter contains a cis-acting fluid shear-stress-responsive element. *Proc Natl Acad Sci U S A* 1993;90:4591-4595
53. Ciricillo SF, Edwards MS. Occult malformations with anomalous venous drainage (letter). *J Neurosurg* 1995;82:311-312
54. Wikholm G. Occlusion of cerebral arteriovenous malformations with *n*-butyl cyanoacrylate is permanent. *AJNR Am J Neuroradiol* 1995;16:479-482