



Get Clarity On Generics

Cost-Effective CT & MRI Contrast Agents



FRESENIUS
KABI

WATCH VIDEO

AJNR

Ionic versus nonionic paramagnetic contrast media in differentiating between scar and herniated disk.

C M Nguyen, K C Ho, H An, L H Riley, 3rd, X Rongming and V M Haughton

This information is current as of August 11, 2025.

AJNR Am J Neuroradiol 1996, 17 (3) 501-505
<http://www.ajnr.org/content/17/3/501>

Ionic versus Nonionic Paramagnetic Contrast Media in Differentiating between Scar and Herniated Disk

Canh M. Nguyen, Khang-Cheng Ho, Howard An, Lee H. Riley III, Xu Rongming, and Victor M. Haughton

PURPOSE: To compare the MR contrast enhancement produced by ionic and nonionic paramagnetic contrast media in herniated disk fragments with that in epidural scar tissue. **METHODS:** A recurrent herniated disk was modeled in canines by using laminectomy to place a fragment of disk cartilage in the epidural space. The dogs were studied 88 and 90 days after laminectomy with MR imaging enhanced with an ionic or a nonionic paramagnetic contrast medium. Contrast enhancement of the epidural scar tissue and the epidural disk fragment was measured at 2, 22, and 45 minutes after the injection. **RESULTS:** Contrast enhancement was consistently and significantly higher in scar tissue than in disk fragments, although the difference decreased between 2 and 45 minutes after administration of contrast medium. Enhancement of disk fragments was less with the ionic than with the nonionic contrast medium. Contrast between the disk fragments and scar was also greater with the ionic than with the nonionic medium. **CONCLUSIONS:** The contrast between recurrent disk fragments and scar tissue is affected by the timing of the scan and the choice of contrast medium. Scans obtained immediately after the injection of contrast medium show more contrast between disk fragment and scar than do delayed scans. Recurrent herniated disk fragments are more effectively shown by ionic than by nonionic media.

Index terms: Magnetic resonance, contrast enhancement; Spine, intervertebral disks, herniation; Spine, magnetic resonance; Spine, scar tissue; Animal studies

AJNR Am J Neuroradiol 17:501-505, March 1996

Magnetic resonance (MR) imaging is the primary imaging technique for differentiating recurrent herniated disks from postoperative scarring. Contrast enhancement is used routinely to increase the contrast between the scar tissue and the disk fragments. Disk fragments usually show less enhancement than scar tissue does. However, the enhancement of scar tissue and disk fragments is variable. In previous experimental studies (1, 2), the enhancement of scar tissue varied depending on the time be-

tween injection of contrast medium and imaging, the age of the scar tissue, and the dose of contrast medium used. Cartilage in the intervertebral disk also shows enhancement after intravenous injection of paramagnetic contrast medium (3, 4). The rate and the magnitude of contrast enhancement in the disk differs from that in the scar primarily because the contrast medium reaches the cartilaginous disk by diffusion rather than perfusion (5-20). Enhancement of cartilage caused by diffusion of the contrast medium is a function of the dose of contrast medium injected intravenously and the charge on the molecule (4). Ionic media diffuse into negatively charged cartilage more slowly than do nonionic media. Theoretically, paramagnetic contrast media diffuse into the cartilage in herniated disk fragments as into normal intervertebral disk cartilage. We studied the differential enhancement of disk fragments and scar tissue after intravenous injection of ionic and nonionic contrast media in an experimental model of recurrent disk herniation (2).

Received June 19, 1995; accepted after revision September 27.

Supported by a grant-in-aid from Berlex Laboratories, Seacaucus, NJ.

From the Departments of Radiology (C.M.N., V.M.H.), Pathology (K.-C.H.), and Orthopedic Surgery (H.A., L.H.R., X.R.), Medical College of Wisconsin, Milwaukee.

Address reprint requests to Victor M. Haughton, MD, Department of Radiology, Doyne Clinic/Box 151, 8700 W Wisconsin Ave, Milwaukee, WI 53226.

AJNR 17:501-505, Mar 1996 0195-6108/96/1703-0501

© American Society of Neuroradiology

Materials and Methods

Eleven mongrel dogs (weight range, 17 to 23 kg) underwent laminectomy and placement of a disk fragment in the epidural space followed by MR imaging with ionic and nonionic contrast media. Each animal was sedated with acepromazine (1 mg/kg) and atropine (0.05 mg/kg) intramuscularly and phenobarbital (0.05 mg/kg) intravenously. The animal was intubated, ventilated with a mechanical respirator, and placed prone on an operating table. The skin over the lumbosacral area and tail was prepped and draped for surgery. A left hemilaminectomy was performed (2). The skin and the subcutaneous tissue were incised longitudinally at L3–4. The paraspinal muscles were dissected and retracted to expose the spinous processes and lamina. With a dental drill (Microdrill 5033-001; Hall Surgical, Santa Barbara, Calif) and cutting burr bits, a 7-mm-wide, 17-mm-long defect was created in the L3–4 lamina. The ligamentum flavum was removed, and the nerve root was exposed. The L3–4 disk space was located and incised by a #15 scalpel blade until the nucleus pulposus escaped from the disk space. Bleeding was controlled with gel foam and light compression. The tail was then resected, and the proximal wound was repaired. One intervertebral disk was removed aseptically from the distal portion of the tail. A fragment of fibrocartilage (height, 1.5 mm; diameter, 7 mm) was removed from the disk and inserted into the epidural space through the laminectomy defect anterior to the thecal sac. The laminectomy defect was closed in layers after hemostasis was achieved.

The dogs were allowed to recover from anesthesia in a humidified, warmed environment for 24 hours and then returned to their cages. After surgery, cefazolin sodium was given (1 g/d for 5 days) prophylactically and buprenorphine hydrochloride (1 ampule, intramuscularly) was given as necessary as an analgesic.

In a crossover study design, MR imaging with either gadopentetate dimeglumine or gadoteridol was performed on days 88 and 90 after surgery. For MR imaging, the animal was sedated with acepromazine and atropine and anesthetized with intravenous phenobarbital as was done for the laminectomy. The animal was placed supine with the L3–4 disk space centered on a 3-in (7.5-cm) solenoid coil in the 1.5-T imager. Localizer images were obtained with conventional spin-echo techniques. Either gadopentetate dimeglumine or gadoteridol was injected intravenously at a dose of 0.3 mmol/kg. MR images were obtained in the axial projection immediately before injection and at 2, 22, and 45 minutes after injection of the contrast medium. The parameters used for each of the acquisitions included 3-mm section thickness and 600/25/2 (repetition time/echo time/excitations). The type of contrast medium used was alternated in each dog and between dogs systematically.

Preenhancement and postenhancement images were compared, and the disk fragment and the scar were identified in the epidural space. Signal intensity in the disk fragment and scar tissue in the preenhancement and

postenhancement images was measured with a cursor and a resident computer program. Contrast enhancement was calculated as the change in intensity from baseline divided by the baseline signal intensity. Measurements were entered into a spreadsheet program (Quattro, Borland International, Scotts Valley, Calif). Enhancement for each time period after the injection and enhancement for each contrast medium were recorded and averaged. Contrast enhancement was plotted as a function of time after the injection of contrast medium. Contrast enhancement of disk fragments was compared with that of scar tissue. Differences between enhancement in disk fragment and scar tissue were calculated for each contrast medium and each time period after the injection. The variances of the enhancement for each contrast medium were compared by using Scheffe's *F* test to measure the significance of the differences.

The animals were killed 90 days after surgery. The lumbar spine was removed carefully en bloc and fixed in 10% buffered formalin, decalcified, embedded in paraffin, sectioned axially, and stained with hematoxylin-eosin. The stained sections were examined by the neuropathologist. The location of the disk fragments in the MR images was verified, and the histologic appearance of each disk fragment was characterized.

Results

Of the 11 animals enrolled in the study, 10 had surgery and MR imaging without any complications. One animal developed hindquarter paralysis, was killed 2 days after surgery, and was replaced by another animal. In the other animals, normal activity was seen within 1 week after surgery.

At 88 to 90 days after the surgery, the animals underwent MR imaging with each contrast medium. The disk fragment location in the MR image (confirmed subsequently by histologic section) appeared as a region of decreased enhancement within the epidural scar, regardless of which contrast medium was used (Fig 1).

Average contrast enhancement in scar tissue and in disk fragments after the injection of gadopentetate dimeglumine or gadoteridol is summarized in the Table and in Figure 2. In the MR studies, the disk fragment and scar tissue showed different rates of enhancement. The scar tissue showed greater enhancement at 2 minutes than at 45 minutes after the injection of either contrast medium, whereas the disk fragments tended to increase in signal intensity for 45 minutes after the injection of the contrast medium (Fig 2). Average enhancement for scar tissue was greater than enhancement for disk

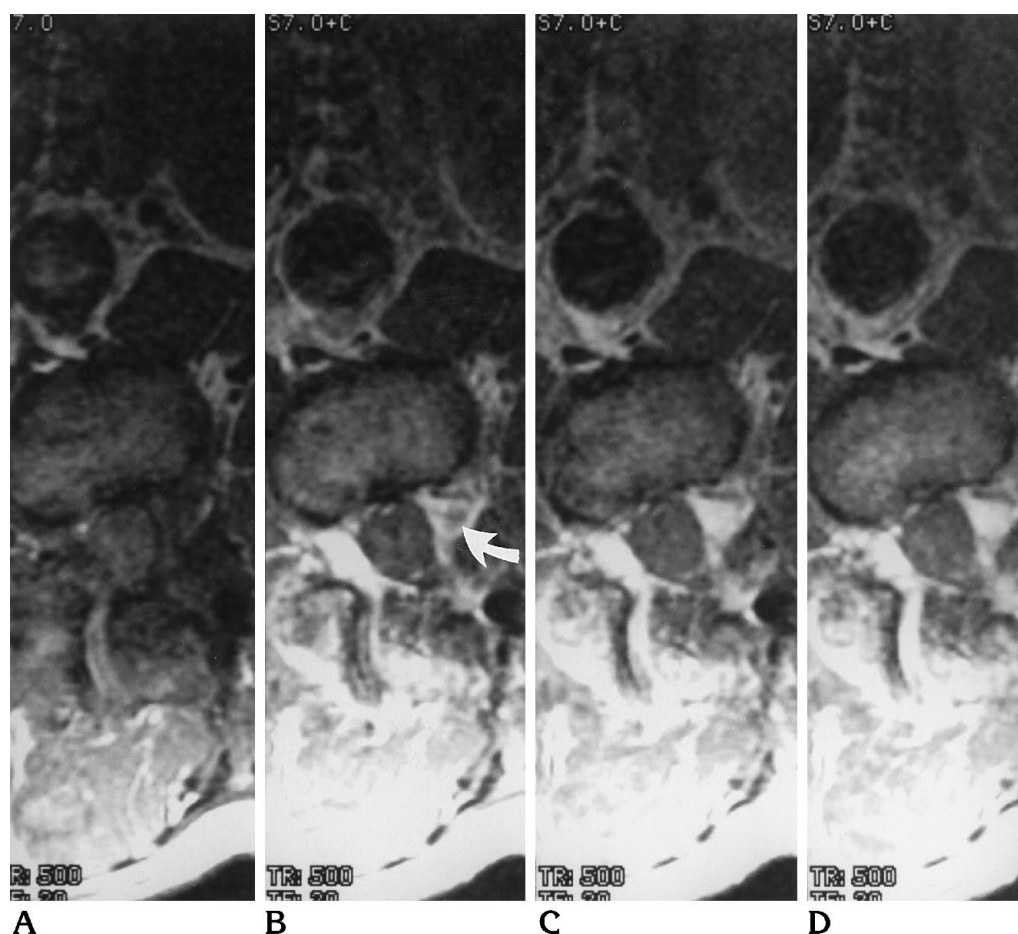


Fig 1. MR images obtained before (A) and 2 (B), 22 (C), and 45 (D) minutes after intravenous injection of 0.3 mmol/kg of gadoteridol in a dog with a surgically modeled recurrent herniated disk. In the unenhanced image (A), the disk fragment is not distinguished from the scar. In the first image after injection of the contrast medium (B), the fragment (arrow) is evident in the enhanced epidural scar. In the images at 22 and 45 minutes, the fragment is less conspicuous because of the increasing enhancement in the disk fragment and the decreasing enhancement in the scar.

fragments for both contrast media at 2, 22, and 45 minutes.

The differences in signal intensity between the disk fragment and the scar tissue for 45 minutes after injection of gadopentetate dimeglumine or gadoteridol is shown in Figure 3. The difference between the signal intensity of scar tissue and that of the disk fragment was greater at 2 minutes than at 22 or 45 minutes. The difference between the signal intensity of the scar tissue and that of the disk fragment was significantly greater for the ionic than the non-ionic medium at 2 and 22 minutes ($P < .01$, Student's *t* test).

Disk fragments in the epidural space were characterized histologically by fibrocartilaginous tissue and variable amounts of fibrosis. All the disk fragments showed infiltrating blood vessels to a marked degree. Inflammatory cell

infiltration was seen in all but 1 of the specimens. In 8 of the 10 animals, histologic examination showed that the fragment was adherent to the dura.

Discussion

This study shows that disk fragments and scar tissue in postoperative spines normally show enhancement on MR images after intravenous injection of a paramagnetic contrast medium. The study confirms previous work indicating that scar tissue shows enhancement maximally soon after intravenous injection, and that enhancement begins to decrease 20 minutes after injection (1, 2, 21, 22). Gradual diffusion of contrast medium into the disk fragment from the adjacent scar tissue probably explains the continuously increasing enhance-

Contrast enhancement in disk fragment and scar tissue after intravenous injection of an ionic or nonionic contrast medium

Location	Type of Contrast Medium	Enhancement at Time after Injection, min		
		2	22	45
Disk	Ionic	0.62 ± 0.1	0.81 ± 0.2	0.89 ± 0.1
	Nonionic	0.76 ± 0.2	0.93 ± 0.2	0.97 ± 0.2
Scar	Ionic	1.29 ± 0.3	1.27 ± 0.4	1.08 ± 0.3
	Nonionic	1.46 ± 0.2	1.50 ± 0.2	1.29 ± 0.2

Note.—Enhancement is expressed as mean \pm SD.

ment of the fragments for the 45-minute period. The scar tissue probably shows enhancement more rapidly than the disk because the blood supply of the scar tissue has a fenestrated capillary endothelium (22). Our study results indicate that disk fragments show less enhancement with the ionic medium than with the nonionic medium and that the contrast between disk fragments and scar is greater after the use of ionic rather than nonionic contrast medium.

The animal model simulates clinical recurrent herniated disks, but there are some differences between the model and the clinical situation. The recurrent herniated disk and scar in humans are not likely to be of the same age. The cartilage in recurrent herniated disk fragments in humans may be larger and more degenerated than in our model. Intervertebral disks from canine tails normally have cartilage similar to that in lumbar intervertebral disks (23). Partial volume averaging is probably greater in measuring enhancement in the small disk fragments in the epidural space in our animals than it is in humans; therefore, the differences are probably underestimated in the experimental animal. The different rates of enhancement for disk and scar tissue cannot be explained on the basis of partial volume errors. The magnitude of enhancement in this study exceeds that in the typical clinical experience because the dose of contrast medium (0.3 mmol/kg) exceeds the usual clinical dose.

The measurements in scar tissue in this study are consistent with previous experimental results. The peaking of enhancement in scar tissue soon after intravenous injection of contrast medium has been described previously (1). The enhancement of cartilage by the process of diffusion has also been reported (3). The degree of enhancement in scar tissue has been shown to correlate with the amount of contrast medium administered (2). Enhancement of the intervertebral disk is affected by the composition of the

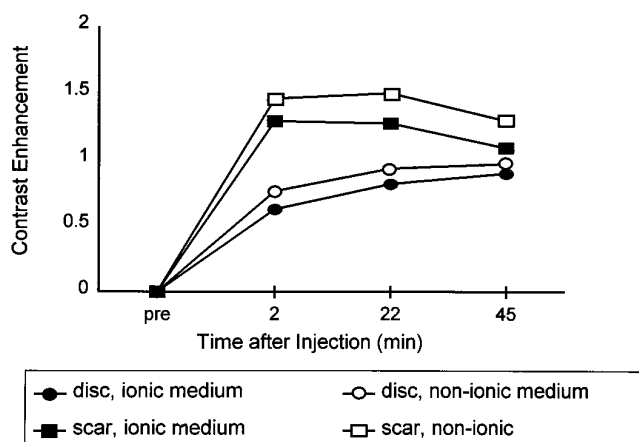


Fig 2. Graph of average contrast enhancement in disk fragments and epidural scar surrounding the disk fragment as a function of time after the injection of 0.3 mmol/kg of gadopentetate dimeglumine or gadoteridol. The data were acquired 88 or 90 days after placement of the disk fragment in the epidural space.

disk. Ionic media diffuse more slowly through cartilage (4) because the fixed negative charges in cartilage, which make it hygroscopic, impede the diffusion of charged particles, such as those in ionic contrast media. The ionic and nonionic contrast media used in the study have similar molecular weights.

We conclude that for optimal enhancement in imaging recurrent herniated disk fragments and scar tissue, it is important to choose the most effective dose and type of contrast medium and the most favorable timing of the imaging. Theoretically, the detection of recurrent herniated disks may be improved by increasing the dose of contrast medium, choosing a contrast medium that diffuses more slowly into cartilage, and obtaining images rapidly after injection of the contrast medium. Our results suggest that

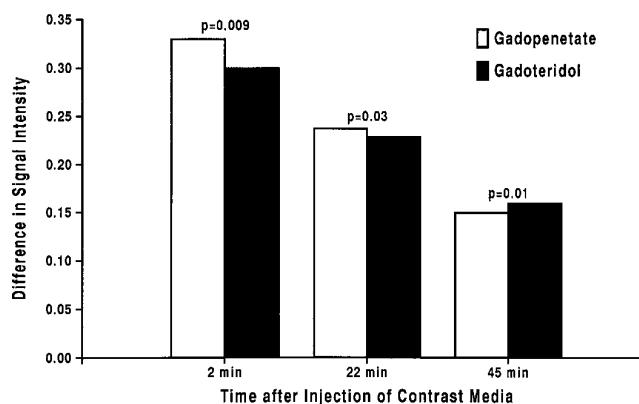


Fig 3. Difference in signal intensity in scar and disk tissue after injection of gadoteridol or gadopentetate dimeglumine.

ionic media diffuse more slowly into disk fragments than do nonionic media. Further work is needed to determine whether use of an ionic medium or larger doses of contrast medium are effective clinically.

Acknowledgment

We thank Debbie Bauer, who facilitated the preparation of the manuscript.

References

1. Nguyen CM, Haughton VM, Ho KC, et al. MR contrast enhancement: experimental study in postlaminectomy epidural fibrosis. *AJNR Am J Neuroradiol* 1993;14:997-1000
2. Nguyen C, An H, Ho KC, Haughton VM, Hasegawa T. Utility of high-dose contrast enhancement for detecting recurrent herniated intervertebral disks. *AJNR Am J Neuroradiol* 1994;15:1291-1295
3. Ibrahim MA, Jesmanowicz A, Hyde J, Estkowski L, Haughton VM. Contrast enhancement of normal intervertebral disks: time and dose dependence. *AJNR Am J Neuroradiol* 1994;15:419-424
4. Ibrahim MA, Haughton VM, Hyde JS. Enhancement of intervertebral disks with gadolinium complexes: comparison of an ionic and a nonionic medium in an animal model. *AJNR Am J Neuroradiol* 1994;15:1907-1910
5. Katz MM, Hargens AR, Garfin SR. Intervertebral disc nutrition. *Clin Orthop* 1986;210:243-245
6. Ogata K, Whiteside LA. Nutritional pathways of the intervertebral disc: an experimental study using hydrogen washout technique. *Spine* 1981;6:211-216
7. Brown M, Tsaltas T. Studies on the permeability of the intervertebral disc during skeletal maturation. *Spine* 1976;1:240-244
8. Maroudas A. Nutrition and metabolism of the intervertebral disc. In: Ghosh P, ed. *The Biology of the Intervertebral Disc*. Boca Raton, Fla: CRC Press, 1988:1-38
9. Brown MD, Tsaltas TT. Studies on the permeability of the intervertebral disc during skeletal maturation. *Spine* 1976;1:240-244
10. Maroudas A. Transport of solutes through cartilage: permeability to large molecules. *J Anat* 1976;122:335-347
11. Urban JPG, Maroudas A, Nachemson A. Nutrition of the intervertebral disk: an in vivo study of solute transport. *Clin Orthop* 1977;129:101-114
12. Maroudas A, Bullough P, Swanson SAV, Freeman MAR. The permeability of articular cartilage. *J Bone Joint Surg [Br]* 1968;50-B:166-177
13. Maroudas A. Physicochemical properties of cartilage in the light of ion exchange theory. *Biophys J* 1968;8:575-595
14. Riley LH III, Banovac K, Martinez OV, Eismont FJ. The qualitative distribution of antibiotics within the rabbit disc. 1994;19:2619
15. Eismont FJ, Weisel SW, Brighton CT, Rothman RH. Antibiotic penetration into rabbit nucleus pulposus. *Spine* 1987;12:254-256
16. Brower TD, Akahoshi Y, Orlic P. The diffusion of dyes through articular cartilage in vivo. *J Bone Joint Surg [Am]* 1962;44-A:456-463
17. Hansen H-J, Ullberg S. Uptake of S35 in the intervertebral discs after injection of S35 sulphate: an autoradiographic study. *Acta Orthop Scand* 1966;30:84-90
18. Nachemson A, Lewin T, Maroudas A, Freeman MA. In vitro diffusion of dye through the endplates and the annulus fibrosus of human intervertebral discs. *Acta Orthop Scand* 1970;41:589-607
19. Brodin H. Paths of nutrition in articular cartilage and intervertebral discs. *Acta Orthop Scand* 1955;24:177-183
20. Kantori TG, Schubert M. The differences in permeability of cartilage to cationic and anionic dyes. *J Histochem Cytochem* 1957;5:28-32
21. Ross JS, Delamarter R, Hueftle MG, et al. Gadolinium-DTPA-enhanced MR imaging of the postoperative spine: time course and mechanism of enhancement. *AJNR Am J Neuroradiol* 1989;10:37-41
22. Bundschuh CV, Modic MT, Ross JS, et al. Epidural fibrosis and recurrent disk herniation in the lumbar spine. *AJNR Am J Neuroradiol* 1988;9:169-173
23. King AS, Smith RN. A comparison of the anatomy of the intervertebral disc in dog and man. *Br Vet J* 1955;3:135-149