



Get Clarity On Generics

Cost-Effective CT & MRI Contrast Agents

 FRESENIUS
KABI

WATCH VIDEO

AJNR

Angioplasty of the occluded internal carotid artery.

M P Spearman, C A Jungreis and L R Wechsler

AJNR Am J Neuroradiol 1995, 16 (9) 1791-1796

<http://www.ajnr.org/content/16/9/1791>

This information is current as
of August 29, 2025.

Angioplasty of the Occluded Internal Carotid Artery

Michael P. Spearman, Charles A. Jungreis, and Lawrence R. Wechsler

PURPOSE: To review patients who have presented with acute strokes from a middle cerebral artery occlusion in whom in addition to the middle cerebral artery thromboembolus, an internal carotid artery occlusion has been present, and in whom angioplasty of these totally occluded internal carotid arteries has been successful. **METHODS:** We reviewed retrospectively our experience in treating acute stroke patients with intracranial, intraarterial urokinase. Six of 27 patients had internal carotid artery occlusions in addition to middle cerebral artery occlusions. Two patients presented with spontaneous carotid dissections for which no further intervention from the ipsilateral internal carotid artery was attempted. In the remaining four internal carotid artery occlusions secondary to atherosclerotic disease, standard guide wires and catheters were negotiated across the level of the internal carotid artery occlusion, which expedited intracranial catheterization for thrombolysis. Subsequently, angioplasty of the internal carotid artery was performed. **RESULTS:** All four occluded internal carotid arteries could be traversed. No new neurologic deficits occurred. No vascular injuries occurred. No deaths occurred. Four- to 6-month follow-up showed all four internal carotid arteries remained patent. **CONCLUSION:** In acute occlusions of the internal carotid artery from atherosclerosis, the occluded vessel can sometimes be recanalized with low morbidity. In addition, endovascular access to the intracranial circulation can be expedited by using the recanalized internal carotid artery.

Index terms: Arteries, carotid, internal; Arteries, transluminal angioplasty

AJNR Am J Neuroradiol 16:1791–1796, October 1995

The prognosis of patients with acute cerebral ischemia depends on the degree of ischemia and the duration of the ischemic period. Previous studies have shown that an ischemic “window” is present during which neurologic deficits are potentially reversible (1, 2). This has been corroborated in experimental studies with animals in which early restoration of flow to experimentally occluded middle cerebral arteries (MCA) has salvaged the ischemic area (3–6). Thus, early intervention appears to be imperative.

We present a series of four acute stroke patients in which our attempts to minimize the

delay in treatment of an offending MCA embolus led us to attempt traversing an ipsilateral occluded internal carotid artery (ICA) to gain access to the MCA for the administration of local intraarterial urokinase.

Materials and Methods

We reviewed retrospectively our experience in treating acute stroke patients with intracranial, intraarterial urokinase. In the review, we focused on patients who presented initially with acute neurologic deficits characteristic of an embolus to the MCA. Angiographically, 4 (male patients, ages 54, 58, 65, and 73) of 27 patients (13 male, 14 female) had ICA occlusions in addition to MCA occlusions (Table). All patients presented with an interval of less than 6 hours from onset of clinical findings to the infusion of the thrombolytic agent. Computed tomographic scans were performed before the institution of therapy.

Arteriography was performed via a femoral arterial puncture, and a standard 5F cerebral catheter was placed initially into the common carotid artery (CCA). Digital subtraction angiography was performed to demonstrate best the entire anticipated segments of the ICA as well as views of the cerebral circulation to demonstrate best the MCA territory.

Received December 22, 1994; accepted after revision June 8, 1995.

From the Departments of Radiology (M.P.S.), Radiology and Neurological Surgery (C.A.J.), and Neurology (L.R.W.), University of Pittsburgh (Pa) Medical Center.

Address reprint requests to Michael P. Spearman, MD, Department of Radiology, University of Pittsburgh Medical Center, 200 Lothrop St, Pittsburgh, PA 15213-2582.

AJNR 16:1791–1796, Oct 1995 0195-6108/95/1609–1791

© American Society of Neuroradiology

Four patients with internal carotid and middle cerebral artery occlusions

Sex/Age, y	Delay of Treatment after Ictus, h	Findings on Angiography	Residual Stenosis after Angioplasty	Urokinase Dose, U	Presenting Clinical Findings	Final Outcome	Treatment
M/73	6	ICA occlusion at origin; reconstitution of ICA via external carotid artery; occlusion M-2 division	56%	300 000	Sudden onset of aphasia and R hemiplegia after hip surgery	10 mo after stroke—fluent speech; no trouble with naming or comprehension; no movement of right extremities; walks with short leg brace and quad cane	Warfarin sodium for 10 mo
M/54	5	ICA occlusion at origin; no reconstitution of ICA or any intracranial filling	Difficult to measure because of intimal crack	1 000 000	Sudden onset of restlessness; global aphasia, R facial weakness, field cut, dense R hemiplegia; no response to pain on R	9 mo after stroke—limited speech; follows some, not all, commands; walks with quad cane; independent for activities of daily living; carotid endarterectomy in 9/94 (5 mo)	Warfarin sodium for 5 mo, then aspirin after carotid endarterectomy on L
M/58	6	ICA occlusion at origin; reconstitution of ICA via external carotid artery; MCA main stem occlusion	40%	250 000	Tingling in L lower extremity day before; sudden onset L sided paresis	8 mo after stroke—mild L sided weakness in arm and leg; walks without assistance; normal tone on L	Warfarin sodium for 8 mo, then changed to aspirin
M/65	6	ICA occlusion at origin; reconstitution of ICA via external carotid artery; MCA main stem occlusion	60%	300 000	Spells of R hand weakness and numbness for 3 d; sudden aphasia, R hemiparesis	5 mo after stroke—followed occasional 1 step command; R hemiplegia and sensory loss	Aspirin; no follow-up in office

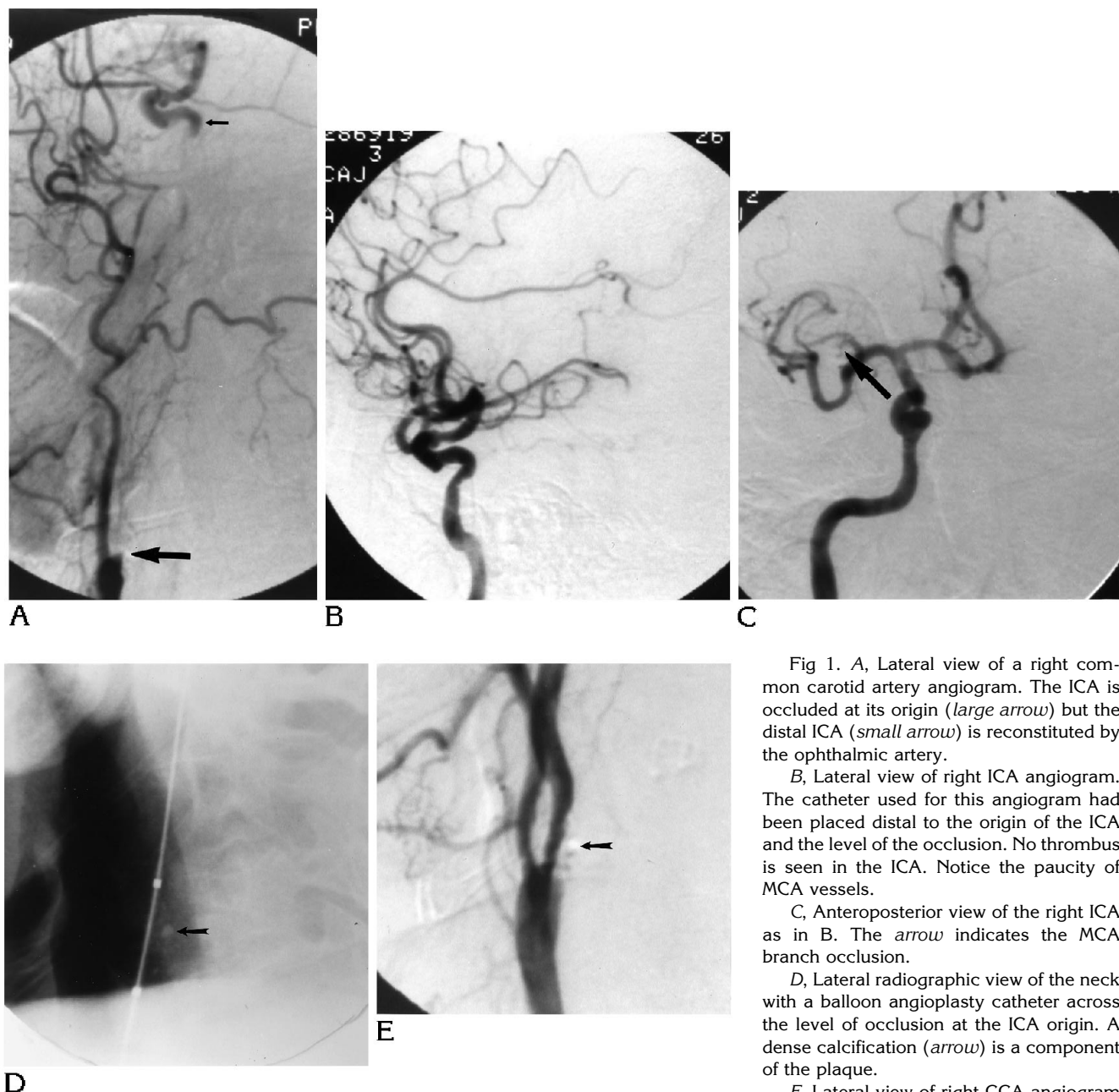


Fig 1. A, Lateral view of a right common carotid artery angiogram. The ICA is occluded at its origin (*large arrow*) but the distal ICA (*small arrow*) is reconstituted by the ophthalmic artery.

B, Lateral view of right ICA angiogram. The catheter used for this angiogram had been placed distal to the origin of the ICA and the level of the occlusion. No thrombus is seen in the ICA. Notice the paucity of MCA vessels.

C, Anteroposterior view of the right ICA as in B. The *arrow* indicates the MCA branch occlusion.

D, Lateral radiographic view of the neck with a balloon angioplasty catheter across the level of occlusion at the ICA origin. A dense calcification (*arrow*) is a component of the plaque.

E, Lateral view of right CCA angiogram after angioplasty shows some residual stenosis but patency of the ICA. The calcification (*arrow*) in the plaque is again noted.

Subsequently, a steerable hydrophilic 0.038-in guide wire (Medi-tech, Watertown, Mass) was gently negotiated from the CCA through the occlusion into the distal cervical ICA. The 5F catheter then was easily advanced over the wire into the distal cervical ICA. Repeat angiography of the ICA was performed with repeat imaging of the cerebral circulation with attention to the MCA territory (Fig 1B and C). The patients were placed on systemic heparinization at this point.

A microcatheter, Tracker 18 (Target Therapeutics, San Jose, Calif), was placed in a coaxial fashion into the MCA clot for initiation of thrombolysis. Urokinase was infused (Table) with intermittent repeat arteriography done to assess the degree of thrombolysis.

After completion of the intracranial thrombolysis, the catheter system was exchanged for a standard balloon angioplasty catheter 5 × 40-mm balloon (Medi-tech, Watertown, Mass). The balloon was inflated at the level of

the previous occlusion in the ICA for between 10 and 30 seconds, and then the balloon was deflated (Fig 1D). The catheter was withdrawn into the CCA, and a repeat angiogram was done to assess the ICA after angioplasty and the cerebral circulation (Fig 1D). The patients were transferred to the neurosurgical intensive care unit for monitoring and were kept on systemic heparinization for 3 days before removal of the femoral arterial sheath.

Results

Occlusion at the origin of the ICA was identified in all four patients. In three patients, the cavernous carotid artery was identified as patent via collateral flow from the external carotid branches. With gentle probing at the site of occlusion, the guide wire simply advanced from the CCA into the ICA in all cases. A standard 5F catheter then could be easily advanced over the guide wire into the distal cervical ICA. Aspiration of the 5F catheter resulted in brisk back bleeding, except in the one case in which the distal ICA was not reconstituted.

No arterial dissections or transmural vascular tears occurred as a result of traversing the occluded segment. No apparent distal embolization resulted during the passage of the catheter through the area of occlusion. Because this allowed placement of the base catheter ipsilateral to the side of anticipated thrombolysis, the subsequent intracranial catheterization was expedited in all cases. Two patients had significant bradycardia during balloon dilatation that resolved spontaneously on deflation of the balloon. Postangioplasty angiograms showed patency of the ICA in all four cases (Fig 1D).

None of the patients developed intracranial hemorrhage, and no deaths occurred. The degree of residual stenosis varied from 40% to 60% after angioplasty. In one patient, the degree of residual stenosis was difficult to determine accurately because of an intimal crack related to the angioplasty.

Two patients had significant clinical improvement after thrombolytic treatment. The third had minor improvement in leg strength after treatment but still suffered major deficits long term. The fourth patient had no clinical changes as a result of the intervention. Four- to 6-month follow-up carotid duplex scanning in three cases demonstrated patent ICAs with no evidence of high-grade narrowing. The patient in whom the postangioplasty arteriogram demonstrated an intimal crack, making it difficult to determine accurately the degree of residual ste-

nosis, returned for a repeat angiogram at 6 months. At that time, a 70% short focal residual stenosis of the ICA was demonstrated, with the remainder of the ICA remaining normal. This patient subsequently underwent an uncomplicated and uneventful carotid endarterectomy.

Discussion

Over the past several years, neither surgical nor endovascular repair of a complete ICA occlusion has been common. Early studies aimed at restoring blood flow to ischemic human brain tissue included trials of high-dose intravenous urokinase (7). These early studies, however, were fraught with a high number of fatal intracerebral hemorrhages. Selective arterial infusions then were attempted with the hope of performing thrombolysis without the untoward systemic effects (8–14). Infusions of the thrombolytic agents at the level of the proximal ICA showed only modest success in vessel recanalization. More encouraging results have been appearing from reports of highly selective infusions, but good controlled studies to establish the benefits still are lacking. Similarly, some reports of carotid endarterectomy within the first 3 weeks after an established cerebral infarction also have been discouraging, with suggestions of an increased risk of subsequent hemorrhage into the region of the infarction (15–16). Sundt described patients with unstable or progressing focal neurologic deficit as the highest-risk group in his series for developing a persistent neurologic deficit after carotid endarterectomy. He did recognize, however, that although the complication rate was the highest in this group of patients, some of the most dramatic benefits were achieved in this group (17). Other authors have reported spontaneous cerebral hemorrhage after carotid endarterectomy but have indicated that the hemorrhages seemed to have been associated with uncontrolled hypertension during the postoperative period (18, 19). Still others have reported relatively good immediate and long-term results with a reasonably low surgical morbidity and mortality (20).

In our four patients, occlusion of the proximal ICA was present having an appearance consistent with thrombotic occlusion secondary to atherosclerosis. The technique of traversing the occluded ICA was successful in all four patients. In contrast, we did not attempt to recanalize the

ICA in the two patients with angiographic evidence of arterial dissection. The analogous technique of traversing occluded vascular segments has gained success in the coronary arteries, in bypass grafts (21–23), and in the extremities (24, 25). In particular, results of coronary angioplasty for chronic total occlusions have generally shown no increased incidence of acute complications (26). A major concern in traversing an occluded ICA is the possibility that a thrombus present in the ICA distal to the occlusion may be dislodged, further compromising the patient. None of the patients in our series developed further apparent emboli from the passage of the catheter through the occluded segment, although we have based this conclusion on clinical grounds coupled with a comparison of angiograms made before and after the procedure. Thus, we may have been insensitive to small new emboli.

Previous reports have emphasized that when an ICA is occluded, thrombus forms from the site of occlusion at the CCA bifurcation to the next branch of the ICA, usually the ophthalmic artery (27). This thrombus has been thought to be the source of embolic events to the MCA, termed *distal stump embolus*. Our observation that the ICA distal to the bifurcation was entirely free of thrombus at first seems consistent with this hypothesis, with the presumption being that the ICA clot embolized to the MCA. On further review, however, we must reconsider such a mechanism. If, in fact, the MCA embolus was attributable to the dislodged ICA clot, then it should have been substantially larger. That is, if an ICA thrombus that had been the length (greater than 10 cm) and caliber (about 4 mm) of the entire ICA were suddenly deposited into the MCA, one would expect a much larger area of vascular occlusion than that demonstrated (main stem of MCA). Furthermore, the force required to move the clot out of the ICA remains obscure because the ICA is occluded and therefore has no antegrade flow. Alternatively, a presumptive mechanism for a distal stump embolus might be that only a short length of clot dislodges from the distal ICA secondary to turbulent flow at the distal branch point. If this latter mechanism is correct, however, then the rest of the ICA still should have clot within it, which was not the case.

Therefore, we must postulate a different mechanism for thromboembolic disease when it is associated with an ipsilateral ICA occlusion.

Initially, the atherosclerotic changes at the carotid bifurcation cause clot formation. Before complete ICA occlusion, the antegrade flow causes the clot to embolize to the MCA. The ICA then reforms a thrombus. Sometimes, this second thrombus formation is occlusive, and sometimes it is not. The onset of clinical symptoms probably corresponds to the time of MCA occlusion. The time when the ICA occludes is not certain. The implications, however, are that if intervention is early enough, then successful reconstitution of the ICA should be likely.

In conclusion, we recognize that this is a small series and that more experience will be required to establish the true safety and efficacy of revascularizing acute carotid occlusions. Nevertheless, in acute occlusions of the ICA from atherosclerotic disease, the ICA can sometimes be used as a conduit to the distal intracranial territory with apparent low morbidity. In addition, early surgical or endovascular intervention in acute carotid occlusions may salvage the vessel.

References

1. Astrup J, Siesjö BK, Symon L. Thresholds in cerebral ischemia: the ischemic penumbra. *Stroke* 1981;12(6):723–725
2. Wise RJS, Bernardi S, Frackowiak RSJ, Legg NJ, Jones T. Serial observations on the pathophysiology of acute stroke: the transition from ischemia to infarction as reflected in regional oxygen extraction. *Brain* 1983;106:197–222
3. Sundt TM Jr, Grant WC, Garcia JH. Restoration of middle cerebral artery flow in experimental infarction. *J Neurosurg* 1969;311–322
4. Crowell RM, Olsson Y, Klatzo I, Ommaya A. Temporary occlusion of the middle cerebral artery in the monkey: clinical and pathological observation. *Stroke* 1970;1:439–448
5. Jones TH, Morawetz RB, Crowell RM, et al. Thresholds of focal cerebral ischemia in awake monkeys. *J Neurosurg* 1981;54:773–782
6. Del Zoppo GJ, Copeland BR, Waltz TA, Zyff J, Plow EF, Harker LA. The beneficial effect of intracarotid urokinase on acute stroke in a baboon model. *Stroke* 1986;17:638–643
7. Hanaway J, Torack R, Fletcher AP, Landau WM. Intracranial bleeding associated with urokinase therapy for acute ischemic hemispherical stroke. *Stroke* 1976;7:143–146
8. Zeumer H, Hacke W, Ringelstein EB. Local intraarterial thrombolysis in vertebrobasilar thromboembolic disease. *AJNR Am J Neuroradiol* 1983;4:401–404
9. Jungreis CA, Wechsler LR, Horton JA. Intracranial thrombolysis via a catheter embedded in a clot. *Stroke* 1989;20:1578–1580
10. Mori E, Tabuchi M, Yoshida T, Yamadori A. Intracarotid urokinase with thromboembolic occlusion of the middle cerebral artery. *Stroke* 1988;19:802–812
11. Hacke W, Zeumer H, Ferbert A, Bruckmann H, del Zoppo GJ. Intraarterial thrombolytic therapy improves outcome in patients with acute vertebrobasilar occlusive disease. *Stroke* 1988;19:1216–1222

12. Casto L, Moschini L, Camerlingo M, et al. Local intraarterial thrombolysis for acute stroke in the carotid artery territories. *Acta Neurol Scand* 1992;86:308-311
13. del Zoppo GJ, Ferbert A, Otis S, et al. Local intraarterial fibrinolytic therapy in acute carotid territory stroke. *Stroke* 1988;19:307-313
14. Wildenhain SL, Jungreis CA, Barr J, Mathis J, Wechsler L, Horton JA. CT after intracranial intraarterial thrombolysis for acute strokes. *AJNR Am J Neuroradiol* 1994;15:487-492
15. Bruetman MF, Fields WS, Crawford ES, DeBakey ME. Cerebral hemorrhage in carotid artery surgery. *Arch Neurol* 1963;458-467
16. Wylie EJ, Hein MF, Adams JE. Intracranial hemorrhage following surgical revascularization for treatment of acute strokes. *Neurosurgery* 1964;21:212-215
17. Sundt TM Jr, Sandok BA, Whisnant JP. Carotid endarterectomy: complications and preoperative assessment of risk. *Mayo Clinic Proc* 1975;50:301-306
18. Reith HB, Edelman M, Reith C. Spontaneous intracerebral hemorrhage following carotid endarterectomy: experience of 328 operations from 1983-1988. *Int Surg* 1992;77:224-225
19. Caplan LR, Skillman J, Ojemann R, Fields WS. Intracerebral hemorrhage following carotid endarterectomy: a hypertensive complication? *Stroke* 1978;5:457-460
20. McCormick PW, Spetzler RF, Bailes JE, Zabramski JM, Frey JL. Thromboendarterectomy of the symptomatic occluded internal carotid artery. *J Neurosurg* 1992;76:752-758
21. de Swart JBRM, van Gelder LM, van der Krieken AM, El Gamal MIH. A new technique for angioplasty of occluded coronary arteries and bypass grafts, not associated with acute myocardial infarction. *Cathet Cardiovasc Diagn* 1987;13:419-423
22. Mosseri M, Admon D, Hasin Y, Kriwitzki M, Rosenbeck S, Gotsman M. Percutaneous angioplasty of totally occluded coronary vein bypass grafts: case histories. *Angiology J Vasc Dis* 1990;41:44-52
23. Marx M, Armstrong W, Brent B, Wack J, Bernstein R, Gregoratos G. Transcatheter recanalization of a chronically occluded saphenous aortocoronary bypass graft. *AJR Am J Roentgenol* 1987;148:375-377
24. O'Donnell T. Arterial diagnosis and management of acute thrombosis of the lower extremity. *Can J Surg* 1993;36:349-353
25. Farina C, Mingoli A, Schultz R, et al. Percutaneous transluminal angioplasty versus surgery for subclavian artery occlusive disease. *Am J Surg* 1989;158:511-514
26. Ruocco NA Jr, Ring ME, Holubkov R, Jacobs AK, Detre KM, Faxom DP. Results of coronary angioplasty of chronic total occlusions (the National Heart, Lung, and Blood Institute 1985-1986 percutaneous transluminal angioplasty registry). *Am J Cardiol* 1992;69:69-76
27. Finklestein S, Kleinman GM, Cuneo R, Baringer JR. Delayed stroke following carotid occlusion. *Neurology* 1980;30:84-88

Please see the commentary on page 1797 in this issue.