



## Get Clarity On Generics

Cost-Effective CT & MRI Contrast Agents

**FRESENIUS  
KABI**

[WATCH VIDEO](#)

# AJNR

## **Congenital nasal piriform aperture stenosis.**

A Bignault and M Castillo

*AJNR Am J Neuroradiol* 1994, 15 (5) 877-878

<http://www.ajnr.org/content/15/5/877>

This information is current as  
of August 29, 2025.

# Congenital Nasal Piriform Aperture Stenosis

Ann Bignault and Mauricio Castillo

**Summary:** A 3-1/2-month-old girl presented with respiratory difficulty secondary to nasal obstruction. CT demonstrated stenosis of the nasal piriform aperture. The presentation of this entity is similar to that of posterior choanal atresia.

**Index terms:** Nares; Nose, abnormalities and anomalies; Nose, computed tomography; Infants

Stenosis of the nasal piriform aperture is believed to occur secondary to overgrowth of the medial maxilla. Although rare, congenital stenosis of the piriform aperture should be included in the differential diagnosis of nasal obstruction in newborns and infants.

## Case Report

A 3-1/2-month-old girl presented with noisy breathing and apnea during feedings of 8-week duration. The patient was the product of a twin pregnancy and was born at 31 weeks gestation. Birth weight was 1195 g. Her twin sister had alobar holoprosencephaly and multicystic kidney disease and died shortly after birth. During her initial hospitalization, our patient had two transfontanelle sonograms, which showed bilateral grade II hemorrhages but no midline anomalies. No history of maternal teratogen exposure was elicited.

Evaluation at presentation revealed oxygen desaturation as low as 55% on room air while feeding. Other pertinent findings on physical examination included nasal apertures partially obstructed by lateral soft-tissue shelves, a glabellar hemangioma, and mild bilateral fifth finger clinodactyly. The results of routine laboratory and thyroid function tests were normal, as were serum cortisol levels. A computed tomography (CT) scan using 3-mm-thick sections in axial and coronal projections through the paranasal sinuses was obtained and showed an increase in the size of the medial aspect of the maxilla, giving rise to stenosis of the nasal piriform aperture (Fig 1, A and B). A single and unerupted megaincisor was present (Fig 1B). No choanal atresia was seen. Sublabial resection of the medial maxilla and resection of the inferior turbinates were performed. At follow-up 1 month later, the patient was asymptomatic.

## Discussion

The piriform aperture is a term used to refer to the anterior nasal openings. Congenital stenosis of the piriform aperture is a recently described syndrome (1,2). It manifests itself during the neonatal period and is clinically indistinguishable from the more common bilateral atresia or stenosis of the posterior nasal choanae. The exact mechanism responsible for piriform aperture stenosis is unclear, but bone overgrowth of the nasal process of the maxilla is believed to cause the clinical symptoms directly (1).

The diagnosis is easily confirmed using CT. Additionally, in these patients CT may detect a single large central upper incisor. Of the six cases of piriform aperture stenosis described by Arlis and Ward (2), four had megaincisors. Of these four patients, two had endocrine abnormalities thought to be secondary to abnormal pituitary-adrenal axes. Megaincisors are also seen in patients with the autosomal dominant variety of holoprosencephaly; therefore, patients with piriform aperture stenosis and megaincisor should be screened for cerebral midline anomalies. However, it is believed that piriform aperture stenosis with no megaincisor is probably an isolated finding, which in itself is not related to intracranial abnormalities (2). Likewise, a single megaincisor may be an isolated anomaly or associated with holoprosencephaly (3).

In our patient, CT indicated stenosis of the piriform aperture and a single megaincisor. Brain sonograms, however, were normal. Because the results of laboratory endocrine tests were normal, magnetic resonance of the brain was not deemed necessary. It is curious to note that although our patient had no midline brain anomalies, her twin

Received December 4, 1992; accepted for publication February 1, 1993.

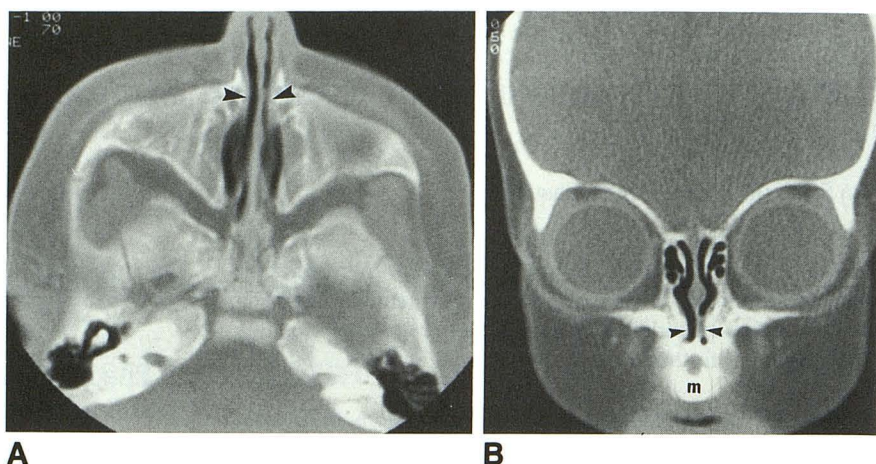
From the Department of Radiology, University of North Carolina School of Medicine, Chapel Hill, NC.

Address reprint requests to M. Castillo, MD, Department of Radiology, CB# 7510, University of North Carolina School of Medicine, Chapel Hill, NC 27599-7510.

AJNR 15:877-878, May 1994 0195-6108/94/1505-0877 © American Society of Neuroradiology

Fig. 1. A, Axial 3-mm-thick CT section (bone window settings) at the level of the inferior nasal cavity shows overgrowth of the medial aspects of the maxilla (*arrowheads*), giving rise to stenosis of the nasal piriform aperture.

B, Coronal 3-mm-thick CT section through the anterior portion of the nasal cavity again demonstrates the overgrowth of the medial maxilla (*arrowheads*), which causes severe narrowing of the airway. Note the single upper megaincisor (m).



sister did have alobar holoprosencephaly. The abnormalities in both siblings, therefore, are probably related to a familial form of holoprosencephaly with variable expressivity. Congenital stenosis of the nasal piriform aperture should be included in the differential diagnosis of nasal obstruction in the neonatal period.

## References

1. Brown OE, Myer CM, Manning SC. Congenital nasal pyriform aperture stenosis. *Laryngoscope* 1989;99:86-99
2. Arlis H, Ward RF. Congenital nasal pyriform aperture stenosis. *Arch Otolaryngol Head Neck Surg* 1992;118:989-991
3. Cohen MM. Perspectives on holoprosencephaly. I. Epidemiology, genetics, and syndromology. *Teratology* 1989;40:211-235