



Get Clarity On Generics

Cost-Effective CT & MRI Contrast Agents

 FRESENIUS
KABI

[WATCH VIDEO](#)

AJNR

Endovascular occlusion of intracranial aneurysms with electrically detachable coils: correlation of aneurysm neck size and treatment results.

A Fernandez Zubillaga, G Guglielmi, F Viñuela and G R Duckwiler

This information is current as of August 20, 2025.

AJNR Am J Neuroradiol 1994, 15 (5) 815-820
<http://www.ajnr.org/content/15/5/815>

Endovascular Occlusion of Intracranial Aneurysms with Electrically Detachable Coils: Correlation of Aneurysm Neck Size and Treatment Results

Amelia Fernandez Zubillaga, Guido Guglielmi, Fernando Viñuela, and Gary R. Duckwiler

PURPOSE: To devise a method to measure aneurysm neck size on angiographic films, and to correlate the sizes obtained with the extent of endovascular aneurysm occlusion, performed with electrically detachable coils. **METHODS:** The angiograms of 79 intracranial aneurysms treated by endovascular occlusion using electrically detachable coils were retrospectively analyzed. A method using the average reported caliber of the major intracranial vessels was applied to determine the aneurysm neck sizes on the diagnostic angiograms. The cases were divided into two groups according to neck size, 4 mm being the discriminative value for small and wide necks. The posttreatment angiogram of each case was analyzed to evaluate the degree of occlusion achieved by the technique. **RESULTS:** Necks were successfully measured in 95% of the aneurysms. Complete aneurysm thrombosis was observed in 85% of the small-necked aneurysms and in 15% of the wide-necked aneurysms. **CONCLUSIONS:** Accurate angiographic measurements of neck diameter can be obtained in most aneurysms. The size of an aneurysm neck correlates well with the results of the endovascular treatment. Small-necked aneurysms can be satisfactorily occluded with this technique. In wide-necked aneurysms this technique should be reserved for lesions having a high surgical risk.

Index terms: Aneurysm, intracranial; Aneurysm, embolization; Interventional instrumentation, coils

AJNR Am J Neuroradiol 15:815–820, May 1994

In the neurosurgical literature intracranial aneurysms are classically subdivided into saccular and fusiform, depending on the presence or absence of a definite aneurysm neck (1). Although a great deal of attention has been paid to the dimensions of the sac of saccular aneurysms (small, large, and giant), less information is available on the size of the aneurysm neck. This is probably because, in general, small aneurysms have small necks and large and giant aneurysms have wide

necks (2). Therefore the concept of aneurysm neck size tends to be incorporated in the general concept of aneurysm dimension. From the neurosurgical perspective, the technical surgical difficulty is affected more by the size of the aneurysm sac or by the presence of calcification in the neck area than by the size of the neck. This is because the physical presence of the sac acts as an obstacle to adequate exposure and clipping of the neck—a significant factor, especially in large and giant aneurysms. Conversely, from the point of view of neuroendovascular therapy, the diameter of the aneurysm neck as opposed to the dimensions of the sac seems to be the critical factor, particularly in foreseeing whether the treatment will be complete or not.

Over a 3-year period, 79 intracranial saccular aneurysms were treated with electrically detachable coils (Guglielmi detachable coils, Target Therapeutics, Fremont, Calif) and electrothrombosis (3, 4) at our institution. Because neck size seemed to be an important determinant for the

Received June 23, 1993; accepted pending revision August 31; revision received December 27.

This work was supported by National Institutes of Health Grant HL46286-01.

From the Department of Radiological Sciences, Endovascular Therapy Service, University of California at Los Angeles.

Address reprint requests to Guido Guglielmi, MD, Endovascular Therapy Service, Department of Radiological Sciences, University of California Los Angeles Medical Center, 10833 Le Conte Ave, Los Angeles, CA 90024-1721.

AJNR 15:815–820, May 1994 0195-6108/94/1505-0815

© American Society of Neuroradiology

treatment results (5), a method was devised to measure accurately the size of the aneurysm neck on diagnostic angiograms in an attempt to find a correlation between neck size and treatment results.

Material and Methods

Case Material

The Guglielmi detachable coil technique was developed at the University of California Los Angeles in 1989 (3). The occlusive agent is a detachable platinum coil delivered through a microcatheter positioned within the aneurysm. The entire detachable coil consists of a proximal stainless steel delivery wire, soldered to an extremely soft coil made of platinum (3, 4). The platinum portion is manufactured with various lengths and diameters. It has a circular memory that allows the coil, once outside the microcatheter, to adjust to the shape of the sac, causing little stress on the aneurysm walls. Detachment is achieved by applying a low positive direct electric current to the delivery wire. The stainless steel delivery wire is laminated with a thin layer of Teflon, except for its final 2 mm, which are uninsulated. Electrolysis of this uninsulated portion nearest to the platinum coil occurs within 4 to 12 minutes. The coil behaves as a positively charged electrode, attracting negatively charged blood particles, such as white blood cells, red blood cells, platelets, and fibrinogen, and promoting clot formation. The electric current is not applied until the platinum coil is in a suitable position inside the aneurysm. If the positioning is not ideal, the coil can be withdrawn and repositioned, or exchanged for a different-size one. This property allows control of the coil delivery and protection of the parent vessel from accidental coil migration. More than one coil can be placed inside an aneurysm, the goals being a tight packing of the aneurysm sac and bridging of the mesh of coils across the aneurysm neck.

Over a 3-year period, 79 intracranial aneurysms were treated with the Guglielmi detachable coil endovascular technique at our institution. The diagnostic angiograms of all patients were retrospectively reviewed to measure the aneurysm neck size using the method described below. Five aneurysms were excluded from this study either because they were fusiform (3 cases), or because the goal of the treatment had been the occlusion of a carotid-cavernous fistula rather than aneurysm occlusion (2 cases of ruptured intracavernous carotid aneurysms). The location of the remaining 74 saccular aneurysms was as follows: basilar artery bifurcation in 24 cases, carotid-posterior communicating artery junction in 11, carotid-ophthalmic artery junction in 11, middle cerebral artery in 5, vertebro-basilar junction in 4, posterior inferior cerebellar artery in 4, cavernous carotid artery in 4, internal carotid artery bifurcation in 3, superior cerebellar artery in 2, posterior cerebral artery in 2, anterior communicating artery in 1, anterior-inferior cerebellar artery in 1, midbasilar artery in 1, and trigeminal artery in 1. Thirty-one aneurysms were

small (<12 mm); 26 were large (12 to 25 mm); and 17 were giant (>25 mm).

This retrospective analysis was undertaken to evaluate a possible relationship between aneurysm neck size and degree of aneurysm occlusion. The degree of occlusion was assessed by reviewing the latest posttreatment follow-up angiogram of each patient. Each case was considered: (a) incomplete occlusion if a portion of the aneurysm was still filling with contrast at the follow-up angiogram, whether the residual part was a neck remnant or a portion of the aneurysm sac; and (b) complete occlusion if the sac and the neck of the aneurysm were totally occluded at the follow-up angiogram.

Technique

In the method devised we consider the diameter of the internal carotid artery or the basilar artery as a reference value and aim to obtain accurate measurements of aneurysms and their necks on angiographic films.

Radü and du Boulay (6) reviewed 50 cerebral angiograms performed with a constant focus-film distance of patients with nonvascular diseases. They measured the size of the internal carotid artery 5 mm proximal to its bifurcation. An average internal diameter of 3.35 mm was obtained after correction for radiographic magnification (reported angiographic measurements ranged from 3.98 to 4.74 mm [mean, 4.36 mm], and the magnification factor was 130%). Müller et al (7) used the same method in 222 cases. They determined their magnification factor (120%) by taking radiographs of a dry skull in which a 10-mm metallic sphere had been placed at the site of the left or the right internal carotid artery bifurcation. Their angiographic measurements, also taken at 5 mm proximal to the internal carotid artery bifurcation, were 3.32 to 4.68 mm (mean, 4.04). After correction for magnification, the actual mean arterial diameter was therefore calculated at 3.37 mm. Wollschlaeger et al (8) measured the actual sizes of the internal carotid artery and the basilar artery in 291 nonselected brain specimens. Both internal carotid arteries and both vertebral arteries of the specimens were injected with a barium gelatin suspension upon removal. They obtained measurements ranging from 2.70 to 4.55 mm (mean, 3.63) for the internal carotid artery 3 mm proximal to its bifurcation, and from 2.70 to 4.24 mm (mean, 3.27) for the basilar artery 3 mm distal to the vertebrobasilar junction. The reference value used in this study was thus obtained by determining the average of the measurements given by the above-cited authors (Table).

The diagnostic angiograms of 74 aneurysms were analyzed (see Case Material). Most of the images were obtained with a digital subtraction technique. The projection in which the neck was best identified in its full extent was selected for the measurement. Using a transparent ruler to an attempted accuracy of one-quarter of a millimeter, the diameter of the contrast filled lumen of the internal carotid artery or the basilar artery (a), and the largest width of the neck (n) were measured on the same angiographic film. The sites of vessel measurements were as follows: the

Average diameter of the internal carotid artery and basilar artery

	Radü (6)	Müller (7)	Wollschlaeger (8)	
Artery ^a	Internal Carotid Artery	Internal Carotid Artery	Internal Carotid Artery	Basilar Artery
Number of cases	50	222	291	291
Measurement (mm)	4.36 ^b	4.04 ^b	3.63 ^c	3.27 ^c
Magnification factor (%)	130	120
Real/corrected value (mm)	3.35	3.37	3.63	3.27

^a Measurement sites: internal carotid artery, 3 to 5 mm proximal to the internal carotid artery bifurcation; basilar artery, 3 mm distal to the vertebrobasilar junction.

^b Angiographic measurement.

^c Direct measurement.

internal lumen of the internal carotid artery was 5 mm proximal to its bifurcation for aneurysms of the anterior circulation; the internal lumen of the basilar artery was 3 mm distal to the vertebrobasilar junction for posterior circulation aneurysms. The real neck width was derived from the following algebraic formula, assuming that the proportion between real neck width (N) and the reference vessel diameter (A) from the literature is equal to the proportion between neck measurement (n) and internal carotid artery or basilar artery measurement (a) on the angiogram (Figs 1–3): $N = (n \times A)/a$.

Results

In the literature, the neck of intracranial saccular aneurysms has been classified into small (1 to 3 mm) or large (4 to 10 mm) (1). For this study, necks measuring 3 to 4 mm were included in the small-necked aneurysm group. Consequently, a small neck was defined as measuring 4 mm or less, and a wide neck as measuring more than 4 mm.

Reviewing the diagnostic angiograms of this series of 74 saccular aneurysms, we found that the neck was accurately measured in 66 cases. The neck size could only be approximated in 5 cases. The reasons for this were irregular morphology of the aneurysm, superimposition of normal vessels, or absence of the ideal projection in the diagnostic angiogram. Nonetheless, the measurements obtained were considered accurate enough to be included in the study.

The measurements from three cases (two small and one giant aneurysms) were not used because their diagnostic angiograms exhibited significant irregularities in the vessel caliber at the measurement site. This could have provided erroneous results because our reference values are derived from cases that did not present with cerebral

vascular disease. The angiogram of one case showed marked vasospasm caused by prior subarachnoid hemorrhage. In the second, the distal internal carotid artery was compressed by the sac of a giant paraophthalmic aneurysm. In the third, a case of basilar artery bifurcation aneurysm was associated with an occipital arteriovenous malformation, marked enlargement of one posterior cerebral artery, and the basilar artery.

The neck diameter of the 71 aneurysms included in this analysis ranged from 1.1 to 10.3 mm, with a mean value of 5.26 mm. Twenty aneurysms (28.2%) had a small neck (4 mm or less); in 51 cases (71.8%) the neck was wider than 4 mm. Among the small aneurysms, 17 (59%) had a small neck and 12 (41%) a wide neck. In the large aneurysm population, 2 (7.7%) had a small neck, and 24 (92.3%) had a wide neck. Only one (6.3%) giant aneurysm had a small neck; the remaining 15 (93.7%) had a wide neck.

At the follow-up review, complete aneurysm occlusion was observed in 17 (85%) of the aneurysms that had been measured and included in the small-necked group. A neck remnant was noticed in 3 cases (15%). The mean angiographic follow-up length was 5.63 months in this group, ranging from 0 to 18 months. In 8 cases (40%) the follow-up length was shorter than 1 month.

Among the aneurysms classified as having a wide neck, 8 (15.7%) were completely occluded at the last follow-up angiogram. Subtotal aneurysm occlusion (defined as obliteration of 70% to 98% of the lumen or presence of a neck remnant) was observed in 43 cases (84.3%). The mean angiographic follow-up period in this group was 6.21 months (range, 0 to 23 months). The last follow-up angiogram had been performed less than 1 month after the treatment in 20 cases (39%).

Discussion

The goal of intracranial aneurysm treatment is the exclusion of the aneurysm sac and neck from the circulation. This is currently performed most often by surgical clipping. In surgically difficult aneurysms, an endovascular approach with electrically detachable coils is a practicable alternative (3–5). Considering that this is a recently developed technique and it is not yet possible to compare its results with neurosurgical series, a strict protocol of follow-up angiograms was set up for patients undergoing this method of treat-

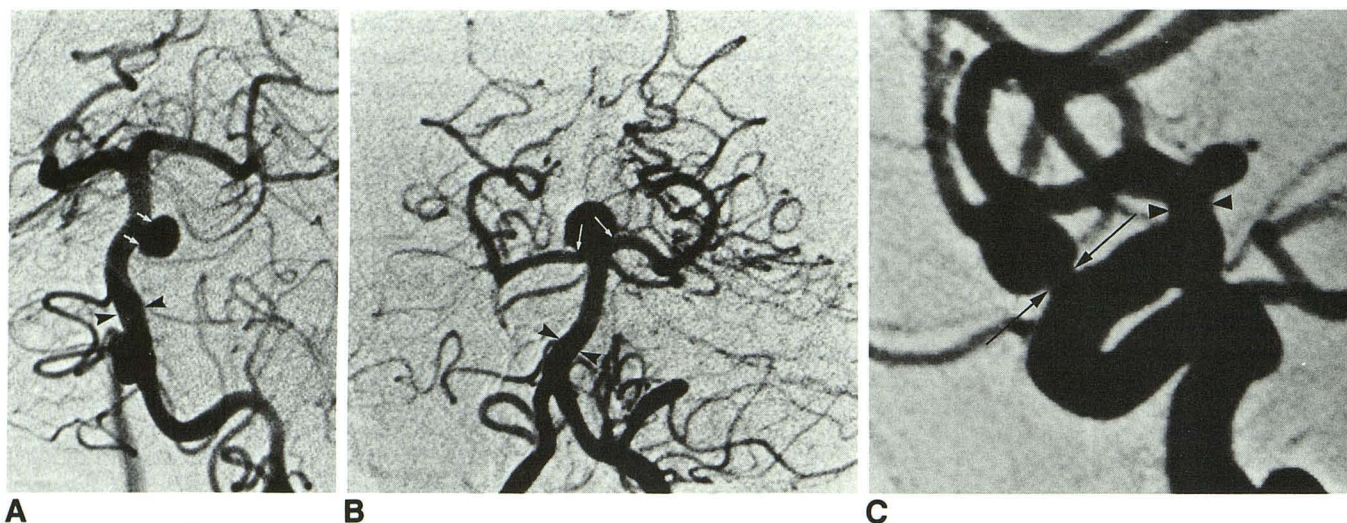


Fig. 1. Vertebral angiogram (anteroposterior projection) showing a midbasilar artery small-necked aneurysm. The basilar artery (arrowheads) is measured. At this site its known average caliber is 3.27 mm. Measuring the angiographic neck (arrows) and applying the formula described in the text, the real neck diameter is obtained. Real neck diameter is 3.3 mm in this case.

Fig. 2. Vertebral angiogram (anteroposterior projection) showing a basilar bifurcation wide-necked aneurysm. The real neck size is obtained after measuring the neck (arrows) and the basilar artery (arrowheads) on the angiogram and applying the formula cited in the text. Reference vessel diameter is 3.27 mm (real neck size is 4.12 mm).

Fig. 3. Internal carotid angiogram (lateral projection) showing a carotid-ophthalmic small-necked aneurysm. The neck (arrows) and the internal carotid artery (arrowheads) are measured. The internal carotid artery average diameter at this site is 3.5 mm. The actual neck size can be obtained (actual neck size is 2.3 mm).

ment. Since our early experience, we felt that the neck size, only subjectively assessed, affected the extent to which the aneurysm could be occluded. This retrospective study was designed to obtain accurate, objective measurements of aneurysm necks and to correlate them with the degree of aneurysm occlusion as seen on follow-up angiograms.

The measurement method described presents certain drawbacks. Sex and side differences exist in the diameter of intracranial arteries (7) and as individual anatomic variations caused by vessel dominance. Arterial caliber can vary as a function of vasospasm, partial pressure of carbon dioxide, and metabolic conditions (6). The analysis of our results did not include the measurements from three cases for such reasons. The reference values reported in the literature for vessel diameters are not absolute figures, but ranges. A mean value was required to operate mathematically. Other measurement methods can be applied during a diagnostic angiogram. For instance, a metallic marker with known length or diameter can be placed on the patient's skin while obtaining the diagnostic angiogram. However, the metallic marker, on the head's surface, will not be subject to the same magnification as the aneurysm. The measurement obtained using this technique is, therefore, approximate and needs correction re-

lated to the magnification. Taking all these factors into consideration, the measurement method outlined in this paper is the best one applicable to angiograms retrospectively. It is likewise the only means of assessing aneurysm neck diameter when reviewing angiograms sent by referring physicians.

In our series, complete occlusion was achieved in 85% of the aneurysms included in the small-necked group. The remaining 15% of the aneurysms in this group showed residual aneurysm neck filling at the follow-up angiogram. The wide-necked group provides significantly different results. Only 15.7% of the cases showed complete occlusion. In a much higher proportion (84.3%), the occlusion was subtotal. The analysis of these results clearly indicates that the degree of aneurysm occlusion is affected by the aneurysm neck size. This finding can be explained by taking into consideration the behavior of the occlusive material inside the lesion. In endovascular therapy a small neck holds the occlusive agent inside the aneurysm. Using the Guglielmi detachable coil technique, the smaller the neck the higher the probability that the mesh of coils bridges across the neck area. This allows aneurysm occlusion without the danger of herniation into the parent vessel and with little risk of coil migration. In wide-necked aneurysms, bridging of the neck

area by the coil mesh is difficult because of the hazard of coil deposit in the parent vessel. Thus, loose coil packing of the neck region may be inevitable. Subsequently, the coils can be pushed by the arterial pressure and become compacted toward the aneurysm sac, resulting in reexposure of portions of the aneurysm to the circulation. The final result is a partial occlusion of the lesion. A neck remnant must be considered potentially dangerous until its natural history is fully understood. There is still lack of long-term follow-up studies of aneurysm neck remnants after Guglielmi detachable coil treatment. Nevertheless, a neck remnant from an aneurysm treated with a Guglielmi detachable coil may not necessarily behave identically to a postclipping neck remnant.

The posttreatment angiographic follow-up period of the cases reviewed for this study varied by a wide range. However, the variation of the follow-up time and its mean value were matched in both groups of aneurysms. Excluding from the revision cases with short follow-up periods would have decreased the size of the sample and weakened the significance of the results. The notable difference in the degree of aneurysm occlusion between the two groups suggests that the 4-mm measurement is a valid threshold, independent of the duration of the angiographic follow-up period.

The main parameter under investigation in this study was the neck diameter. The neck orifice, however, is a surface, with its area proportional to the square of the neck radius. Because of this exponential relationship, a small difference in neck diameter detected by the measurement corresponds to actual significant variations in neck surface area. For instance, the area of a 5-mm-diameter neck is not double but nearly four times larger than the one of a 2.5-mm-diameter neck. This repercussion on the neck area stresses the need to be extremely precise in applying the measurement technique described in this paper. The method's accuracy can be limited by any factor that may alter vessel caliber. Examples of such factors are vasospasm caused by subarachnoid hemorrhage, compression caused by mass effect, or associated arteriovenous malformation. In addition, the cross-section of the neck of an aneurysm resembles more an irregular ellipsoid than a circle (9). Different angiographic projections can therefore show varying diameters. The results of this study indicate that neck size should be carefully taken into consideration when planning an endovascular approach to these lesions.

An erroneous estimation of the neck size can lead to a wrong prediction of the results of treatment. This reinforces the necessity of obtaining views of the aneurysm in multiple projections to guarantee that the largest neck diameter is measured.

We noticed that aneurysms in certain locations were usually better analyzed in a specific projection. This observation had already been described by Lin and Kricheff (10). The anteroposterior projection is the most suitable to measure the neck of basilar artery bifurcation aneurysms. It is difficult to identify the actual neck extent in the lateral view, because of superimposition of the posterior cerebral arteries. However, if the dome of the aneurysm points ventrally or dorsally, a pure anteroposterior view can be misleading, because the neck will still be hidden by the sac. In these cases, a Waters or a Townes projection, respectively, will be more adequate. A submentovertex view may be needed in certain ventral-growing basilar artery bifurcation aneurysms. Furthermore, when the axis of the aneurysm is not in the sagittal plane, an oblique projection (Townes oblique, Waters oblique, etc) also may be required. Aneurysms of the internal carotid artery–ophthalmic artery junction originate dorsally or medially and are distinguished by a dorsal medial projection. Therefore the neck of these aneurysms is best assessed in lateral and lateral-oblique projections. Most posterior communicating artery aneurysms are best seen in lateral and lateral oblique views, because their sacs commonly project posteriorly or posterolaterally.

The technique of endovascular occlusion with Guglielmi detachable coils was originally designed to offer a less traumatic therapy for intracranial aneurysms. The results of this study clearly confirm that complete occlusion of small-necked aneurysms can be achieved with this technique. Longer-term follow-up angiograms, however, are required to assess consistency of the results reported in this review. The results obtained in the wide-necked group are less satisfactory. As noted above, only subtotal occlusion was achieved in most of these cases. Thus, in wide-necked aneurysms, the Guglielmi detachable coil technique should be reserved for lesions having a high surgical risk.

References

1. Yasargil MG. Pathological considerations. In Yasargil MG, ed. *Micro-neurosurgery*. Stuttgart: Thieme Verlag, 1984:280–281
2. Drake CG. Giant intracranial aneurysms: experience with surgical treatment in 174 patients. *Clin Neurosurg* 1978;26:19–95

3. Guglielmi G, Viñuela F, Sepetka I, Macellari V. Electrothrombosis of saccular aneurysms via endovascular approach. Part 1: electrochemical basis, technique, and experimental results. *J Neurosurg* 1991;75:1-7
4. Guglielmi G, Viñuela F, Dion J, Duckwiler G. Electrothrombosis of saccular aneurysms via endovascular approach. Part 2: preliminary clinical experience. *J Neurosurg* 1991;75:8-14
5. Guglielmi G, Viñuela F, Duckwiler G, et al. Endovascular treatment of posterior circulation aneurysms by electrothrombosis using electrically detachable coils. *J Neurosurg* 1992;77:515-524
6. Radü EW, Du Boulay MB. Paradoxical dilatation of the large cerebral arteries in hypocapnia in man. *Stroke* 1976;7:569-572
7. Müller HR, Brunhölzl Chr, Radü EW, Buser M. Sex and side differences of cerebral arterial caliber. *Neuroradiology* 1991;33:212-216
8. Wollschlaeger G, Wollschlaeger PB, Lucas FV, Lopez VF. Experience and result with postmortem cerebral angiography performed as routine procedure of the autopsy. *AJR Am J Roentgenol* 1967;101:68-87
9. Black SPW, Leo H-L, Carson WL. Recording and measuring the interior features of intracranial aneurysms removed at autopsy: method and initial findings. *Neurosurgery* 1988;22:40-43
10. Lin JP, Kricheff II. Angiographic investigation of cerebral aneurysms. *Neuroradiology* 1972;105:69-76