



Get Clarity On Generics

Cost-Effective CT & MRI Contrast Agents

 FRESENIUS
KABI

[WATCH VIDEO](#)

AJNR

Transient monocular blindness in carotid occlusion testing.

R W Hurst and H I Goldberg

AJNR Am J Neuroradiol 1994, 15 (2) 255-257

<http://www.ajnr.org/content/15/2/255>

This information is current as
of August 11, 2025.

Transient Monocular Blindness in Carotid Occlusion Testing

Robert W. Hurst and Herbert I. Goldberg

Summary: A patient developed monocular blindness 23 minutes into a temporary balloon occlusion test of the carotid artery, on the side being tested. His vision returned to normal 1 minute after the balloon was deflated. The authors emphasize the importance of complete frequent neurologic examination during this kind of test.

Index terms: Interventional neuroradiology, provocative testing; Interventional neuroradiology, complications of; Arteries, carotid (internal); Iatrogenic disease or disorder

The primary complication associated with therapeutic occlusion of the internal carotid artery is cerebral infarction involving the territory supplied by the occluded vessel. Carotid occlusion tests using nondetachable balloons are performed before permanent carotid occlusion to evaluate the ability of collateral pathways to provide adequate blood flow to the brain, thereby minimizing the chance of development of cerebral infarction. We report a case of isolated monocular blindness which occurred during a carotid occlusion test in a patient with a cavernous origin of the ophthalmic artery. Because of the possibility of monocular blindness, we stress the importance of complete careful repeated neurologic examination during occlusion testing.

Case Report

A 45-year-old man was evaluated for balloon occlusion of the right internal carotid artery before surgical resection of malignant adenopathy secondary to squamous cell carcinoma of the oropharynx. The patient had undergone maximal radiation therapy to the face and neck for metastatic disease. No neurologic deficits were present.

The left internal carotid artery injection showed good cross-filling of the right anterior and middle cerebral artery via the anterior communicating artery. Injection of the left vertebral artery showed good forward filling via the posterior communicating arteries. Injection of the right common carotid artery demonstrated a cavernous origin of the right ophthalmic artery (Fig 1). Normal filling of the intracranial

branches of the right internal carotid artery occurred. No evidence of atherosclerotic disease was present.

Temporary occlusion of the right internal carotid artery was performed using a permanently attached balloon occlusion catheter (occlusion balloon 5-2-100, Meditech, Watertown, Mass) after systemic heparinization with 10 000 U of heparin. Activated coagulation time after heparin administration was in excess of 400 seconds. The balloon was inflated in the proximal internal carotid artery under fluoroscopic control. Throughout the period of carotid occlusion, 1-cc injections of heparinized saline were made every several minutes through the distal port of the occlusion catheter to prevent clot formation within the lumen. Neurologic examination including testing of strength, sensation, cranial nerves, visual fields, and visual acuity was performed every 1 to 2 minutes after inflation of the balloon catheter. At approximately 23 minutes after occlusion, the patient became unable to see a stimulus presented to the right eye on testing. Further testing revealed no light perception on the right. There was no pupillary response to light stimulus on the right. The right pupil constricted on light stimulus to the left eye. There were no visual field or acuity abnormalities on the left and no other neurologic deficits.

Balloon deflation was accomplished immediately under fluoroscopic control. Contrast injection revealed normal filling of the anomalously originating right ophthalmic artery. After approximately 1 minute the patient noted a return of vision on the right. Visual acuity at that time was 20/20. The occlusion test was terminated. The patient refused further surgical therapy.

Discussion

This case demonstrates the potential for monocular blindness to develop in the setting of therapeutic occlusion of the internal carotid artery, a sign not previously emphasized in association with carotid occlusion testing. The patient's anomalous anatomy and history of radiation therapy provided the setting for ischemic blindness and may suggest cases in which the risk of ocular ischemia should be anticipated. The case also

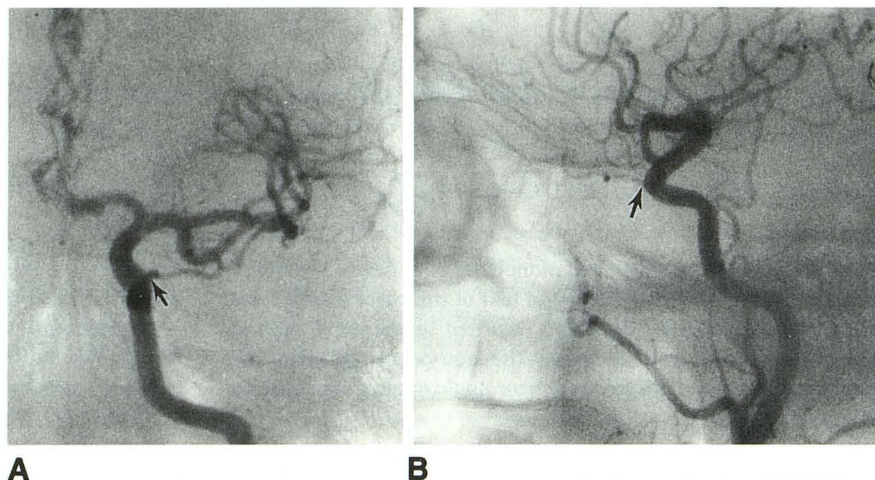
Received May 21, 1992; accepted pending revision September 30; revision received June 4, 1993.

From the Department of Radiology, Hospital of the University of Pennsylvania, Philadelphia.

Address reprint requests to Robert W. Hurst, MD, Department of Radiology, Hospital of the University of Pennsylvania, Philadelphia, PA 19104.

AJNR 15:255-257, Feb 1994 0195-6108/94/1502-0255 © American Society of Neuroradiology

Fig. 1. Anteroposterior (A) and lateral (B) views of the right common carotid injection demonstrate a cavernous origin of the ophthalmic artery (arrow).



emphasizes the necessity of complete neurologic evaluation during carotid occlusion testing.

The rarity of monocular blindness during carotid occlusion testing may be related to the great potential for collateral flow to the ophthalmic circulation. The usual location of the ophthalmic artery as the first intradural branch of the internal carotid artery is significant in that collateral filling after internal carotid artery occlusion is usually easily accomplished by retrograde filling of the supraclinoid internal carotid artery. As the mean distance from the normal ophthalmic artery origin to the nearest intracranial collaterals, the posterior communicating artery and the bifurcation of the internal carotid artery, is only 9.6 mm and 19.2 mm, respectively (1), the establishment of retrograde flow to this vessel is usually immediate. In 8% of patients, however, the ophthalmic artery originates extradurally from the cavernous portion of the internal carotid artery (2). The identification of this usually asymptomatic variant is important in interventional neuroradiologic procedures, particularly those involving the cavernous carotid artery. In this patient the more proximal cavernous origin of the ophthalmic artery increased its distance from potential intracranial collateral supply from both the contralateral internal carotid and the basilar circulations. The additional distance was apparently too great in this patient for adequate ophthalmic perfusion. In contrast, collateral flow to the right cerebral hemisphere was adequate, thus accounting for the absence of hemispheric deficits.

A second mechanism that usually protects the ophthalmic circulation from ischemia arises from the multitude of external carotid branches potentially providing immediate collateral flow to the ophthalmic artery. The patient's history of max-

imal radiation therapy to both the face and neck may have prevented the opening of these collateral vessels, thus permitting ischemia of the ophthalmic circulation.

The anomalous anatomy of this patient's ophthalmic artery combined with the decreased potential for external carotid collateralization resulted in perfusion failure to the ophthalmic circulation. The full heparinization and immediate normal filling of the vessel after balloon deflation would make embolus unlikely. Additionally, the immediate return of normal vision points most strongly to a failure of perfusion as the cause of his transient monocular blindness.

Had the procedure been performed with continuous distal perfusion thorough the occlusion balloon catheter, perfusion of the ophthalmic artery with saline might be considered the cause of the deficit. This technique was not used, however. One-cubic-centimeter boluses of heparinized saline were injected through the distal lumen of the balloon catheter every several minutes to prevent retrograde filling of the distal lumen with blood, which might permit clot formation within the catheter. The amounts of saline used were not sufficient to permit ophthalmic artery perfusion.

Although recent studies have suggested that cerebral perfusion studies may add significant information to carotid occlusion testing, such studies would not have detected this potential complication and must not be viewed as a substitute for careful neurologic examination (3-6). In addition, the appearance of the deficit more than 20 minutes into the occlusion test further emphasizes the need for an adequate period of clinically observed carotid occlusion. We routinely use 30 minutes of carotid occlusion testing. A shorter occlusion period may be adequate in

patients with normal anatomy and no predisposing conditions such as radiation therapy, which might compromise potential collaterals. In this case, a shorter trial of occlusion might have failed to allow diagnosis of the deficit. Because no cerebral perfusion imaging was used, no comment can be made regarding the presence or significance of clinically silent cerebral hypoperfusion.

This case emphasizes the importance of complete evaluation of candidates for carotid occlusion testing including history and preocclusion angiographic examination. Most importantly, it stresses the importance of complete frequent neurologic examination during carotid occlusion testing.

References

1. Gibo H, Lenkey C, Rhoton A. Microsurgical anatomy of the supraclinoid portion of the internal carotid artery. *J Neurosurg* 1981;55:560-574
2. Harris F, Rhoton A. Anatomy of the cavernous sinus: A microsurgical study. *J Neurosurg* 1976;45:169-180
3. Eskridge J. The challenge of carotid occlusion. *AJNR Am J Neuroradiol* 1991;12:1053-1054
4. Monsein L, Jeffrey PJ, Van Heerden BB, et al. Assessing adequacy of collateral circulation during balloon test occlusion of the internal carotid artery with 99mTc-HMPAO SPECT. *AJNR Am J Neuroradiol* 1991;12:1045-1051
5. Moody E, Dawson R, Sandler M. 99mTc-HMPAO SPECT imaging in interventional neuroradiology: validation of balloon test occlusion. *AJNR Am J Neuroradiol* 1991;12:1043-1044
6. Peterman S, Taylor AJ, Hoffman JJ. Improved detection of cerebral hypoperfusion with internal carotid balloon test occlusion and 99mTc-HMPAO cerebral perfusion SPECT imaging. *AJNR Am J Neuroradiol* 1991;12:1035-1041