



Get Clarity On Generics

Cost-Effective CT & MRI Contrast Agents



FRESENIUS
KABI

WATCH VIDEO

AJNR

MR of acute autonomic and sensory neuropathy.

T Yasuda, G Sobue, Y Hirose, M Mimura and T Yanagi

AJNR Am J Neuroradiol 1994, 15 (1) 114-115

<http://www.ajnr.org/content/15/1/114.citation>

This information is current as
of August 29, 2025.

MR of Acute Autonomic and Sensory Neuropathy

Takeshi Yasuda, Gen Sobue, Yoshikiyo Hirose, Mikio Mimura, and Tsutomu Yanagi

Summary: The case of acute autonomic and sensory neuropathy presented here demonstrated high MR signal intensity in the posterior columns of the spinal cord.

Index terms: Neuropathy; Spinal cord, magnetic resonance; Nervous system, diseases

Acute autonomic and sensory neuropathy was first described by Colan and colleagues in 1980 (1). The disease is characterized by autonomic dysfunction and severe sensory deficit with acute onset (2, 3). The disease is rare and is thought to be a variant form of acute pandysautonomia (4, 5) and Guillain-Barré syndrome (6). Pathologically, the abnormality in this disease as found in two autopsied cases was located in the dorsal root ganglia with the secondary degeneration in the posterior column of the spinal cord (7, 8). In the present study we show the magnetic resonance (MR) findings in the spinal cord of a patient with acute autonomic and sensory neuropathy.

Case Report

A 44-year-old woman had an upper respiratory tract infection 2 weeks before the onset of general fatigue and gait disturbance. She was admitted to a local hospital with difficulty in walking and numbness of the hands. Because of severe vomiting, abdominal distension, and numbness throughout her entire body, including the face, the patient was transferred to our hospital. Physical examination on admission revealed complete anhidrosis, paretic ileus, and diminished bowel sounds. Urinary retention was noted, and catheterization was performed. Neurologically, light reflex was bilaterally sluggish, corneal reflexes were absent, and there was a mild facial diplegia. She had mild muscular weakness of the upper limbs on both sides which was worse on the left, and she could not keep her knees flexed while in bed. Sensation was completely lost for all modalities over the entire body. Deep tendon reflexes were generally absent. In the ensuing weeks, she developed postural hypotension with syncope. Cerebrospinal fluid protein was

158 mg/dL, and the cell count was normal. Neurophysiologic studies showed that sensory nerve action potentials were not evoked in the four extremities, but motor conduction velocities and compound muscle action potentials were normal. Sensory evoked potentials were not elicited by median nerve stimulation. Sural nerve biopsy demonstrated severe axonal degeneration of myelinated and unmyelinated fibers. Within 6 months after the onset of symptoms, the motor weakness recovered, and the urinary disturbance and orthostatic hypotension markedly improved without any drugs. However, sensory loss in pain, touch, vibration, and position persisted in the trunk and four extremities. The patient could not walk without assistance because of severe sensory ataxia. MR performed on a 1.5-T unit 6 months after the onset demonstrated a high-intensity area in the posterior column of the cervical, thoracic, and lumbar spinal cord, including both the fasciculi cuneatus and gracilis on T2*-weighted gradient-echo images (Fig 1). These lesions were not enhanced by gadolinium.

Discussion

Our patient experienced acute onset of urinary retention, paretic ileus, postural hypotension, and severe sensory loss. Her symptoms and signs were compatible with those of acute autonomic and sensory neuropathy (1). Other autonomic and sensory neuropathies such as diabetic neuropathy; alcoholic neuropathy; neuropathies caused by botulism, amyloidosis, and malignant disease; and hereditary sensory and autonomic neuropathy including Reiley-Day syndrome could be ruled out by this patient's clinical features and history. In our case, orthostatic hypotension, paretic ileus, anhidrosis, and urinary disturbance began to resolve within 6 months after the onset of symptoms. However, sensory loss in all modalities over the entire body did not recover. The absence of sensory evoked potentials, severe axonal involvement on sural nerve biopsy, and persistent sen-

Received August 10, 1992; accepted pending revision October 16; revision received December 15.

From the Departments of Neurology (T.Yas., Y.H., T.Yan.) and Radiology (M.M.), Nagoya Daini Red Cross Hospital; and the Fourth Department of Internal Medicine (G.S.), Aichi Medical University, Aichi-ken, Japan.

Address reprint requests to Gen Sobue, Division of Neurology, Fourth Department of Internal Medicine, Aichi Medical University, Nagakute, Aichi 480-11, Japan.

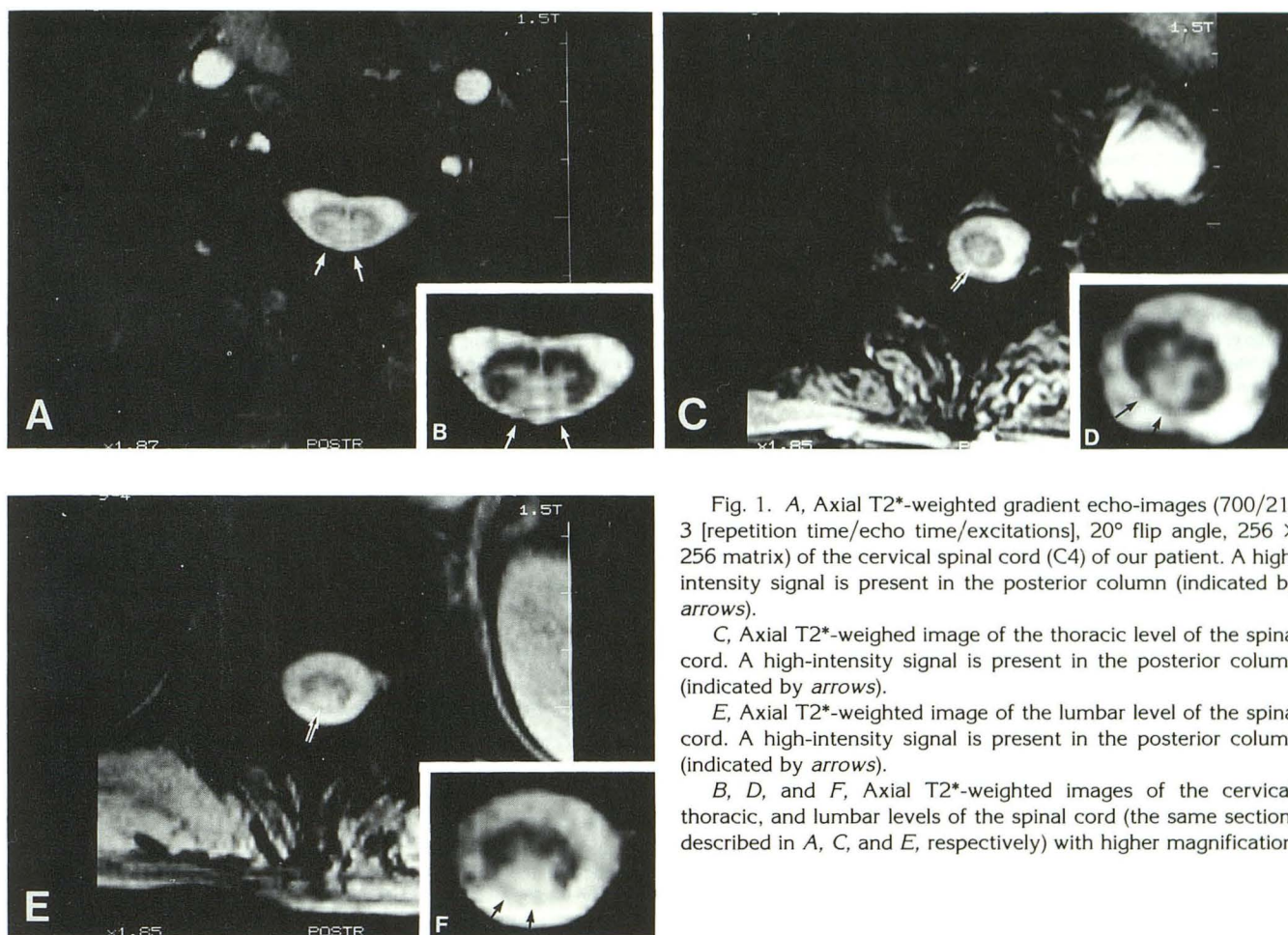


Fig. 1. A, Axial T2*-weighted gradient echo-images (700/21/3 [repetition time/echo time/excitations], 20° flip angle, 256 × 256 matrix) of the cervical spinal cord (C4) of our patient. A high-intensity signal is present in the posterior column (indicated by arrows).

C, Axial T2*-weighted image of the thoracic level of the spinal cord. A high-intensity signal is present in the posterior column (indicated by arrows).

E, Axial T2*-weighted image of the lumbar level of the spinal cord. A high-intensity signal is present in the posterior column (indicated by arrows).

B, D, and F, Axial T2*-weighted images of the cervical, thoracic, and lumbar levels of the spinal cord (the same sections described in A, C, and E, respectively) with higher magnification.

sory loss suggested that the dorsal root ganglion neurons were involved in our case (ganglionopathy), as previously demonstrated in two autopsied cases (7, 8). The MR findings of a high-intensity area on T2*-weighted images in the posterior column of the spinal cord supported the view that the sensory ganglion neurons were primarily and extensively involved in the spinal cord lesion, which was consistent with autopsy findings in other cases in which severe posterior column involvement had been found. The T2*-weighted high-intensity areas in both the fasciculus cuneatus and fasciculus gracilis in the posterior column was also consistent with the distribution of sensory loss extending to the arms, legs, and trunk. Friedreich ataxia, subacute combined degeneration, tabes dorsalis, and subacute myelopticonuropathy are other diseases that may present with lesions in the posterior column of the spinal cord. The present case suggested that MR studies of the spinal cord can provide important information regarding central axon involvement of the

sensory ganglion neurons in sensory neuropathies such as the ganglionopathy observed in acute autonomic and sensory neuropathy.

References

1. Colan RV, Snead OC, Oh SJ, et al. Acute autonomic and sensory neuropathy. *Ann Neurol* 1980;8:441-444
2. Fujii N, Tabira T, Shibasaki H, et al. Acute autonomic and sensory neuropathy associated with elevated Epstein-Barr virus antibody titre. *J Neurol Neurosurg Psychiatry* 1982;45:656-661
3. Kanda F, Uchida T, Jinnai K, et al. Acute autonomic and sensory neuropathy: a case report. *J Neurol* 1990;237:42-44
4. Young RR, Asbury AK, Corbett JL. Pure pandysautonomia with recovery. *Trans Am Neurol* 1969;94:355-357
5. Appenzeller O, Kornfeld M. Acute pandysautonomia. *Arch Neurol* 1973;29:334-339
6. Hodson AK, Hurwitz BJ, Albrecht R. Dysautonomia in Guillain-Barré syndrome with dorsal root ganglioneuropathy, Wallerian degeneration, and fatal myocarditis. *Ann Neurol* 1984;15:88-95
7. Fagius J, Westerberg CE, Olsson Y. Acute pandysautonomia and severe sensory deficit with poor recovery. A clinical, neurophysiological and pathological case study. *J Neurol Neurosurg Psychiatry* 1983;46:725-733
8. Tohgi H, Sano M, Sasaki K. Acute autonomic and sensory neuropathy: report of an autopsy case. *Acta Neuropathol* 1989;77:659-663