



Get Clarity On Generics

Cost-Effective CT & MRI Contrast Agents



FRESENIUS
KABI

WATCH VIDEO

AJNR

3-D reconstruction for evaluation of facial trauma.

S J Zinreich

AJNR Am J Neuroradiol 1992, 13 (3) 893-895

<http://www.ajnr.org/content/13/3/893.citation>

This information is current as
of August 22, 2025.

3-D Reconstruction for Evaluation of Facial Trauma

S. James Zinreich¹

The facial skeleton comprises bones of varying shapes, thickness, and size, arranged into an interconnecting support system of buttressed arches. Three sagittal buttresses are identified: two involving the lateral nasal walls and superiorly, the medial orbital walls and, between these two, the nasal septum. There are two coronal buttresses, one anteriorly, including the frontal bone, orbital rims, anterior maxilla, and alveolus and one posteriorly, including the posterior maxillary wall and pterygoid processes. Three horizontal struts include the floor of the anterior cerebral fossa, the orbital floor and zygomatic arches, and the hard palate. A clear understanding of the orientation of these struts provides an explanation of the mechanism and extent of injury in this area (1, 2). In 1901, LeFort was the first to introduce the face as a functional unit. Through his description of the "line of least resistance" a classification of facial fractures was established, also widely used as osteotomy planes for the treatment of congenital and post-traumatic facial deformities (3).

Traditionally, patients with facial trauma are evaluated based on the combination of the physical examination and plain films. Both are frequently suboptimal in the ill patient who is also often uncooperative. Initially, overlying edema, hemorrhage, and soft-tissue injury may obscure the facial deformity. For this reason, therapy is often delayed but is usually performed within the first 7 days to avoid fibrous fixation. Of particular importance are the presence of malocclusion, abnormal mobility, diplopia, orbital rim "step-off," hypertelorism and cerebrospinal fluid rhinorrhea, all good indicators of the site and type of injury (4).

The ability to simultaneously display the facial skeleton, the soft tissues, brain, and air spaces make computed x-ray tomography the optimal modality to evaluate facial trauma. Scanning in the axial and coronal planes provide the best

diagnostic information, especially when both planes are available for evaluation. Often, due to the patient's condition, coronal images cannot be obtained. In such cases, thinner axial images or overlapping scans allow multiplanar reconstruction (MPR) in virtually any plane (5–7). Even though such images improve the radiologist's 3-D perception, some clinicians find this information difficult to conceptualize and prefer a more recently available display—three dimensional imaging (3-D) (6).

Over the past 6 years, we have witnessed significant advances in 3-D imaging. At the time of its first introduction the displays were based largely on thresholding segmentation methods with a surface display. Due to the limitations of segmentation, this new modality is best applied to tissues with distinctive attenuation coefficients, making it particularly useful in the examination of bony structures. The denser and larger the bony structure, the more optimal is its 3-D reconstruction. In the reconstruction of the maxillofacial/calvarial skeleton the larger bones are well displayed, but the smaller and thinner bones—orbit, cribriform plate, ethmoid, maxilla—are less accurately reconstructed. Adjusting the segmentation for the accurate display of larger bones results in "tissue dropout" of the smaller bones. Moreover, when trying to adjust the thresholding to select the thinner, smaller bones, a significant "bleeding" of bone segmentation into adjacent normal soft tissues or pathology may be seen. Thus the smaller bony structures are, by the nature of their density and size, more difficult to evaluate from a 3-D reconstruction.

More recent advances in segmentation methods, as reviewed by Levy RA et al in this issue of the *AJNR* (8), describe an improved method for reconstruction of smaller bony structures. They discuss the need for an automated 3-D segmentation algorithm, but acknowledge the continued dependence on the user's knowledge to define

¹ Department of Radiology and Radiological Sciences, Johns Hopkins Medical Institutions, 600 N. Wolfe Street, Baltimore, MD 21205.

the outlines of structures of fine detail. Decreasing the scanning thickness to 1 mm or even submillimeter ranges (9), as well as decreasing the field of view during the initial scanning, provide a more accurate 3-D reconstruction. This was proven by Levy et al.

Currently, the role of 3-D in facial trauma is largely perceptual. The pathologic diagnosis is usually made on the two-dimensional images, while reconstruction of the information into a 3-D image improves the display of the fracture site, extent of fracture, the presence and extent of step-off, and the extent of fracture-fragment rotation. 3-D imaging also provides a display of the entire regional injury, enabling accurate presurgical planning for reduction and fixation.

3-D images permit a direct view of anatomic relationships, enhanced by the ability to observe images from any angle—with operator control of image rotation and magnification. Linear measurements on the reconstructed images are accurate, reproducible, and unaltered by change in magnification or viewing angle. Cut-away wedged views visualize deeper structures, and simultaneously display the original or reconstructed (MPR) two-dimensional images on the surface of the wedge. This allows a direct correlation of the information of the axial and coronal images with the findings of the 3-D images (Figs. 1A and 1B).

Most importantly, the 3-D display provides a global view of the face, thus providing increased perception of all injured sites. The location of the bony fragments and their interrelationships can be assessed, even if several sites are involved. Such a display enables optimal presurgical planning. Where to affix the miniplates and how many to use is easily determined. The display of the information from virtually any angle enhances the perception of malocclusion and comminution, their extent, and, therefore, the appropriate therapeutic approach. Regarding blow-out fractures, the 3-D volumetric display can provide area measurements and orbital volume changes that may influence the therapy for enophthalmos.

As with the advent of any new medical technology, one must assess whether its use will actually provide additional data or improve patient care, justifying its utilization and expense. Specifically, in the case of 3-D, do these reconstructed views provide information previously unattainable with conventional 2-D images?

3-D has been shown to improve diagnosis in the evaluation of spinal trauma (10, 11). The authors of these reports explain the diagnostic

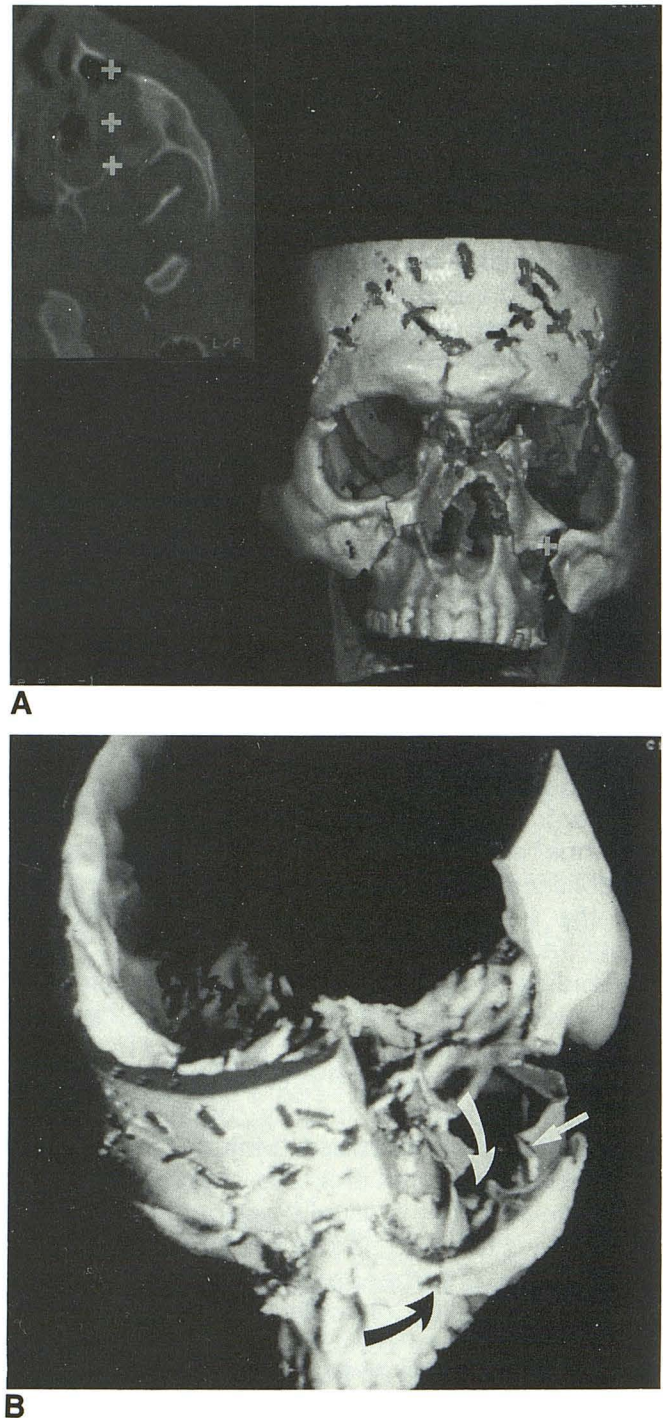


Fig. 1. Comparison of 3-D and 2-D axial images.

A, The 3-D reconstruction of a patient who sustained severe maxillofacial, orbital, and calvarial trauma. The cross-shaped cursor on the 3-D image reveals the plane and location of the fracture depicted by the cursor(s) on the axial image.

B, Triplanar wedge into the left maxillofacial skeleton demonstrates the fracture plane in the maxillary sinus (between curved arrows) and a fracture of the coronoid process (straight arrow). Note that the wedge surfaces display the 2-D axial and MPR image data, providing another means to compare the 2-D and 3-D information.

utility of 3-D in spinal injury and show that orthogonal images alone are insufficient for the display of the complex morphology of the spinal posterior elements. This reasoning might also be applied to the evaluation of facial trauma. However, before such an evaluation may be undertaken there is a need to establish the accuracy with which current "state of the art" 3-D imaging can display facial fractures. Levy et al. (8) have undertaken this worthy project by first creating a controlled model to evaluate facial trauma and then evaluating the accuracy of their 3-D reconstructions. The lamina papyracea and orbital floor are the two maxillofacial areas most difficult to reconstruct three-dimensionally. Levy et al. showed that scanning in the coronal plane and the use of 1-mm thick slices faithfully replicated even the orbital floor fractures with the use of regional thresholding and seed growing segmentation.

Scanning in the coronal plane is important not only for reconstruction purposes but also because it best displays the sagittal and horizontal struts, sites of the most common and severe complications in facial trauma (4). The radiologic evaluation of facial injuries should not only include a listing of the fractures and classification of their planes, but should also determine which struts are injured and their relationship to adjacent soft tissues. Perception of this information is greatly facilitated by 3-D imaging (Figs. 1A and 1B).

The display and interpretation of radiographic information continues to change. To date, however, the information analysis continues to be remote from the patient and the transfer of this information from film or computer screen to the patient is intuitive. The next step for display and interpretation of imaging data should aim to achieve the active transfer of such information to the patient. A system with a computer capable of 3-D and 2-D reconstruction of CT or MR data (ISG Allegro Computer, ISG Technologies, Inc, Toronto, Canada), connected to a robotic-like

mechanical sensor (FARO, Faro Medical Instruments, Tampa, FL) and a computer display screen, can now be used to transfer information directly from the radiographic display to the patient at the time of surgery. This system can provide accurate localization of anatomy and pathology and, perhaps in the future, will actively guide the surgical repair of trauma.

The role of 3-D imaging for facial injury is not primarily diagnostic. Two-dimensional images usually provide the basic diagnosis, but 3-D reconstructions enhance perception of pathology and enable precise planning for therapy. The future objective for 3-D imaging should aim to expand the direct application of imaging data to patient management, such as the intraoperative use of 3-D data to actively guide surgical repair of facial injuries and craniofacial anomalies.

References

1. Mancuso AA, Hanafee WN. *Computed tomography and magnetic resonance imaging of the head and neck*. 2nd ed. Baltimore: Williams & Wilkins, 1985:42-60
2. Gentry LR, Manor WF, Turski RA, Strother CM. High resolution CT analysis of facial struts in trauma. I. Normal anatomy. *AJR* 1983; 140:523
3. LeFort R. Etude experimentale sur les fractures de la machoire superieure. *Rev Chir* 1901;23:208, 360
4. Schweitzer H, Kruger E. Midface fracture. In: Kruger E, Schilli W, Worthington P, eds. *Oral and maxillofacial traumatology*. Vol. 2. Chicago: Quintessence, 1986:107-136
5. Brant-Zawadzki MN, Minagi H, Federle MD, Rowe LD. High resolution CT with image reformation in maxillofacial pathology. *AJNR* 1982; 3:31-37
6. Som PM. Sinonasal cavity: fractures. In: Som PM, Bergeron RT, eds. *Head and neck imaging*. 2nd ed. St. Louis: Mosby Yearbook, 1991: 227-229
7. Guyon JJ, Brant-Zawadzki M, Seiff SR. CT demonstration of optic canal fractures. *AJR* 1984;143:1031-1034
8. Levy RA, Edwards WT, Meyer JR, Rosenbaum AE. Facial trauma and 3-D reconstructive imaging: insufficiencies and correctives. *AJNR* 1992;13:885-892
9. Wojcik WG, Edeiken-Monroe BS, Harris JN. Three dimensional computed tomography in acute cervical spine trauma: a preliminary report. *Skeletal Radiol* 1987;16:261-264
10. Zinreich SJ, Rosenbaum AE, Wang H, et al. The critical role of 3D CT reconstructions for defining spinal disease. *Acta Radiol (Suppl)* 1986;369:699-702